DOI: https://doi.org/10.53350/pjmhs020241811141

ORIGINAL ARTICLE

Diagnostic Accuracy of Physical Examination versus Axillary Ultrasound for Nodal Staging of Breast Cancer in Patients Undergoing Modified Radical Mastectomy

UMER ANWAR[1], MAHVISH NOOR[2], HIRA MUNIR[3], MEHAR JAMIL[1], AREEJ AMANAT[1]
[1]*Postgraduate Resident of General Surgery, Department of Surgery, Fauji Foundation Hospital, Rawalpindi*
[2]*Assistant Professor of Surgery, Department of Surgery, Fauji Foundation Hospital, Rawalpindi*
[3]*Senior Registrar General Surgery, Department of Surgery, Fauji Foundation Hospital, Rawalpindi*
Correspondence to: Dr Umer Anwar, Email: umer_anwer@ymail.com

ABSTRACT

Background: Axillary nodal status is the strongest predictor of outcome in breast cancer, yet preoperative staging in many centres still relies on palpation.

Aim: To compare the diagnostic accuracy of physical examination and axillary ultrasound for preoperative nodal staging of breast cancer, using postoperative histopathology as the reference standard.

Material and Methods: This cross-sectional validation study was conducted in the Department of Surgery, Fauji Foundation Hospital, Rawalpindi, from 1 April to 1 October 2023. We enrolled 195 consecutive, chemotherapy-naïve women aged 18 to 80 years with primary breast cancer who were scheduled for modified radical mastectomy. Each patient underwent standardised axillary examination by a surgical registrar, then ipsilateral axillary ultrasound by a radiology registrar. Histopathology of the dissected axillary nodes served as the reference. Sensitivity, specificity, positive and negative predictive values (PPV, NPV) and accuracy were calculated with 95% confidence intervals.

Results: Mean age was 49.2 ± 10.2 years. Histopathology confirmed nodal metastasis in 58 patients (29.7%). Physical examination showed sensitivity of 56.9%, specificity 94.9%, PPV 82.5%, NPV 83.9% and accuracy 83.6%. Axillary ultrasound showed sensitivity of 79.3%, specificity 95.6%, PPV 88.5%, NPV 91.6% and accuracy 90.8%. Examination missed 25 node-positive patients; ultrasound missed 12. Ultrasound sensitivity equalled or exceeded that of examination in every stratum of age and risk factors.

Conclusion: Axillary ultrasound detected nodal metastasis far more often than palpation, with no loss of specificity. It should be a routine part of preoperative axillary staging rather than an optional add-on.

Keywords: Breast Neoplasms; Axilla; Lymphatic Metastasis; Ultrasonography; Physical Examination

INTRODUCTION

Breast cancer is now the most commonly diagnosed cancer in women worldwide, with an estimated 2.3 million new cases in 2020[1]. Pakistan carries a heavy and rising share of this burden. Registry data from Karachi project a steady increase in age-specific incidence through 2025[2], although national figures remain uncertain because the country has no national cancer registry and regional series differ widely with the ethnic mix of the population they serve[3]. In many of our hospitals, a large proportion of women are still treated with modified radical mastectomy (MRM) and full axillary dissection.

The status of the axillary lymph nodes remains one of the most powerful prognostic factors in early breast cancer. It shapes decisions on systemic therapy, regional radiotherapy and the extent of axillary surgery[4,5]. Staging the axilla accurately before operation therefore has practical consequences. A missed metastasis may leave disease untreated, while a falsely positive axilla can commit a woman to a dissection, and to its lymphoedema risk, that she did not need.

For decades, clinical palpation was the main and often the only tool for preoperative nodal staging[6,7]. It is quick and costs nothing, but it is subjective. Its yield depends on the examiner's experience, the patient's build and the depth of the nodes. Small deposits, and nodes lying beneath the pectoral muscles, are easily missed, whereas reactive nodes may feel suspicious[5,6]. Chen and colleagues reported a sensitivity of only 54.2% for physical examination against histopathology[7], and Olfatbakhsh et al. found a sensitivity of 31% despite a specificity of 98%[8].

Ultrasound has become the imaging method of choice for the axilla. It can show cortical thickening, loss of the fatty hilum, a rounded shape and abnormal vascularity, and it guides needle sampling of any suspicious node[5,6]. Current European and North American guidance includes axillary ultrasound in the routine work-up of early breast cancer[9,10]. Its role grew further when the SOUND trial showed that, in women with tumours of 2 cm or less and a sonographically normal axilla, omitting axillary surgery was non-inferior to sentinel node biopsy[11]. In that setting, the reliability of a single ultrasound report directly decides whether the axilla is operated on at all.

Published Pakistani work has mostly examined ultrasound in clinically node-negative women, measuring how often a normal scan is confirmed at surgery[12,13]. Fewer studies have compared palpation and ultrasound side by side in the same patients against full axillary dissection, and several earlier comparisons were retrospective. We therefore set out to compare the diagnostic accuracy of physical examination and axillary ultrasound for preoperative nodal staging in women undergoing MRM, using histopathology of the dissected nodes as the reference standard.

MATERIAL AND METHODS

Study design and setting: This cross-sectional validation study was carried out in the Department of Surgery, Fauji Foundation Hospital, Rawalpindi, from 1 April 2023 to 1 October 2023. The synopsis was approved by the College of Physicians and Surgeons Pakistan, and the hospital ethics review committee granted approval (reference no. [to be added]). Every participant read and signed a written informed consent form, and confidentiality was maintained throughout.

Sample size and sampling: The minimum sample size was estimated with Buderer's formula for sensitivity and specificity, assuming an expected sensitivity of 86.8% and specificity of 72.5%[7], an anticipated prevalence of nodal involvement of 49%, an absolute precision of 10% and a 95% confidence level. Specificity was the limiting estimate and required at least 151 patients; 195 patients were enrolled, which exceeds this minimum. Patients were recruited by non-probability consecutive sampling.

Participants: We included women aged 18 to 80 years with primary breast cancer diagnosed on clinical examination, mammography and/or histopathology who had not received chemotherapy and were referred for MRM. Patients requiring sentinel lymph node biopsy or radical mastectomy were excluded,

Received on 06-11-2023
Accepted on 29-12-2023

as were those whose MRM was abandoned because of operative findings.

Physical examination (index test 1): One senior registrar from the surgical department examined every patient. Both axillae were assessed for the number, size and location of palpable nodes and for fixation to one another or to underlying structures. The supraclavicular fossae and likely sites of distant spread were also examined. The axilla was recorded as positive when palpable nodes were judged clinically suspicious for metastasis.

Axillary ultrasound (index test 2): After the clinical examination, the ipsilateral axilla was scanned by one senior registrar from the radiology department on a single machine with a standard linear transducer. Patients lay supine or in a contralateral-side-down oblique position. A node was labelled abnormal if it measured more than 1 cm or showed a non-ovoid shape, an absent fatty hilum, intranodal necrosis, calcification, matting, a peripheral halo or prominent vascularity. Findings of both tests were entered on a checklist designed for the study.

Reference standard: All patients then underwent MRM with axillary dissection. The axillary specimens were examined by one senior registrar in histopathology. Nodal metastasis was diagnosed on loss of the fatty hilum, clusters of epithelial tumour cells within the node, or effacement of nodal architecture. Analysis was performed per patient: the axilla was histologically positive if any node contained tumour.

Control of bias: Consecutive sampling was used to limit selection bias. Observer bias was reduced by keeping the same examiner, sonographer, pathologist, ultrasound machine and data checklist for all patients.

Statistical analysis: Data were entered and analysed in SPSS version 25. Age and body mass index (BMI) are presented as mean ± standard deviation; categorical variables as frequency and percentage. Physical examination and ultrasound findings were each cross-tabulated against histopathology in a 2 × 2 table to derive true positives (TP), false positives (FP), false negatives (FN) and true negatives (TN). Sensitivity was TP/(TP+FN), specificity TN/(TN+FP), PPV TP/(TP+FP), NPV TN/(TN+FN) and diagnostic accuracy (TP+TN)/total, each × 100. Wilson score 95% confidence intervals (CI), positive and negative likelihood ratios (LR+, LR−) and Cohen's kappa for agreement with histopathology were calculated from the same tables. Effect modifiers were addressed by stratification for age group (18–40 and 41–80 years), family history of breast cancer, early menarche (<12 years), late menopause (>55 years), previous radiation exposure, nulliparity, hormone replacement therapy (HRT) and oral contraceptive pill (OCP) use. The association between each test and histopathology was assessed with the chi-square test, or Fisher's exact test when any expected cell count was below 5. A p-value <0.05 was taken as significant.

RESULTS

All 195 enrolled women completed both index tests and surgery and were included in the analysis. Their mean age was 49.17 ± 10.15 years and mean BMI 28.65 ± 1.73 kg/m²; 157 (80.5%) were older than 40 years (Table 1). Histopathology confirmed axillary metastasis in 58 patients (29.7%). Their tumour profile is shown in Table 2; invasive ductal carcinoma and grade 2 tumours predominated.

Tumour characteristics were recorded for patients with histologically positive nodes. Receptor status is given as the dominant receptor recorded for each tumour. ER: oestrogen receptor; PR: progesterone receptor; HER2: human epidermal growth factor receptor 2.

Physical examination labelled 40 axillae (20.5%) as positive and ultrasound 52 (26.7%), against 58 (29.7%) on histopathology (Table 3). Examination missed 25 of the 58 node-positive patients (43.1%), whereas ultrasound missed 12 (20.7%). False positives were few with both methods (7 and 6). Ultrasound therefore achieved a sensitivity of 79.3% against 56.9% for examination, with nearly identical specificity (95.6% vs 94.9%), and its agreement with histopathology was substantial (κ = 0.77) compared with moderate for examination (κ = 0.57) (Table 4, Figure 1).

Table 1: Baseline characteristics of the study population (n = 195)

Characteristic	Value
Age, years (mean ± SD)	49.17 ± 10.15
BMI, kg/m² (mean ± SD)	28.65 ± 1.73
Age 18–40 years, n (%)	38 (19.5)
Age 41–80 years, n (%)	157 (80.5)
Positive family history, n (%)	43 (22.1)
Early menarche (<12 years), n (%)	22 (11.3)
Late menopause (>55 years), n (%)	39 (20.0)
Previous radiation exposure, n (%)	22 (11.3)
Nulliparity, n (%)	8 (4.1)
Hormone replacement therapy, n (%)	20 (10.3)
Oral contraceptive use, n (%)	25 (12.8)

Table 2: Tumour characteristics of patients with histologically positive axillary nodes (n = 58)

Variable	Category	n (%)
Tumour type	Invasive ductal carcinoma	28 (48.3)
	Invasive lobular carcinoma	19 (32.8)
	Inflammatory breast cancer	8 (13.8)
	Other carcinoma	3 (5.2)
Histological grade	Grade 1	9 (15.5)
	Grade 2	33 (56.9)
	Grade 3	16 (27.6)
Dominant receptor status	ER	32 (55.2)
	PR	20 (34.5)
	HER2	6 (10.3)

Table 3: Physical examination and axillary ultrasound against histopathology (n = 195)

Index test	Result	Histopathology positive	Histopathology negative	Total
Physical examination	Positive	33 (TP)	7 (FP)	40
	Negative	25 (FN)	130 (TN)	155
Axillary ultrasound	Positive	46 (TP)	6 (FP)	52
	Negative	12 (FN)	131 (TN)	143
Total		58	137	195

Chi-square: physical examination 67.02, p <0.001; axillary ultrasound 116.99, p <0.001. TP: true positive; FP: false positive; FN: false negative; TN: true negative.

Table 4: Diagnostic performance of physical examination and axillary ultrasound

Measure	Physical examination, % (95% CI)	Axillary ultrasound, % (95% CI)
Sensitivity	56.9 (44.1–68.8)	79.3 (67.2–87.7)
Specificity	94.9 (89.8–97.5)	95.6 (90.8–98.0)
Positive predictive value	82.5 (68.1–91.3)	88.5 (77.0–94.6)
Negative predictive value	83.9 (77.3–88.8)	91.6 (85.9–95.1)
Diagnostic accuracy	83.6 (77.8–88.1)	90.8 (85.9–94.1)
Positive likelihood ratio	11.14	18.11
Negative likelihood ratio	0.45	0.22
Cohen's kappa	0.57	0.77

Confidence intervals by the Wilson score method.

After stratification, ultrasound sensitivity equalled or exceeded that of examination in all 16 subgroups (Figure 2). Among the larger subgroups, the difference reached about 26 percentage points in women aged 18–40 years (73.3% vs 46.7%) and in those without a family history (73.7% vs 47.4%). Bigger gaps appeared only in very small subgroups, such as nulliparous women and HRT users, where the estimates are unstable. Specificity of both tests stayed above 90% in every stratum except those with very few node-negative patients: the family-history-positive group (4 node-negative women) and nulliparous women (5).

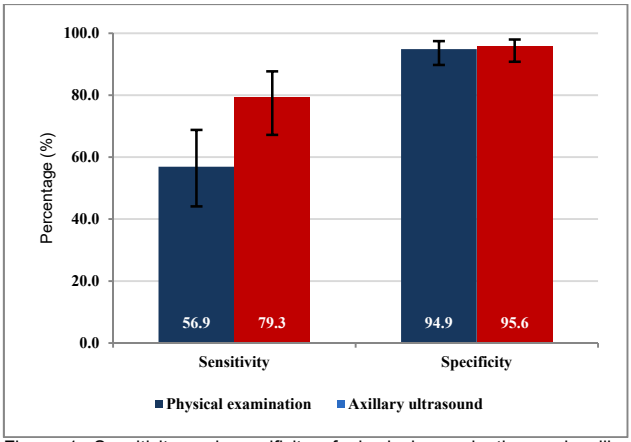

Figure 1: Sensitivity and specificity of physical examination and axillary ultrasound against histopathology of the dissected axilla (n = 195)

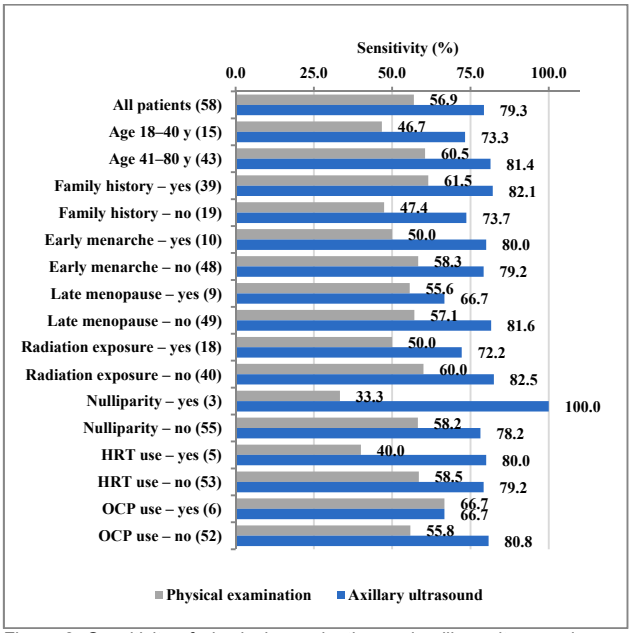

Figure 2: Sensitivity of physical examination and axillary ultrasound across subgroups of age and breast cancer risk factors

DISCUSSION

In this series of 195 women undergoing MRM, axillary ultrasound identified nodal metastasis in 79.3% of node-positive patients, compared with 56.9% for physical examination, while both tests kept specificity close to 95%. Put in clinical terms, palpation left 25 involved axillae undetected; ultrasound left 12. Overall accuracy rose from 83.6% to 90.8%, and agreement with histopathology moved from moderate to substantial. The advantage of ultrasound therefore lies almost entirely in finding disease that the examining hand cannot feel.

Our figures for physical examination fit the pattern reported elsewhere. Chen et al., studying 222 patients in Beijing, found a sensitivity of 54.2% and specificity of 90.0% for examination, against 86.8% and 72.5% for ultrasound[7]. In 140 Iranian patients, Olfatbakhsh et al. recorded an even lower examination sensitivity of 31% with specificity of 98%[8]. In an Indian series, Venkitaraman et al. found palpable axillary nodes in 96% of patients, many of doubtful significance, and concluded that clinical assessment often over-stages the axilla[14]. Together, these studies show that palpation misses a large share of involved axillae and can also be misled by reactive nodes. In our hands a positive examination was usually correct (PPV 82.5%), but a normal-feeling axilla offered little reassurance. Several factors in our cohort probably worked against palpation. Mean BMI was 28.7 kg/m², and axillary fat makes small nodes hard to feel. Low-volume deposits rarely enlarge a node enough to be palpable, and nodes behind the pectoralis minor lie beyond reach of the examining fingers[5,6].

Published ultrasound performance varies more widely. Chen et al. reported higher sensitivity than ours but specificity of only 72.5%[7], whereas Olfatbakhsh et al. found 56% and 88%[8]. In 383 Malaysian women, Jamaris et al. observed a sensitivity of 45.5%, specificity of 80.7% and accuracy of 60.3% for ultrasound alone[15]. Riedel et al. likewise concluded that routinely reported ultrasound cannot reliably confirm or exclude nodal disease in unselected early breast cancer, and that applying published diagnostic criteria did not improve its accuracy[16]. Venkitaraman et al. reported a sensitivity of 90.9% but a specificity of only 60.7% for ultrasound[14], while Hong et al. found 88.2% and 92.2% in 204 patients[17]. Much of this spread reflects case mix and threshold. Studies of screen-detected or clinically node-negative cancers contain many small metastases that are hard to see on any scan. Our patients were selected for MRM rather than sentinel node biopsy and likely carried a heavier axillary burden, which favours sensitivity. A strict, multi-feature definition of an abnormal node, applied by one experienced sonographer, would also explain why our specificity stayed high.

The false negatives deserve attention. Twelve women with nodal metastasis had a reassuring scan, giving a negative predictive value of 91.6% at a nodal prevalence of 29.7%. Pakistani series show the same weakness. Among 781 women with a normal pre-treatment scan in Lahore, Javed et al. found a false-negative rate of 19.7% and an NPV of 80.2%[18]. Khan et al. found that 45 of 262 women (17.2%) with normal axillae on ultrasound and mammography had nodal metastasis at surgery[19], and Mushtaq et al. found positive sentinel nodes in 5 of 29 women (17.2%) whose axillae looked benign on ultrasound[13]. Ultrasound also tends to underestimate how many nodes are involved; Vasigh et al. reported only 25% sensitivity for identifying more than two involved nodes in clinically node-negative patients[20]. A negative scan therefore cannot replace pathological staging, except in the carefully selected, low-risk groups in which the SOUND trial showed that axillary surgery can be omitted safely[11].

The obvious way to build on this is to sample every suspicious node. Pooled data show that ultrasound-guided fine-needle aspiration reaches a sensitivity of 79% and specificity of 96%, and core needle biopsy 85% and 93%[21]. A network meta-analysis also found that adding contrast-enhanced ultrasound to grey-scale imaging ranked highest among ultrasound-based approaches for detecting axillary metastasis[22]. Guided sampling would turn a positive scan into a pathological diagnosis before surgery, which matters most where it may change the operation[9,10]. For hospitals like ours, where ultrasound machines are widely available and inexpensive, a pathway of routine axillary scanning with biopsy of abnormal nodes is a realistic step up from palpation alone.

On stratified analysis, ultrasound performed at least as well as examination in every subgroup, which argues against any single risk factor explaining the overall difference. Some subgroup estimates should be read with caution. Only eight women were nulliparous and twenty used HRT, so their confidence intervals are wide. The family-history-positive group contained 39 node-positive and only 4 node-negative women; specificity and NPV in that stratum rest on four patients and cannot be interpreted meaningfully.

This study has several strengths. Patients were enrolled consecutively and prospectively, every patient received both index tests, and all underwent full axillary dissection. Every result was therefore checked against the same complete reference standard, avoiding the partial verification that affects sentinel-node-based studies. A single examiner, sonographer and pathologist, with one machine and one checklist, kept measurement consistent. There

are also limitations. It was a single-centre study, and the use of single operators means that inter-observer variability could not be assessed and that results may not transfer to less experienced hands. The sonographer was not documented as blinded to the clinical findings, which may have influenced borderline calls. The joint classification of each patient by both tests was not retained, so a paired comparison of sensitivities with McNemar's test was not possible; the comparison rests on separate estimates and their confidence intervals. Analysis was per patient rather than per node, no guided sampling was performed, and tumour characteristics were available only for node-positive patients.

CONCLUSION

Axillary ultrasound was clearly more sensitive than physical examination for detecting nodal metastasis in women with breast cancer undergoing MRM, and it was just as specific. It halved the number of node-positive patients missed before surgery. Ultrasound should be part of the routine preoperative staging of every woman with breast cancer, ideally combined with guided sampling of suspicious nodes. Palpation remains a useful bedside step, but it should not be used alone to stage the axilla.

Conflict of interest: The authors declare no conflict of interest.
Funding: This research received no external funding.

Authors' contribution: UA conceived the study, collected the data, performed the analysis and drafted the manuscript. MN reviewed the manuscript, HM was involved in manuscript drafting, MJ helped in project management and data collection and AA helped in data analysis of the study and critically revised the manuscript. All authors approved the final version.

REFERENCES

1. Sung H, Ferlay J, Siegel RL, Laversanne M, Soerjomataram I, Jemal A, et al. Global cancer statistics 2020: GLOBOCAN estimates of incidence and mortality worldwide for 36 cancers in 185 countries. CA Cancer J Clin. 2021;71(3):209-49. doi:10.3322/caac.21660
2. Zaheer S, Shah N, Maqbool SA, Soomro NM. Estimates of past and future time trends in age-specific breast cancer incidence among women in Karachi, Pakistan: 2004-2025. BMC Public Health. 2019;19(1):1001. doi:10.1186/s12889-019-7330-z
3. Idrees R, Fatima S, Abdul-Ghafar J, Raheem A, Ahmad Z. Cancer prevalence in Pakistan: meta-analysis of various published studies to determine variation in cancer figures resulting from marked population heterogeneity in different parts of the country. World J Surg Oncol. 2018;16(1):129. doi:10.1186/s12957-018-1429-z
4. Waks AG, Winer EP. Breast cancer treatment: a review. JAMA. 2019;321(3):288-300. doi:10.1001/jama.2018.19323
5. Chang JM, Leung JWT, Moy L, Ha SM, Moon WK. Axillary nodal evaluation in breast cancer: state of the art. Radiology. 2020;295(3):500-15. doi:10.1148/radiol.2020192534
6. Marino MA, Avendano D, Zapata P, Riedl CC, Pinker K. Lymph node imaging in patients with primary breast cancer: concurrent diagnostic tools. Oncologist. 2020;25(2):e231-42. doi:10.1634/theoncologist.2019-0427
7. Chen X, Li X, Fan Z, Li J, Xie Y, Wang T, et al. Ultrasound as a replacement for physical examination in clinical staging of axillary lymph nodes in breast cancer patients. Thorac Cancer. 2020;11(1):48-54. doi:10.1111/1759-7714.13224
8. Olfatbakhsh A, Haghighat S, Sari F, Beheshtian T, Hashemi EA, Jafari M. The accuracy of preoperative axillary ultrasound in the diagnosis of lymph node involvement at Motamed Cancer Institute, Iran. Int J Cancer Manag. 2020;13(4):e96383. doi:10.5812/ijcm.96383
9. Cardoso F, Kyriakides S, Ohno S, Penault-Llorca F, Poortmans P, Rubio IT, et al. Early breast cancer: ESMO Clinical Practice Guidelines for diagnosis, treatment and follow-up. Ann Oncol. 2019;30(8):1194-220. doi:10.1093/annonc/mdz173
10. Brackstone M, Baldassarre FG, Perera FE, Cil T, Chavez Mac Gregor M, Dayes IS, et al. Management of the axilla in early-stage breast cancer: Ontario Health (Cancer Care Ontario) and ASCO guideline. J Clin Oncol. 2021;39(27):3056-82. doi:10.1200/JCO.21.00934
11. Gentilini OD, Botteri E, Sangalli C, Galimberti V, Porpiglia M, Agresti R, et al. Sentinel lymph node biopsy vs no axillary surgery in patients with small breast cancer and negative results on ultrasonography of axillary lymph nodes: the SOUND randomized clinical trial. JAMA Oncol. 2023;9(11):1557-64. doi:10.1001/jamaoncol.2023.3759
12. Javid MS, Barry M. Axillary ultrasound as preoperative staging in clinical negative axillary lymph node breast cancer patient. Pak J Med Health Sci. 2021;15(5):1222-4.
13. Mushtaq A, Khan AA, Bano R, Naqvi SRQ, Nawaz S, Khan FA, et al. Concordance between axillary ultrasound and sentinel biopsy in clinically node-negative early breast cancer. Pak Armed Forces Med J. 2023;73(5):1330-3. doi:10.51253/pafmj.v73i5.7268
14. Venkitaraman B, Suhailudeen K, Thanaraj. Utility of preoperative staging of ipsilateral axilla with ultrasound and guided needle aspiration in early-stage breast cancer: current Indian scenario. Indian J Surg Oncol. 2018;9(4):505-10. doi:10.1007/s13193-018-0799-6
15. Jamaris S, Jamaluddin J, Islam T, See MH, Fadzli F, Rahmat K, et al. Is pre-operative axillary ultrasound alone sufficient to determine need for axillary dissection in early breast cancer patients? Medicine (Baltimore). 2021;100(19):e25412. doi:10.1097/MD.0000000000025412
16. Riedel F, Schaefgen B, Sinn HP, Feisst M, Hennigs A, Hug S, et al. Diagnostic accuracy of axillary staging by ultrasound in early breast cancer patients. Eur J Radiol. 2021;135:109468. doi:10.1016/j.ejrad.2020.109468
17. Hong CT, Yan YH, Su LY, Chen DB. Effect, sensitivity, specificity and accuracy of ultrasonic assessment of axillary lymph node-negative breast cancer. Pak J Med Sci. 2023;39(5):1366-71. doi:10.12669/pjms.39.5.7260
18. Javed N, Afzal S, Iqbal E, Aleem J, Parvaiz MA, Abu Bakar M. Efficacy of pre-operative axillary ultrasonography in excluding nodal disease: can it replace sentinel lymph node biopsy in early stage breast cancer? J Pak Med Assoc. 2023;73(2):307-12. doi:10.47391/JPMA.6118
19. Khan A, Masroor I, Khandwala K, Abbasi SU, Tariq MU. Utility of ultrasound and mammography in detection of negative axillary nodal metastasis in breast cancer. Cureus. 2020;12(1):e6691. doi:10.7759/cureus.6691
20. Vasigh M, Meshkati Yazd SM, Karoobi M, Hajebi R, Yazdankhah Kenari A. Does ultrasound evaluation of the axilla increase the rate of axillary lymph node dissection in early stage clinically node negative breast cancer patients? BMC Surg. 2022;22(1):80. doi:10.1186/s12893-022-01530-1
21. Zheng H, Zhao R, Wang W, Liu X, Wang X, Wen C, et al. The accuracy of ultrasound-guided fine-needle aspiration and core needle biopsy in diagnosing axillary lymph nodes in women with breast cancer: a systematic review and meta-analysis. Front Oncol. 2023;13:1166035. doi:10.3389/fonc.2023.1166035
22. Li J, Wang SR, Li QL, Zhu T, Zhu PS, Chen M, et al. Diagnostic value of multiple ultrasound diagnostic techniques for axillary lymph node metastases in breast cancer: a systematic analysis and network meta-analysis. Front Oncol. 2023;12:1043185. doi:10.3389/fonc.2022.1043185

This article may be cited as: Anwar U., Noor M., Munir H., Jamil M., Amanat A., Diagnostic Accuracy of Physical Examination versus Axillary Ultrasound for Nodal Staging of Breast Cancer in Patients Undergoing Modified Radical Mastectomy. Pak J Med Health Sci, 2023; 18(1): 1141-1144.