

# Role of T2 Textural Analysis of Prostate Lesion: A Retrospective Study

ALALI MESHARI ALI A<sup>1</sup><sup>1</sup>Department of Radiology, College of Medicine, Majmaah University, Al Majmaah, Saudi Arabia.Correspondence to: AlAli Meshari Ali A, Email: [me.alali@mu.edu.sa](mailto:me.alali@mu.edu.sa), ORCID ID: 0000-0002-5979-3733

## ABSTRACT

**Introduction:** Prostate cancer is diagnosed in two-thirds of instances in the world's more developed regions. Prostate cancer was detected in 180,890 new cases in the United States in 2016, according to the American Cancer Society. One out of every six men is projected to develop prostate cancer at some point in their lives. The study's major purpose was to develop a textural analysis-based classifier to differentiate between benign and malignant prostate tumors using MRI-T2WI.

**Materials and method:** The retrospective study was conducted in the department of radiology in KCUH. Total 93 lesions from prostate cases were performed in KCUH from 2015 to 2017. About 75 lesions of 48 patients were included in this study. Eleven haralick features from region of interest (ROIs) were extracted. After matching them with traces done by consultants in Profuse software, which was utilized for image-guided biopsy, digital rectal examination (DRE), prior biopsy (Prior bx) lesions were traced using ImageJ (MRI-ultrasound fusion). Weka software used this to create a classifier that distinguishes between malignant and benign tumors.

**Result:** The age of total 48 patients was in the interquartile range of 59.0-70.0, with an average of 64.4 years. The PSA was observed an average of 22.5 with an SD of 50.5 and an interquartile of 10.0. The mean size of the prostate was 3.2 cm with SD 1.9. Among 48 patients Digital rectal examination (DRE) 8 (16.7%) and 40 (83.3%), Prior biopsy (PRIOR BX) 2 (4.2%) and 46 (95.8%), PI-RADS 22 (45.8%) and 26 (54.2%) were observed positive and negative respectively. In DRE, 88% sensitivity 55% specificity with PSA 9.75 (p-value 0.008) were observed. 100% of sensitivity, 41% specificity with PSA 8.19 (p-value 0.897) were found in PRIOR BX, but in MRI, 55% of sensitivity 69% specificity with PSA 10.70 (p-value 0.107) were observed.

**Conclusion:** T2 texture analysis is good in classifying prostate lesions with acceptable sensitivity and specificity. T2W MRI-based textural analysis agreed with pathological findings from many institutions and was sensitive to underlying pathological differences between low- and intermediate/high-grade prostate cancers. Factors in the diagnostic performance, such as DWI/ADC and perfusion, histogram parameters, and other features with distinct orientations and lengths, could help doctors discriminate benign and malignant prostate nodules, allowing for more efficient and precise clinical decisions.

**Keywords:** Prostate lesion, MRI, textural analysis, cancer

## INTRODUCTION

The second most frequent malignancy in men is prostate cancer (PCa). 1 Prostate gland illnesses cause major morbidity and mortality in adult males around the world. <sup>2</sup> In the world's most developed regions, prostate cancer is diagnosed in two-thirds of cases. <sup>2</sup> According to the American Cancer Society, 180,890 new cases of prostate cancer were diagnosed in the United States in 2016. <sup>3</sup> One out of every six men is projected to develop prostate cancer at some point in their lives. It is more common in elderly men, with about 6 out of 10 cases found in men 65 and older. The average age at the time of diagnosis is roughly 67. Despite the fact that prostate cancer is a deadly disease, the majority of men who are diagnosed with it do not die from it. In fact, in the United States, more than 2.5 million men have had prostate cancer at some point in their lives and are still alive today. <sup>4</sup> Prostatic cancer was Pakistan's sixth most common malignancy, affecting 7.3 percent of men. <sup>5</sup> Prostate cancer affects a large percentage of older men (more than 70% of those over the age of 70). Prostate cancer has a very low death rate, especially for low-grade tumors.

It is a retroperitoneal organ with no defined capsule that encircles the bladder neck and urethra. In adults, the prostate's fibromuscular stroma can be divided into four biological and anatomical zones: peripheral, central, transitional, and anterior. Most hyperplasia begins in the intermediate zone, while most carcinoma begins in the peripheral zone. The most frequent illnesses affecting the prostate are prostatitis, benign prostatic hyperplasia, and prostate cancer. <sup>2</sup> Prostatitis is a prostate gland inflammation that produces frequent urination, dysuria, bodily discomfort, and, in certain cases, fever. There are both infectious and non-infectious kinds of prostatitis. <sup>6</sup> Textural analysis is an image-processing technique for analyzing picture signal heterogeneity that evaluates the coarseness and regularity of the spatial distribution of pixel grey level values within normal and damaged tissue (both at and beyond that noticed by the human eye). Especially in oncological imaging, which has recently been demonstrated to be effective in tumor detection/grading, prognosis, and therapeutic response, macroscopic heterogeneity in medical pictures could reflect microscopic heterogeneity at the histology level. <sup>7,8</sup>

Depending on how long a patient's life would be harmed, prostate cancer is categorized as clinically inconsequential or serious. Although there is no universally accepted definition for clinically relevant prostate cancer, the following is the most often accepted definition: Gleason score of 7 (containing 3 + 4 with a significant but not dominant Gleason 4 component), the volume of 0.5 cc, and/or extraprostatic extension (EPE). <sup>9</sup> Active surveillance, surgery, and radiotherapy are all possibilities for treating prostate cancer, depending on the Gleason score and clinical assessment of the patient's condition. <sup>10</sup>

MRI has become the tool of choice for diagnosing and staging prostate cancer. The European Society of Urogenital Radiology (ESUR) developed the "Prostate Imaging Reporting and Data System" (PI-RADS), which is based on breast imaging: PI-RADSTM version 1 (PI-RADSTM v1) is the first iteration of the PI-RADSTM system. <sup>12</sup> This first guideline was based on a summary score for each lesion that was investigated utilizing various mpMRI sequences, such as T2w, DWI, and DCE-MRI, as well as spectroscopy. The American College of Radiology (ACR), ESUR, and the AdMeTech Foundation formed a steering committee to upgrade these guidelines to the PI-RADSTM v2 standard. <sup>13,14</sup> The guidelines aimed to improve prostate cancer diagnosis, localization, characterization, and risk stratification in treatment-naïve prostates, as well as communication with referring urologists. The newest PI-RADS version scores each lesion on a 5-point scale to determine the likelihood of clinically relevant prostate cancer:

Scale point	Description
PI-RADS 1	Very low (clinically significant is highly unlikely)
PI-RADS 2	Low (clinically significant cancer is unlikely)
PI-RADS 3	Intermediate (the presence of clinically significant cancer equivocal)
PI-RADS 4	High (clinically significant cancer is likely)
PI-RADS 5	very high (clinically significant cancer is highly likely).

Our main goal of this study was to build a classifier based on textural analysis to classify prostate lesions into benign versus malignant based on MRI-T2WI.

**MATERIALS AND METHODS**

The retrospective investigation was carried out at KKHU's radiology department. Between 2015 and 2017, KKHU operated a total of 93 prostate lesions. The ethical permission was granted by the KKHU ethical committee. The results of the relevant histopathology were also obtained. Clinical image texture analysis is commonly used to investigate the relationship between histological data such as lesion severity and clinical prognosis.<sup>15-17</sup>

This study included patients who met the following criteria. 1. All cases with T2 sequence 2. Proven pathological prostatic lesions. 3. Prostatic MRI examination done. 4. Without any history of other tumors. Patients who had no pathological report, no MRI examination performed, poor image quality, and an incomplete imaging protocol was excluded from this study.

Using the PCa grading parameters issued by the 2014 International Urological Pathology Association Consensus, each patient's age, PSA levels, lesion volumes, Prostate Imaging Reporting and Data System (PI-RADS, version 2) score, and Gleason scores were recorded (in the case of lesions was confirmed to be PCa).<sup>18</sup>

All imaging was done on a 3 Tesla MRI system GE 1.5T with a 32-channel integrated spine coil and an 18-channel phased-array body coil. The axial T2-weighted turbo spin echo sequence had the following parameters: TR/TE = 5460/104 ms, FOV = 180180 mm2, matrix = 384384, slices = 24, slice thickness = 4 mm, gap = 0 mm, echo train length = 18, and acquisition time = 3 min 49 sec. The images were oriented along the longest axis of the prostate, perpendicular to the urethra, to best approximate standard histologic sectioning of the prostate.

Eleven haralick features from the region of interest (ROIs) were extracted. After matching them with traces done by consultants in Profuse software, which was utilized for image-guided biopsy, digital rectal examination (DRE), Prior biopsy (Prior bx) lesions were traced using ImageJ (MRI-ultrasound fusion). Weka software used this software to create a classifier that distinguishes between malignant and benign tumors. We used Weka to create a NaiveBase classifier that was verified using the 10-fold-cross validation method.

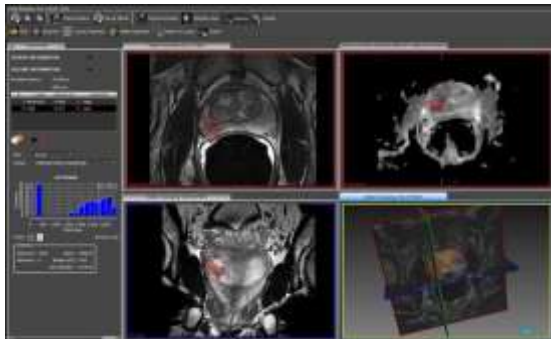


Fig.1: Axial T2-weighted image, COR T2 images, Axial Apparent Diffusion Coefficient (ADC) Map

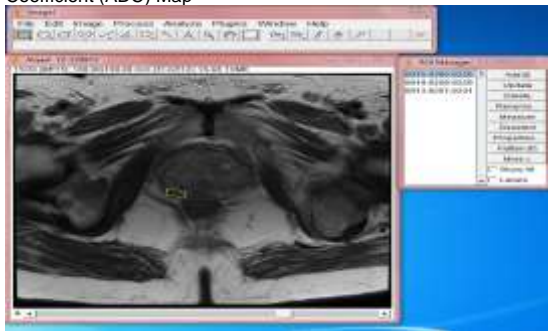

Fig. 2: Three-dimensional (3D) regions of interest that were segmented from T2-weighted magnetic resonance imaging (MRI).

**RESULT**

Total 93 lesions from prostate cases were performed in KKHU from 2015 to 2017. Among 93 lesions 18 lesions were excluded from this study due to lack of pathological reports. Only 75 lesions of 48 patients were included in this study.

Table 1: Descriptive statistics of quantitative variables

Variables	N	Mean	Std. Deviation	Median	IQR	Min	Max
Age	48	64.4	7.9	63.5	59.0-70.0	51.0	85.0
PSA	48	22.5	50.5	10.0	6.1-14.7	2.8	325.0
Prostate size	48	72.5	37.1	58.0	44.8-97.6	28.0	170.0
Targeted Bx cores/Pt	48	3.2	1.9	3.0	2.0-5.0	0.0	7.0

IQR: Interquartile Range

Table 1 shows the age of the total 48 patients interquartile range 59.0-70.0 with average 64.4 years. The PSA were observe average of 22.5 with SD of 50.5 and interquartile 10.0. The mean size of the prostate were 3.2 cm with SD 1.9.

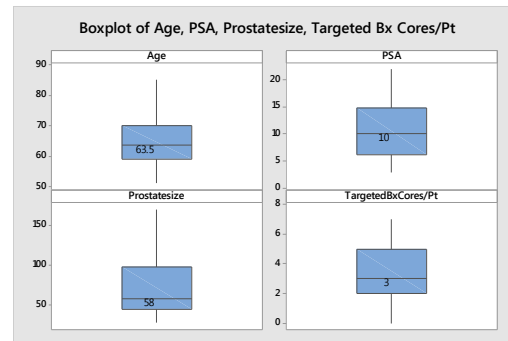


Figure 3: Box plot of quantitative variables

The box plot explains the different quantitative variables like Age, PSA, Prostate Size, and targeted biopsies cores/patients.

Table 2: Diagnostic results

Outcome	DRE	PRIOR BX	PI-RADS
Positive	8 (16.7%)	2 (4.2%)	22 (45.8%)
Negative	40 (83.3%)	46 (95.8%)	26 (54.2%)
Total	48 (100.0%)	48 (100.0%)	48 (100.0%)

Among 48 patients Digital rectal examination (DRE) 8 (16.7%) and 40 (83.3%), Prior biopsy (PRIOR BX) 2 (4.2%) and 46 (95.8%), PI RADS 22 (45.8%) and 26 (54.2%) were observed positive and negative respectively (table 2).

Table 3: Distribution by number of lesions observed

Number of MRI Lesions	Frequency
0	9 (18.8%)
1	20 (41.7%)
2	16 (33.3%)
3	3 (6.3%)
Total	48 (100.0%)

Table 3 shows Out of 48 patients, the most MRI lesion was found 1 MRI lesion was observed in 20 (41.7%), followed by 2 MRI lesion were observed in 16 (33.3%), 0 MRI lesion were observed in 9 (18.8%) and 3 MRI lesion were observed in 3 (6.3%).

The analysis of the MRI comparison to DRE and PRIOR BX on the basis of sensitivity, specificity is shown in figure 4. In comparison to MRI 100% sensitivity and NPV were observed in both, but 65% and 57% specificity, 36%, and 9% PPV were

recorded in DRE and PRIOR BX, respectively, with the accuracy of DRE (71%) and PRIOR BX (58%).

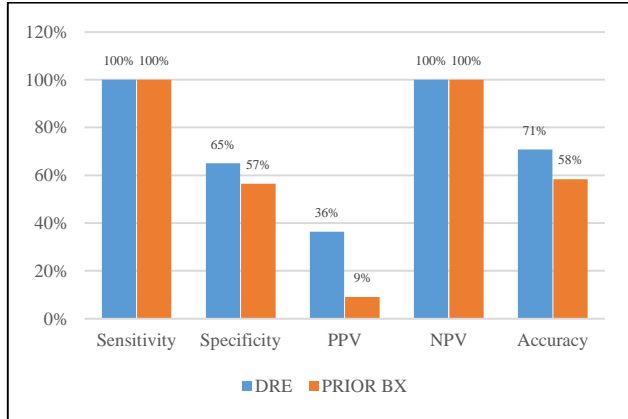


Figure 4: Sensitivity and specificity analysis of MRI in comparison to DRE and Prior Bx

The analysis of the MRI comparison to DRE and PRIOR BX on the basis of sensitivity and specificity is shown in figure 4. In comparison to MRI 100% sensitivity and NPV were observed in both, but 65% and 57% specificity, 36%, and 9% PPV were recorded in DRE and PRIOR BX, respectively with accuracy of DRE (71%) and PRIOR BX (58%).

Table 5: ROC analysis for predicting malignancy with 3 diagnostic tools

	AUC	Sensitivity	Specificity	PSA - Cut Off	P-value
DRE	80%	88%	55%	9.75	0.008
PRIOR BX	53%	100%	41%	8.19	0.897
MRI	64%	55%	69%	10.70	0.107

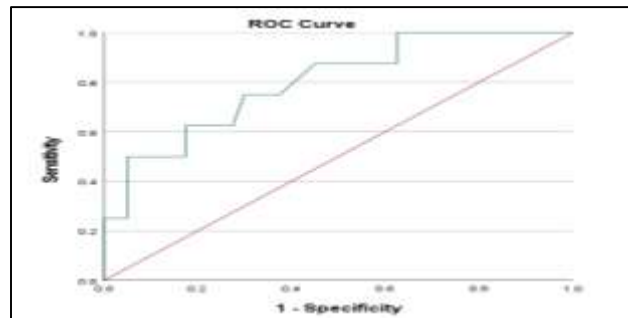


Figure 5: ROC for DRE

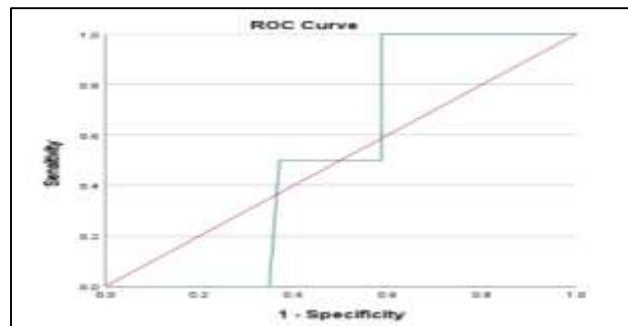


Figure 6: ROC for PRIOR BX

88% sensitivity, 55% specificity with PSA 9.75 (p-value 0.008) were observed in DRE. 100% of sensitivity, 41% specificity with PSA 8.19 (p-value 0.897) were found in PRIOR BX but in MRI

55% of sensitivity, 69% specificity with PSA 10.70 (p-value 0.107) were observed (Table 5).

Figure 5,6, and 7 shows the receiver operating characteristic (ROC) analysis curve graph according to texture analysis-based logistic regression model and other parameters. PI-RADSv2 = Prostate Imaging Reporting and Data System version 2. 88% sensitivity and 55% specificity, 100% sensitivity and 41% specificity, 55% sensitivity, and 69% specificity were observed in DRE, PRIOR BX, and MRI, respectively.

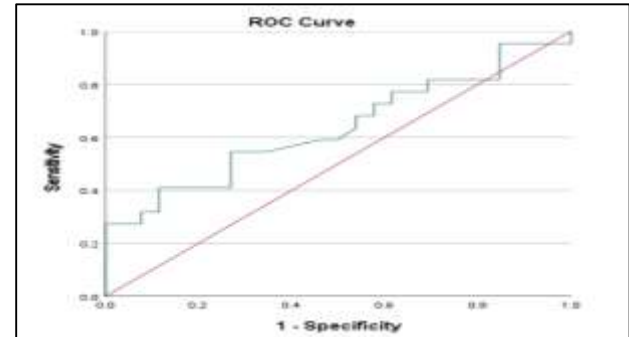


Figure 7: ROC for MRI

### DISCUSSION

T2W MRI has superior spatial resolution and tissue-specific contrast than DW and DCE imaging however, it is largely utilized for qualitative radiological evaluation of the prostate. In a pilot study using single-center data, we discovered that statistically calculated T2W image textural features have the potential to serve as non-invasive indicators for measuring aggressiveness.<sup>19</sup> Between 2015 and 2017, KKHU operated a total of 93 prostate lesions. Due to a lack of pathology data, 18 of the 93 lesions were omitted from the study. This study only included 75 lesions from 48 patients. A Vignati et al. looked at a similar number of patients.<sup>20</sup>

T2-weighted imaging offers a high spatial resolution and can separate the peripheral zone from the transition zone, allowing for the definition of zonal architecture.<sup>21</sup> Furthermore, in T2-weighted images, the peripheral zone has a high signal intensity, whereas prostate cancer (PCa) has a low signal intensity. Low T2 signal in the peripheral zone, on the other hand, can occur in benign conditions such as prostatitis, fibrosis, scar tissue, post-biopsy hemorrhage, and after irradiation. Although individual sequences are effective, T2-weighted imaging in combination with two functional sequences has been found to provide a superior characterization of PCa.<sup>22-24</sup>

Aggressive prostate cancers have poor differentiation, glandular structural deformation, and a loss of cellular integrity in the prostate gland. Correlations between textural features, prognostic factors, and clinical outcomes have also been reported.<sup>20,25</sup> If these quantitatively generated T2W image features are verified, they might be combined with other MRI data and used as evidence-based indicators for prostate cancer. This study's findings could be especially useful in active surveillance situations to track low-risk cancer patients and eliminate the need for recurring biopsies. In terms of patient tolerance and resilience to scanner oscillations and gradient mistakes, T2W imaging is widely regarded as the most stable sequence. Despite these characteristics, T2W imaging is not currently used for the quantitative assessment of prostate cancer aggressiveness due to the non-quantitative nature of its signal intensities.

MRI has been associated with significant advantages in PCa diagnosis, especially in cases of clinically severe and high-grade PCa.<sup>26</sup> The sensitivity and specificity of PI-RADSv2 for the diagnosis of clinically significant cancer were reported to be 0.77 and 0.73, respectively.<sup>27</sup> Our findings imply that PI-RADSv2 has a sensitivity and specificity for detecting PCa with GS 7 that is comparable to previous results. T2WI has been the standard

approach for prostatic MRI since it was originally described in the early 1980s, and it has been used to demonstrate prostatic zonation anatomies and locate lesions.<sup>28</sup> Tan et al. found that T2WI detection of PCa had overall sensitivity and specificity of 0.57–0.62 and 0.74–0.78, respectively.<sup>29</sup> In our research, we found comparable outcomes.

Texture features offer a lot of potential in terms of predicting lesion aggressiveness and clinical outcome. Those, on the other hand, are more likely to be affected by minor differences in imaging data, such as artifacts. As a result, reliability studies should be thoroughly validated before being used in clinical practice, not just for observers but also for imaging data.

This research has certain drawbacks. We started with patients who had radical prostatectomy because of the clear correlation between histology and mpMRI, but this strategy would have reduced the number of cases and lesions included in the analysis. Other sequences, like DWI/ADC and perfusion, would be integrated for a deeper understanding. Other elements with varying lengths and directions could be included.

## CONCLUSION

T2 texture analysis has high sensitivity and specificity for diagnosing prostate lesions. T2W MRI-based textural analysis agreed with pathological findings from many institutions and was sensitive to underlying pathological differences between low- and intermediate/high-grade prostate cancers. Other diagnostic markers, including DWI/ADC and perfusion, histogram parameters, and other features with distinct orientations and lengths, could aid clinicians in distinguishing between benign and cancerous prostate nodules, allowing for more efficient and precise treatment judgments.

**Acknowledgment:** The author would like to thank Dr Metaab alKubair for helping me in providing the data and the participants of the study.

## REFERENCES

- Torre LA, Bray F, Siegel RL, et al. Global cancer statistics, 2012. *CA Cancer J Clin* 2015; 65:87–108
- Anunobi CC, Akinde OR, Elesha SO, Daramola AO, Tijani KH, Ojewola RW: Prostate diseases in Lagos, Nigeria: a histologic study with tPSA correlation. *Nigerian Postgrad Med J* 2011, 18(2):98–104.
- American Cancer Society: Key statistics for prostate cancer . (2016). Accessed: June 4, 2016: <http://www.cancer.org/cancer/prostatecancer/detailedguide/prostate-cancer-key-statistics>
- Siegel R, Naishadham D, Jemal A: Cancer statistics, 2013. *CA Cancer J Clin* 2013, 63(1):11–30.
- Abrar Barakzai Muhammed MM, Iqbal KJ: Histopathological lesions in transrectal ultrasound-guided biopsies of prostate in patients with raised serum prostate-specific antigen: a preliminary report. *J Nephro-Urology Monthly* 2011, 3(3):186–190
- Prostate. <http://www.srhmmatters.org/sexual-health/prostate/>.
- Davnall F, Yip CS, Ljungqvist G, Selmi M, Ng F, Sanghera B et al (2012) Assessment of tumor heterogeneity: an emerging imaging tool for clinical practice? *Insights Imaging* 3:573–589
- Ganeshan B, Miles KA (2013) Quantifying tumour heterogeneity with CT. *Cancer Imaging* 13:140–149
- Ploussard G, Epstein JI, Montironi R, Carroll PR, Wirth M, Grimm M-O, et al. The contemporary concept of significant versus insignificant prostate cancer. *Eur Urol*. 2011;60(2):291–303.
- Mottet N, Bellmunt J, Briers E, van den Bergh RCN, Bolla M, van Casteren NJ, et al. Guidelines on Prostate Cancer 2015 v2. 2015. <http://uroweb.org/wpcontent/uploads/EAU-Guidelines-Prostate-Cancer-2015-v2.pdf>. Accessed 1 Dec 2015.
- Villers A, Lemaitre L, Haffner J, Puech P. Current status of MRI for the diagnosis, staging and prognosis of prostate cancer: implications for focal therapy and active surveillance. *Curr Opin Urol*. 2009;19(3):274–82.
- Barentsz JO, Richenberg J, Clements R, Choyke P, Verma S, Villeirs G, et al. ESUR prostate MR guidelines 2012. *Eur Radiol*. 2012;22(4):746–57.
- Weinreb JC, Barentsz JO, Choyke PL, Cornud F, Haider MA, Macura KJ, et al. PI-RADS Prostate Imaging - Reporting and Data System: 2015, Version 2. *Eur Urol*. 2016;69(1):16–40.
- Barentsz JO, Weinreb JC, Verma S, Thoeny HC, Tempany CM, Shtern F, et al. Synopsis of the PI-RADS v2 Guidelines for Multiparametric Prostate Magnetic Resonance Imaging and Recommendations for Use. *Eur Urol*. 2016;69(1):41–9.
- Lubner MG, Smith AD, Sandrasegaran K, Sahani DV, Pickhardt PJ (2017) CT texture analysis: definitions, applications, biologic correlates, and challenges. *Radiographics* 37:1483–1503 <https://pubs.rsna.org/doi/10.1148/rg.2017170056>
- Schieda N, Lim CS, Zabihollahy F, et al (2021) Quantitative prostate MRI. *J Magn Reson Imaging* 53:1632–1645. <https://doi.org/10.1002/jmri.27191>
- Lovinfosse P, Polus M, Van Daele D, et al (2018) FDG PET/CT radiomics for predicting the outcome of locally advanced rectal cancer. *Eur J Nucl Med Mol Imaging* 45:365–375. <https://doi.org/10.1007/s00259-017-3855-5>
- Egevad L, Delahunt B, Srigley JR, Samarantunga H. International Society of Urological Pathology (ISUP) grading of prostate cancer - An ISUP consensus on contemporary grading. *APMIS*. 2016;124:433–5
- Nketiah, G. et al. T2-weighted MRI-derived textural features reflect prostate cancer aggressiveness: preliminary results. *Eur. Radiol*. <https://doi.org/10.1007/s00330-016-4663-1> (2016).
- Vignati, A. et al. Texture features on T2-weighted magnetic resonance imaging: new potential biomarkers for prostate cancer aggressiveness. *Phys. Med. Biol.* 60, 2685–2701 (2015).
- Thompson, L.C.; Pokorny, M.R. Multiparametric MRI in the diagnosis of prostate cancer—A generational change. *Aust. Fam. Physician* 2015, 44, 597–602.
- Fütterer, J.J.; Heijmink, S.W.; Scheenen, T.W.; Veltman, J.; Huisman, H.J.; Vos, P.; Hulsbergen-Van de Kaa, C.A.; Witjes, J.A.; Krabbe, P.F.; Heerschap, A.; et al. Prostate cancer localization with dynamic contrast-enhanced MR imaging and proton MR spectroscopic imaging. *Radiology* 2006, 241, 449–458. [CrossRef]
- Tanimoto, A.; Nakashima, J.; Kohno, H.; Shinmoto, H.; Kuribayashi, S. Prostate cancer screening: The clinical value of diffusionweighted imaging and dynamic MR imaging in combination with T2-weighted imaging. *J. Magn. Reson. Imaging* 2007, 25, 146–152. [CrossRef]
- Turkbey, B.; Pinto, P.A.; Mani, H.; Bernardo, M.; Pang, Y.; McKinney, Y.L.; Khurana, K.; Ravizzini, G.C.; Albert, P.S.; Merino, M.J.; et al. Prostate cancer: Value of multiparametric MR imaging at 3 T for detection—Histopathologic correlation. *Radiology* 2010, 255, 89–99. [CrossRef]
- Gnep, K. et al. Haralick textural features on T2-weighted MRI are associated with biochemical recurrence following radiotherapy for peripheral zone prostate cancer. *J. Magn. Reson. Imaging* 45, 103–117 (2017).
- Barrett T, Turkbey B, Choyke PL. PI-RADS version 2: what you need to know. *Clin Radiol* 2015; 70:1165–1176
- Park SY, Jung DC, Oh YT, et al. Prostate cancer: PI-RADS version 2 helps preoperatively predict clinically significant cancers. *Radiology* 2016; 280:108–116
- Tan CH, Wei W, Johnson V, Kundra V. Diffusion-weighted MRI in the detection of prostate cancer: meta-analysis. *AJR Am J Roentgenol*. 2012;199: 822–9. 4
- Weinreb JC, Barentsz JO, Choyke PL, Cornud F, Haider MA, Macura KJ, Margolis D, Schnall MD, Shtern F, Tempany CM, et al. PI-RADS prostate imaging - reporting and data system: 2015, Version 2. *Eur Urol*. 2016;69:16–40.