

## ORIGINAL ARTICLE

# Diagnostic Accuracy of Diffusion Weighted MRI in Diagnosing Brain Abscess Taking Histopathology as Gold Standard

MUHAMMAD HASEEB IQBAL<sup>1</sup>, UMMARA SIDDIQUE UMER<sup>2</sup>, MUHAMMAD SALMAN RAFIQUE<sup>3</sup>, ABDULLAH SAFI<sup>4</sup>, SANA KUNDI<sup>5</sup>, MAHWISH JABEEN<sup>6</sup>, ALIYA SHARIF<sup>7</sup>

<sup>1</sup>Consultant Radiologist, DHQ Hospital, Bahawal Nagar

<sup>2</sup>Associate Prof. Radiology, Rehman Medical Institute, Peshawar

<sup>3</sup>Consultant Radiologist, Pakistan Kidney and Liver Institute and Research Center, Lahore

<sup>4</sup>Assistant Professor Radiology, RMI, Peshawar

<sup>5</sup>Resident Radiology department, RMI, Peshawar

Correspondence to Dr. Ummara Siddique Umer,

## ABSTRACT

**Aim:** Diagnostic accuracy of DW-MRI in diagnosing brain abscess taking histopathology as gold standard.

**Methodology:** A total of 407 patients having focal brain lesion on MRI of age 20-50 years of either gender were included. Patients with history of brain surgery, already established diagnosis on histopathology, claustrophobia and pregnant or breast feeding females were excluded. DW-MRI was done and conventional MRI sequences on 1.5 tesla MRI machine and presence or absence of brain abscess was noted. DW-MRI findings were correlated with histopathology.

**Results:** Mean age was  $38.53 \pm 7.59$  years. Out of these 407 patients, 262 (64.37%) were male and 145 (35.63%) were females with ratio of 1.8:1. Mean duration of disease was  $4.87 \pm 2.40$  months. Mean size of lesion was  $7.69 \pm 4.52$  mm. In DW-MRI positive patients, 221 were true positive and 32 were false positive. Among 154, DW-MRI negative patients, 18 were false negative whereas 136 were true negative (P-value=0.01). So in diagnosis of abscess in brain, sensitivity, specificity, PPV, NPV and DA of DW-MRI was 92.5%, 80.96%, 87.4%, 88.3% and 87.7% respectively.

**Conclusion:** DW-MRI is the non-invasive modality of choice having high diagnostic accuracy (DA) i.e. 87.7% in diagnosing brain abscess with sensitivity of 92.5% and specificity of 80.96%.

**Keywords:** Brain abscess, diffusion weighted imaging, sensitivity.

## INTRODUCTION

Infection of brain with abscess appears as ring enhancing cerebral lesion on enhanced MRI. Malignant lesions are on the top of differential diagnosis.<sup>1</sup> It is difficult to differentiate cystic or necrotic neoplastic brain lesions from abscess in brain. Differentiation is important because of subsequent management.<sup>2</sup> Abscess in brain tissue is encircled by hypo intense capsule especially in T2 WI<sup>3</sup>.

Diagnostic accuracy was increased by using DW-MRI and magnetic resonance spectroscopy (MRS)<sup>4</sup>. DW-MRI has the ability to look into diffusion characters of water molecules in tissue. There is difference in biochemical composition of the central part of brain abscess and cystic tumor. Other study<sup>5</sup> has shown the prevalence of brain abscesses as 36.67% and sensitivity and specificity of DW-MRI in diagnosing brain abscess as 94.7% and 81.8% respectively.

The objective of the study was to diagnose accuracy of DW-MRI in diagnosing brain abscess taking histopathology as gold standard.

## METHODOLOGY

Cross-sectional study was done in Radiology department, RMI, Peshawar for six months duration. Cases with brain lesion on MRI scan (hypointense lesion on T1-weighted imaging, no contrast enhancement, perifocal edema and rim enhancement) with duration >3 months were included. Age ranged 20-50 years and both genders were included. DW-MRI were obtained in all patients using 2D breath-hold T2-weighted half-Fourier acquisition single shot turbo spin-echo (HASTE), breath-hold T2-weighted TSE and dynamic contrast-enhanced 3D gradient-echo sequences. DW-MRI findings were compared with histopathology report. Data was analyzed using SPSS. 2x2 contingency table was used to calculate the sensitivity, specificity, positive predictive value, negative predictive value and diagnostic accuracy of DW-MRI in diagnosing brain abscess, taking histopathology as gold standard.

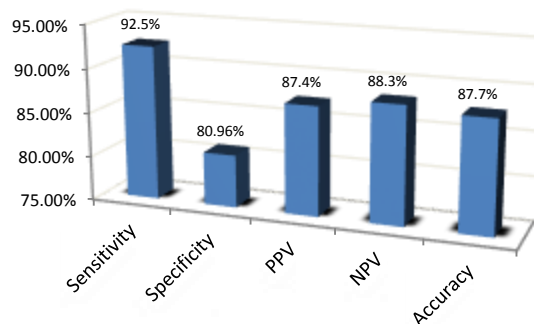
Table:

	+ve on DW-MRI	-ve on DW-MRI
+ve Histopathology	True +ve	False -ve
-ve Histopathology	False +ve	True -ve

## RESULTS

Age range in this study was from 20-50 years with mean age of  $38.5 \pm 7.6$  years. Majority of the patients 254(62.4%) were between 36 to 50 years of age. Out of these 407 patients, 262(64.4%) were male and 145(35.6%) were females with ratio of 1.8:1. Mean duration of disease was  $4.87 \pm 2.4$  months. Mean size of lesion was  $7.69 \pm 4.52$  mm. DW-MRI of brain was done in all cases. DW-MRI supported the diagnosis of brain abscess in 253(62.2%) patients. Histopathology findings confirmed brain abscess or necrotic brain tumor in 239(58.7%) cases. In DW-MRI positive patients, 221 were True Positive and 32 were False Positive. Among 154, DW-MRI negative patients, 18 were False Negative whereas 136 were True Negative (P-value=0.01). Fig 1 shows the Diagnostic accuracy of DW-MRI in diagnosing brain abscess. 100 true positive patients had lesion size >10mm. 161 true positive lesions had disease duration from 3-6 months, 136 true positive lesions were in patients' age range 36-50 years and 147 true positive lesions were in male patients. Permission was granted by IRB.

Fig 1: DW-MRI in diagnosing brain abscess



## DISCUSSION

Sensitivity, specificity, PPV, NPV and DA of DW-MRI in the diagnosis of brain abscess was 92.5%, 80.96%, 87.4%, 88.3% and 87.7% respectively in this study. A researcher<sup>5</sup> has shown the prevalence of brain abscesses as 36.7% and sensitivity and specificity of DW-MRI in diagnosing brain abscess as 94.7% and 81.8% respectively. In a local study<sup>7</sup>, for brain abscess diagnosis, DW-MRI had 98.8% sensitivity while specificity was 94% and 97.1% diagnostic accuracy. In another study<sup>2</sup>, sensitivity, specificity and diagnostic accuracy of D-MRI was 97.4%, 94.4%, 94.5% respectively. Chang SC et al<sup>8</sup> showed high sensitivity of DW-MRI as compared to conventional MRI, having sensitivity (93.3%), specificity (90.9%), PPV (93.3%) and negative predictive value of (90.9%). Reiche et al<sup>9</sup> reported that abscess containing cavities were hyper intense on DW-MRI and with low ADC values. 8 cases out of 10 with necrotic glioblastoma and 6 cases with metastatic cysts showed hypo intense area on DW-MRI and high ADC values.

In another study, there is difficulty in diagnosing ring-enhancing intracranial mass by clinical symptoms and conventional MRI. Visual inspection and signal intensity means cannot differentiate abscesses from cystic tumors.<sup>6</sup>

## CONCLUSION

DW-MRI has Sensitivity of 92.5% and Specificity of 80.96% in diagnosing brain abscess. So DW-MRI may be used in all suspected cases of intracranial lesions for accurate diagnosis of brain abscess.

Received on 11-09-2021  
Accepted on 23-03-2022

Conflict of interest: Nil

## REFERENCES

1. Lanphear J, Sarnaik S. Presenting symptoms of pediatric brain tumors diagnosed in the emergency department. *Pediatr Emerg Care*. 2014;30(2):77-80.
2. Alam SM, Sajjad Z, Azeemuddin M et al. DW- MRI of ring enhancing brain lesions. *J Coll Physicians Surg Pak*. 2012;22(7):428-31.
3. Wilne S, Collier J, Kennedy C et al. Progression from first symptom to diagnosis in childhood brain tumors. *Eur J Pediatr*. 2012;171(1):87-93.
4. Gasparetto EL, Cabral RF, da Cruz LC et al. Diffusion imaging in brain infections. *Neuroimaging Clin N Am*. 2011;21(1):89-113.
5. Sheisha DM, Amin MA, Soliman AY. Role of DW-MRI and proton magnetic resonance spectroscopy in ring enhancing brain lesions. *Egyptian J Radiol Nuclear Med*. 2014;45:825-32.
6. Mortimer A, O'Leary S, Bradley M et al. Pitfalls in the discrimination of cerebral abscess from tumor using DW- MRI. *Clin Radiol*2010, 65(6):488-92.
7. Ahmed MS, Shazlee MK, Usman R et al. Diagnostic accuracy of DW-MRI in the diagnosis of brain abscess. *Pak J Radiol*. 2016;26(4):305-311.
8. Chang SC, Lai PH, Chen WL et al. DW- MRI features of brain abscess and cystic or necrotic brain tumors: a comparison with conventional MRI. *Clin Imaging* 2002;26(4):227-36.
9. Reiche W, Schuchardt V, Hagen T, et al. Differential diagnosis of intracranial ring-enhancing cystic mass lesions – role of DW-MRI and diffusion-tensor imaging (DTI). *Clin Neurol Neurosurg* 2010; 112(3):218-25.