

Study of Histopathological Pattern of Endometrial Curettings and Healthcare Burden due to Inadequate Samples

SAMEEN EJAZ¹, MARYAM EJAZ², UMME KALSOOM³, MAHA KAMRAN⁴, DEEBA AHSAN⁵, SAMINA QAMAR⁵

^{1,3,4}Year MBBS student at King Edward Medical University, Lahore.

^{2,5}House Officer at Sir Ganga Ram Hospital, Lahore.

⁶Assistant Professor at Department of Pathology, King Edward Medical University, Lahore.

Correspondence to Sameen Ejaz Email: sameen.ejaz99@gmail.com, Telephone: +923034040866

ABSTRACT

Aim: To determine the frequency of different histopathological findings of endometrial curettings presenting to a tertiary care hospital with a special focus on the frequency of inadequate samples which impose a major healthcare burden.

Methods: The data of 975 female patients whose EC samples were received in the Pathology Lab of King Edward Medical University (KEMU), Lahore from August 2019- August 2021 was included in this retrospective, descriptive study. A statistical analysis of endometrial findings according to age and their association with histopathological findings was determined.

Results: A total of 975 cases were analyzed (average age, 42.95 years). 34.9% had hormone induced change (n=340), 235 had secretory endometrium (24.1%). Next in the list were Chronic Endometritis, proliferative phase and endometrial polyps accounting for 68(7%), 57(5.8%) and 16(1.6%) of the biopsies respectively. 1.6% patients had Endometrioid Carcinoma 16 and 9(0.9%) had Squamous cell carcinoma. 201(20.6%) of the total were inadequate biopsy specimens. There were 28 cases of hyperplasia, half of which were associated with atypia and half were without atypia, i.e., 14(1.4%). Atrophic endometrium and granulomatous inflammation accounted for 3(0.3%) and 2(0.2%) cases respectively.

Conclusion: A diverse spectrum of endometrial patterns was observed that included physiological as well as pathological patterns. The pathologies ranged from benign conditions to malignancies. There was a huge frequency of inadequate biopsies that were indicative of wastage of the limited resources of healthcare system.

Keywords: Dilatation and curettage, Endometrial carcinoma, Uterine diseases

INTRODUCTION

The uterine endometrium performs a number of important functions. These include preparing the uterus for implantation, maintaining the pregnancy if implantation occurs and menstruation in the absence of pregnancy¹. Any pathology in the endometrium can result in the disruption of these normal functions. It is very important to properly diagnose the underlying pathology in order to treat it. The most commonly used method for endometrial sampling is dilation and curettage (D & C)². It is the standard method used in countries with limited resources³. It can be done for either diagnostic or therapeutic reasons⁴. In this method, cervical dilators are first used that help in introducing instruments in the uterus and then the endometrial sample is taken with a curette⁵. Endometrial pathologies form a major bulk of workload in gynecology department⁶. Sampling of the endometrium can be very effective as the first step in the diagnosis of various pathologies of the endometrium. It is very important to attain an adequate sample for biopsy that can be analyzed in the histopathology lab⁷. Failure to do so can result in inadequate biopsy and negative findings. This results in a heavy burden on the healthcare resources of developing countries such as Pakistan. A wide range of morphological patterns can be observed, ranging from physiological changes in the endometrium to structural pathologies such as infections or tumors. The purpose of this study is to determine the histopathological pattern of endometrial curettings presenting to the histopathology department of a tertiary care hospital. This can give an idea of recent common endometrial pathologies diagnosed in Pakistan and their frequency in different age groups.

This study also discusses the frequency of inadequate samples that are sent for histopathological analysis causing a serious burden on the limited healthcare resources of Pakistan.

The objective of the study was to determine the frequency of different histopathological findings of endometrial curettings presenting to a tertiary care hospital with a special focus on the frequency of inadequate samples which impose a major healthcare burden.

Received on 10-09-2021

Accepted on 11-02-2022

MATERIAL AND METHODS

It was a retrospective study that was conducted at the pathology department of King Edward Medical University (KEMU), Lahore from August 2019 to August 2021. Ethical approval for conducting the study was obtained from the Institutional review board of King Edward Medical University, Lahore (IRB number 788/RC/KEMU). Reports of all the endometrial biopsies of non-pregnant patients presenting in the given time period were retrieved from the computer data base of the Pathology department, KEMU and included in the study. Cases with incomplete data were excluded from the study. 975 cases were included in the study. Age and histopathological findings were recorded. The youngest patient was 25 years old while the oldest patient was 85 years old. The data was divided into 6 age groups ranging from 25 to 85 years. The possible histopathological findings were tabulated under 12 headings i.e., inadequate tissue, secretory endometrium, proliferative endometrium, hormone induced change, chronic endometritis, hyperplasia with atypia, hyperplasia without atypia, granulomatous inflammation, atrophic endometrium, endometrial polyp, squamous cell carcinoma and endometrioid carcinoma. The data was entered and analyzed using spss version 23. The frequencies and percentages of histopathological findings in different age groups were calculated. Mean and median was calculated for quantitative data such as age and association of age with histopathological findings was found by cross tabulation. A p value of <0.05 was considered significant.

RESULTS

In this study, 1232 biopsies were evaluated at the Pathology department, KEMU. After applying the exclusion criteria, a total of 975 biopsies were analyzed. The age ranged from 25 years to 85 years with the mean age being 42.95±8.45 years. Maximum number of cases (51.8%) fell into the age group 36-45 years. The most commonly diagnosed histopathological finding was of hormone induced change in the endometrium accounting for about 340(34.9%) of cases followed by 235(24.1%) cases of secretory endometrium and 201(20.6%) cases with inadequate biopsy specimen. Chronic Endometritis, proliferative phase and endometrial polyps were next in the list accounting for 68(7%), 57(5.8%) and 16(1.6%) of the biopsies respectively.

Figure 1: Comparison of frequency of inadequate samples in Pakistan with other countries.

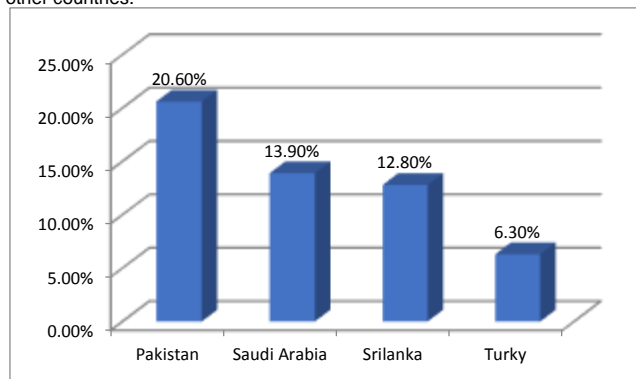


Table 1: Frequency of samples presenting in different age groups

Age Group (years)	Number of samples	%age
25-35	173	17.7
36-45	505	51.8
46-55	243	25
56-65	43	4.4
66-75	9	0.9
76-85	2	0.2
Total	975	100

Table 2: Spectrum of histopathological findings in different age groups (Percentages are rounded off)

Histopathological finding	Age groups						n	Percentage
	25-35	36-45	46-55	56-65	66-75	76-85		
Inadequate biopsy	25(2.56%)	89 (9.12%)	73 (7.5%)	13 (1.3%)	1 (0.1%)	0	201	20.6%
Secretory endometrium	55(5.64%)	136(13.95%)	41 (4.2%)	2 (0.2%)	1 (0.1%)	0	235	24.1%
Proliferative endometrium	12(1.23%)	35 (3.6%)	9 (0.92%)	1 (0.1%)	0	0	57	5.8%
Hormone induced change	54(5.54%)	188(19.3%)	87(8.92%)	11(1.13%)	0	0	340	34.9%
Chronic endometritis	19(1.95%)	33 (3.4%)	14(1.44%)	1 (0.1%)	1 (0.1%)	0	68	7%
Hyperplasia with atypia	1 (0.1%)	4(0.4%)	3 (0.3%)	5 (0.5%)	1 (0.1%)	0	14	1.4%
Hyperplasia without atypia	1 (0.1%)	9 (0.92%)	2 (0.2%)	1 (0.1%)	1 (0.1%)	0	14	1.4%
Granulomatous inflammation	2 (0.2%)	0	0	0	0	0	2	0.2%
Atrophic endometrium	0	0	3 (0.3%)	0	0	0	3	0.3%
Endometrial polyp	1 (0.1%)	9 (0.92%)	5 (0.5%)	1 (0.1%)	0	0	16	1.6%
Squamous cell carcinoma	2 (0.2%)	0	3 (0.3%)	3 (0.3%)	1 (0.1%)	0	9	0.9%
Endometrioid carcinoma	1 (0.1%)	2(0.2%)	3 (0.3%)	5 (0.5%)	3 (0.3%)	2 (0.2%)	16	1.6%
Tot (Number)	173	505	243	43	9	2	975	
Percentage	17.7%	51.8%	24.9%	4.4%	0.9%	0.2%		

There were 25 cases of carcinoma out of which endometrioid carcinoma was found in 16(1.6%) and Squamous cell carcinoma was found in 9(0.9%) of the total biopsies respectively. From a total of 28 cases of hyperplasia, half were associated with atypia and half were without atypia, i.e., 14(1.4%) each of the total cases analyzed. The least commonly occurring histopathological findings were atrophic endometrium and granulomatous inflammation accounting for 3(0.3%) and 2(0.2%) cases respectively. The most common histopathological finding in the first age group (25-35 years) was secretory endometrium. In the second (36-45 years) and third (46-55 years) age groups, the predominant condition was hormone induced change. Inadequate biopsy was the leading result in the fourth age group (56-65 years) followed by hormone induced change. In the fifth (66-75 years) and sixth (76-85 years) age groups, the most common histopathological finding was Endometrioid carcinoma. The number of samples presenting in different age groups are tabulated in table 1 and the spectrum of histopathological findings in different age groups in table 2. The p value was calculated to be <0.001 showing a significant association between age and histopathological findings.

DISCUSSION

The Analysis of endometrial biopsies is commonly indicated in patients presenting with abnormal uterine bleeding (AUB)⁸. The gold standard for diagnosing endometrial causes of AUB is endometrial biopsy or curettage⁹. Proper sampling of the endometrium followed by careful histopathological evaluation can help establish the definitive diagnosis. Endometrial lesions that necessitate endometrial sampling have a wide histopathological spectrum depending upon the age. This is shown in table-1. The mean age of patients in this study was 42.95 ± 8.45 years that is very similar to a previous study conducted by Shaheen U et al in the pathology department of DG Khan Medical College and Multan

Institute of Kidney Diseases, Pakistan over a period of two years (2017, 2018) (42.3 ± 8.5 years)⁹. In this study the risk of a pathological endometrial lesion increased with age. This is consistent with the findings of a previous study conducted by Ali SS et al in Armed Forces Institute of Pathology (AFIP), Rawalpindi, Pakistan from December 2013 to August 2015¹⁰.

The most common physiological pattern of histopathological findings of endometrial curettings was secretory phase followed by proliferative phase. Together both of these findings were seen in 292(29.9%) of the cases. This same pattern was reported by studies conducted in Pakistan, India and Saudi Arabia^{10,11,12}.

A large percentage of biopsies comprised of inadequate samples i.e., 201(20.6%) which is much more than that of other countries like Saudi Arabia (13.9%), Sri Lanka (12.8%) and Turkey (6.3%)^{12,13,14}. This comparison is illustrated in figure 1. A previous study conducted by Sarfraz T et al in Army Medical College Rawalpindi, from Jan to Dec 2018 showed the percentage of inadequate biopsies to be 29.54%¹⁵. This huge percentage shows the lack of skillful approach in obtaining adequate samples for histopathological evaluation. This is also indicative of how Pakistan is far behind other countries in health care provision. Pakistan is already a low resource country and such a big number of inadequate samples further depletes the scanty health care resources. This can be prevented by improving the sample-drawing skills of health care professionals by organizing workshops and launching programs and seminars to improve quality of health care and better utilization of the limited resources.

The most common histopathological pattern observed was Hormone Induced change in the endometrium 340(34.9%) with maximum number of cases in the age group 36-45 years (n=188). We included disordered proliferative endometrium and pill endometrium (resulting from unopposed hormone therapy in the form of oral contraceptive pills) within this category. The frequency of hormone induced endometrium was comparable to the study of

Ali SS et al (25.9%) and much higher than other studies conducted by Husain S et al in Saudi Arabia (15.5%) and Kaur A et al in India (20.6%)^{10,11,12}.

Granulomatous inflammation of endometrium was found to be present in 2(0.2%) of biopsies that was similar to the findings of Shaheen U et al (0.6%)⁹ and the study of Abubakar M et al (0.46%) conducted in Nigeria from January 2014 to December 2018¹⁶. Mycobacterium tuberculosis is one of the most common causes of granulomatous endometritis specially in developing countries. Pakistan, being a developing country has a huge burden of systemic tuberculosis. In this study, there were two cases of granulomatous inflammation. Histopathological report of both the cases showed caseous necrosis that was suggestive of tuberculosis. Both the cases were in women aged between 25-35 years. This showed that granulomatous endometritis due to tuberculosis is more likely to present in younger women. This is supported by a previous study conducted by Aslan G et al in Turkey¹⁷. Genital tuberculosis is usually asymptomatic and remains underdiagnosed. A very common presenting complaint of genital tuberculosis is infertility⁽¹⁸⁾. This could also be a reason for its increased presentation in younger menstruating women who wish to conceive as compared to older postmenopausal women.

Endometrial Polyps are epithelial proliferations in the endometrium, and consist of glandular, fibromuscular, vascular and connective tissue¹⁹. The frequency of endometrial polyps in this study was 16(1.6%) that is similar to that of Ali SS et al (0.8%) and much lower as compared to the studies of Husain S et al (18.3%) and Shaheen U et al (10.8%)^{9,10,12}. The reason of this low frequency could be that all patients with endometrial polyps are not symptomatic as a study conducted by Tanos V et al suggested that patients with endometrial polyps may be asymptomatic or present commonly with abnormal uterine bleeding¹⁹. Also, it is not easy to identify endometrial polyps on curettings⁽¹⁰⁾. For the diagnosis of endometrial polyps, it is important to take the history of the patient's bleeding pattern if she presents with abnormal uterine bleeding.

Endometrial carcinoma is the 6th most common gynecological malignancy globally²⁰. It is also a major cause of morbidity and mortality in South Asia²¹. The frequency of endometrial carcinoma in this study was 25(2.5%) that is slightly higher than the findings of Husain S et al (1.9%)¹². However, it was higher than the previous studies conducted by Ali SS et al and Shaheen U et al in Pakistan (0.3% and 0.6%)^{9,10}. This showed an increase in the frequency of endometrial carcinoma since 2016. Endometrial carcinoma was subtyped as squamous cell carcinoma (0.9%) and endometrioid carcinoma (1.6%). Overall, Endometrial carcinoma was most common in ages 49-60 years which was similar to the results of the study conducted by Thirukumar M et al in Sri Lanka¹⁴. The peak occurrence of endometrioid carcinoma was in the age group 56-65 years that was consistent with the previous study conducted by Tai YJ et al from 1998 to 2017 in Taiwan²². An unexpected finding was the presence of endometrial carcinoma in 3 cases (12% of all cases of endometrial carcinoma) less than 30 years of age. This age group was younger than that reported by Thirukumar M et al who reported 5 cases (17% of all cases of Endometrial carcinoma) in age less than 40 years¹⁴. The frequency of atrophic endometrium was found to be 3(0.3%) that was comparable to the studies of Ali SS et al and Shaheen U et al (2.1% and 1.3%)^{9,10}. On the other hand, it was lower than the frequencies reported by Husain S et al and Inal ZO et al (11% and 3.7%)^{12,13}. All these women were post-menopausal i.e above 50 years of age. This low frequency can be explained by the fact that most of the endometrial samples in this study were from women in the reproductive and perimenopausal stage whereas atrophic endometrium presents in postmenopausal women. Postmenopausal women are less likely to present as they do not have complaints of menorrhagia or intermenstrual bleeding.

Endometrial hyperplasia is the proliferation of the endometrial glands and is a known precursor to endometrial carcinoma²³. The risk of progression of atypical hyperplasia to

endometrial carcinoma is about 8-29%²⁴. Endometrial hyperplasia was classified in this study according to the WHO classification (2014) as hyperplasia with atypia and hyperplasia without atypia. Collectively both comprised of 28(2.8%) of the total samples and the individual frequencies of both types were same i.e., 14(1.4%). This was lower as compared to the previous studies conducted by Ali SS et al, Abubakar M et al and Shaheen U et al (8.4%, 7.1%, 5.2%, 7%)^{9,10,16}. This low frequency indicates that it is relatively an underdiagnosed condition. On the other hand, the frequency of endometrial carcinoma was higher in this study as compared to other studies. This showed that most women here present only when the endometrial hyperplasia has progressed to endometrial carcinoma. This raises the necessity of screening programs for women as early detection of this precursor lesion of endometrial carcinoma can give time for preventive strategies against it. Hence, early diagnosis and timely management can prevent mortality and morbidity by this life-threatening disease.

Chronic endometritis is the continuous inflammation of the endometrial mucosa²⁵. It was found to be present in 68(7%) of the total histopathological samples. This was similar to the results of Abubakar M et al (6%), lower than the findings of Ali SS et al and Shaheen U et al (10.8% and 16%) and higher than that of Husain S et al (4.8%)^{9,10,12,16}. Thus, the frequency of chronic endometritis showed marked variation in various studies.

CONCLUSION

It is very important to properly diagnose the endometrial pathologies as they have a diverse spectrum ranging from normal endometrium to malignancy. The definitive diagnosis requires skilled endometrial sampling and careful microscopic examination of the tissue. A variety of histopathological patterns were observed in this study. There was a big percentage of inadequate samples that indicated the wastage of the limited resources. Improper sampling is also a source of discomfort for the patient as the sampling has to be repeated.

Conflict of interest: Nil

REFERENCES

1. Critchley HO, Maybin JA, Armstrong GM, Williams AR. Physiology of the endometrium and regulation of menstruation. *Physiological reviews*. 2020 Apr 29.
2. Rauf R, Shaheen A, Sadia S, Waqar F, Zafar S, Sultana S, Waseem S. Outpatient endometrial biopsy with Pipelle vs diagnostic dilatation and curettage. *Journal of Ayub Medical College Abbottabad*. 2014 Jun 1;26(2):145-8.
3. Jetley S, Rana S, Jairajpuri ZS. Morphological spectrum of endometrial pathology in middle-aged women with atypical uterine bleeding: A study of 219 cases. *Journal of mid-life health*. 2013 Oct;4(4):216.
4. Barry L, Manning H, Chesterman E, Izzo L, Strockyj S. Thrombotic microangiopathy following a minor gynaecological procedure in the setting of endometrial cancer: a case report. *Case Reports in Women's Health*. 2021 Oct 1;32:e00354.
5. Braaten KP, Dutton C. Dilatation and curettage
6. Shivangi PD, Mohapatra D. Comparative Study of Endometrial Aspiration Cytology Using Pipelle with Hysteroscopic Guided Endometrial Biopsy in Patient with AUB (Abnormal Uterine Bleeding).
7. Piatek S, Warzecha D, Kisielewski F, Szymusik I, Panek G, Wielgos M. Pipelle biopsy and dilatation and curettage in clinical practice: are factors affecting their effectiveness the same?. *Journal of Obstetrics and Gynaecology Research*. 2019 Mar;45(3):645-51.
8. Singh P. Abnormal uterine bleeding-evaluation by endometrial aspiration. *Journal of mid-life health*. 2018 Jan;9(1):32.
9. Shaheen U, Majeed S, Khan YN, Adnan HA, Khalid M, Shaheen H. Morphologic patterns of endometrium in biopsy/curettage specimen of patients with abnormal uterine bleeding. *Pakistan Journal of Physiology*. 2020 Mar 31;16(1):24-7.
10. Ali SS, Muhammad I, Shaukat J, Afzal S, Hashmi SN, Hamdani SN, Ahmed R. Histopathological spectrum of endometrial biopsies—a study of 378 cases at AFIP Pakistan. *PAFMJ*. 2016;66(Suppl-3):S194-98.

11. Kaur A, Kour B, Kaur S. Histopathological patterns of endometrium in abnormal uterine bleeding—a one year retrospective study.
12. Husain S, Al Hammad RS, Alduhaysh AK, AlBatly MM, Alrikabi A. Pathological spectrum of endometrial biopsies in Saudi women with abnormal uterine bleeding. *Saudi Med J*. 2021;42(3):270-9.
13. Inal ZO, Inal HA, Kucukosmanoglu I, Kucukkendirici H. Assessment of endometrial sampling and histopathological results: Analysis of 4,247 cases. *The Eurasian journal of medicine*. 2017 Feb;49(1):44.
14. Thirukumar M, Ahilan S. Histopathological Pattern of Endometrium: Hospital Based Study in Teaching Hospital, Batticaloa, Srilanka. *Open Journal of Obstetrics and Gynecology*. 2018 Sep 3;8(11):1015-22.
15. Sarfraz T, Tahir H, Wazir L, Tariq H, Khan SA, Jaffar SR. Diagnostic adequacy and histological outcome of pipelle endometrial biopsies. *PAFMJ*. 2021 Feb 23;71(1):57-61.
16. Abubakar M, Kabir B, Liman AA, Shehu SM, Kankia BL, Yahya A, Ali ZA. Histopathologic analysis of endometrial biopsies in a Northern Nigerian Teaching Hospital. *Annals of Tropical Pathology*. 2020 Jul 1;11(2):101.
17. Aslan G, Ulger M, Ulger ST, Durukan H, Yazici FG, Emekdas G. Female genital tuberculosis cases with distinct clinical symptoms: Four case reports. *International Journal of Reproductive BioMedicine*. 2018 Jan;16(1):57.
18. Tal R, Lawal T, Granger E, Simoni M, Hui P, Buza N, Pal L. Genital tuberculosis screening at an academic fertility center in the United States. *American Journal of Obstetrics and Gynecology*. 2020 Nov 1;223(5):737-e1.
19. Tanos V, Berry KE, Seikkula J, Abi Raad E, Stavroulis A, Sleiman Z, Campo R, Gordts S. The management of polyps in female reproductive organs. *International Journal of Surgery*. 2017 Jul 1;43:7-16.
20. Lortet-Tieulent J, Ferlay J, Bray F, Jemal A. International patterns and trends in endometrial cancer incidence, 1978–2013. *JNCI: Journal of the National Cancer Institute*. 2018 Apr 1;110(4):354-61.
21. Hashmi AA, Mudassir G, Hashmi RN, Irfan M, Asif H, Khan EY, Bakar SM, Faridi N. Microsatellite instability in endometrial carcinoma by immunohistochemistry, association with clinical and histopathologic parameters. *Asian Pacific journal of cancer prevention: APJCP*. 2019;20(9):2601.
22. Tai YJ, Chiang CJ, Chiang YC, Wu CY, Lee WC, Cheng WF. Age-Specific Trend and Birth Cohort Effect on Different Histologic Types of Uterine Corpus Cancers.
23. Singh G, Puckett Y. Endometrial hyperplasia. *StatPearls [Internet]*. 2021 Jul 26.
24. Sobczuk K, Sobczuk A. New classification system of endometrial hyperplasia WHO 2014 and its clinical implications. *Przegląd menopauzalny= Menopause review*. 2017 Sep;16(3):107. Moreno I, Cicinelli E, Garcia-Grau I, Gonzalez-Monfort M, Bau D, Vilella F, De Ziegler D, Resta L, Valbuena D, Simon C. The diagnosis of chronic endometritis in infertile asymptomatic women: a comparative study of histology, microbial cultures, hysteroscopy, and molecular microbiology. *American journal of obstetrics and gynecology*. 2018 Jun 1;218(6):602-e1.