

Anatomical Variations on Routine CT Scans Observed in the Paranasal Sinuse

AHMAD BIN KHALID¹, AYESHA SIDDIQA², SYED IMRAN HAIDER³, GOHAR ALAM⁴, NADEEM AKRAM BUTT⁵

¹Medical Officer, General Surgery Pak Red Crescent Hospital, Kasur

²Incharge Medical Officer, BHU Nasserwala, Mianwali

³Assistant Professor Radiology, Sahara Medical College, Narowal

⁴Medical Officer, Orthopedic and Trauma Unit, Qazi Hussain Ahmed Medical Complex, Nowshera

⁵Consultant Radiologist, Health Point Hospital, Abu Dhabi UAE

Corresponding Author: Syed Imran Haider, Email: drimranfcp@yahoo.com, Cell: +92 331 4351976

ABSTRACT

Objective: The aim of current study is to determine the frequency of anatomical variants on routine CT scan observed in the paranasal sinus.

Stud Design: Cross-sectional

Place and Duration: The study was conducted at Radiology department of Jinnah Hospital, Lahore for the duration of nine months from January 2021 to September 2021.

Methods: There were 90 sinus patients of both genders with ages 20-55 years in this study. Cases were recruited after informed written permission was obtained and data such as gender and BMI were collected. The prevalence of various anatomical variations of the sinonasal cavities was determined based on the results of the CT scans. Anatomical differences between individuals with low to no apparent imaging evidence of rhinosinusitis vs those with clinically substantial radiologic evidence of rhinosinusitis were examined in this study. SPSS 21.0 was used to analyze complete data.

Results: Among 90 cases, the majority of the patients were males 63 (70%) and 27 (30%) were females with mean age 33.41±8.56 years and mean BMI 23.22 ±5.31 kg/m². According to Kero's classification to determine the difference in olfactory fossa depth, most of the patients 62 (68.9%) were in type II, 20 (22.2%) in type I and 8 (8.9%) in type III. In accordance with anatomical variation, we found that most of the patients 65 (72.2%) had deviated nasal septum (DNS) followed by agger nasi cells in 61 (67.8%) cases and concha bullosa in 35 (38.9%) cases.

Conclusion: We concluded in this study that the prevalence of anatomical variants among patients of paranasal sinus was higher in which the majority of the patients had deviated nasal septum and agger nasi cells.

Keywords: Frontal sinus, Paranasal Sinus, Maxillary sinus, Anatomical variants

INTRODUCTION

These days, computed tomography of the nasal and sinus cavities, or PNS, is considered the most reliable method for diagnosing nasal and sinus illness. [1] When compared to conventional radiography, sinus CT provides a wealth of information about anatomical soft tissue and bone structures that is important for making a diagnosis and planning a successful surgical procedure.

ESS is a frequent operation that requires an in-depth evaluation of the patient and a comprehensive radiological description of the anatomy, including any anatomical changes in the nose or PNS.[2] As contentious as it may be,[3] anatomical differences in the osteomeatal complex may have some part in the genesis of sinonasal illness, but knowing about these changes in each patient before surgery helps prevent injury to nearby essential tissues like the orbit and brain. Depending on the ethnic group, these variances may occur more often or less frequently. [4] There is no evidence of anatomical differences in our population's nose and PNS.

An air-filled cavity is found in the face and skull bones in the paranasal sinuses (PNS). Maxillary, sphenoid, ethmoid, and frontal sinuses are all named for the bones in which they are placed. In addition to making the voice more resonant, PNS devices lessen the weight of the user's head and increase air humidity. [5]

On computed tomography, sinonasal anomalies may be seen in large numbers (CT). Among them, the most often detected structural variations are agger nasi cells, deviated nasal septum (DNS), infraorbital sphenoidal (Haller) cells, and concha-bullosa (CB). Prior to and inferolateral to the frontal recess, the agger nasi cells are the most anterior ethmoidal air cells. Infraorbital ethmoidal cells are located under the medial floor of the orbit, just above and lateral to the maxillary sinus ostium. Proximal to the sphenoid sinus cavity, the ethmoidal-cells of the posterior ethmoidal region extend superolaterally, and these cells are strongly connected with CNS II. Any nasal-septal bending is what is meant by DNS. Pneumatization (development of air-cells) of the middle turbinate, which is most often bilateral and involves the inferior bulbous region, is what is meant by CB. The inability to

detect distinct anatomical variances has been documented to cause difficulties during surgical procedures. [6]

There are major anatomical variances in the human body, such as the nasal cavity and the PNS. Many anatomical variations may impede the ostiomeatal complex's mucociliary drainage channel, including DNS, CB, paradoxical middle turbinates, uncining processes (UP), ethmoid bulla and numerous air cells in the ethmoid cavity. Recent advances in endoscopic sinus surgery and CT imaging have sparked an increased interest in the anatomy of the nasal cavity and the posterior nasal spine (PNS). [7] In order to spread and cause rhinosinusitis, OMC is the most important location. Rhinosinusitis impairs cilia action, resulting in mucus buildup in the sinuses. A little distention of the mucosa may lead to repeated infections and severe inflammation of the mucosal membrane in the sinonasal region if there is an anatomical variance, such as a constriction of the OMC. [8,9]

Anatomical variations of OMC may not have a role in the genesis of sinonasal pathology, but complete understanding of anatomical variants in every individual is essential before planning for surgery to minimise harm to the orbit and brain. Radiology is increasingly turning to CT-PNS and FESS to diagnose and treat sinonasal morphology and diseases. [10-12]

Patients with symptoms of sinusitis who got CT scans at the hospital were the focus of this research.

MATERIAL AND METHODS

This cross-sectional study was carried out at Radiology department of Jinnah Hospital, Lahore for the duration of nine months from January 2021 to September 2021 and consisted of 90 cases. Cases were recruited after informed written permission was obtained and data such as gender and BMI were collected. Patients who had history of sinonasal surgery or had a sinonasal malignancy, < 20 years of age, other medical illness and those who did not give any written consent were excluded from this study.

This task force's key criteria were used to diagnose all patients with rhinosinusitis, and no further criteria were used. Face discomfort, pressure, nasal blockage and hyposmia were among

the symptoms. The sinonasal cavities on the CT images were examined for anatomical variations. Each variant's prevalence was determined. Nasal and paranasal sinus disease severity was also assessed using computed tomography (CT) images. Anatomic variations in the paranasal sinus and nasal cavity were studied for their frequency. Type I has an olfactory fossa depth of around 3 millimetres, type II's is 4-7 millimetres, and type III's is 8-14 millimetres, according to kero's categorization. Data were analysed using SPSS 21.0.

RESULTS

Among 90 cases, the majority of the patients were males 63 (70%) and 27 (30%) were females with mean age 33.41±8.56 years and had mean BMI 23.22 ±5.31 kg/m².(table 1)

Table 1: Demographic details of included cases

Variables	Frequency	Percentage
Mean age (years)	33.41±8.56	
Mean BMI (kg/m ²)	23.22 ±5.31	
Gender		
Male	63	70
Female	27	30

According to Kero's classification to determine the difference in olfactory fossa depth, most of the patients 62 (68.9%) were in type II, 20 (22.2%) in type I and 8 (8.9%) in type III.(fig 1)

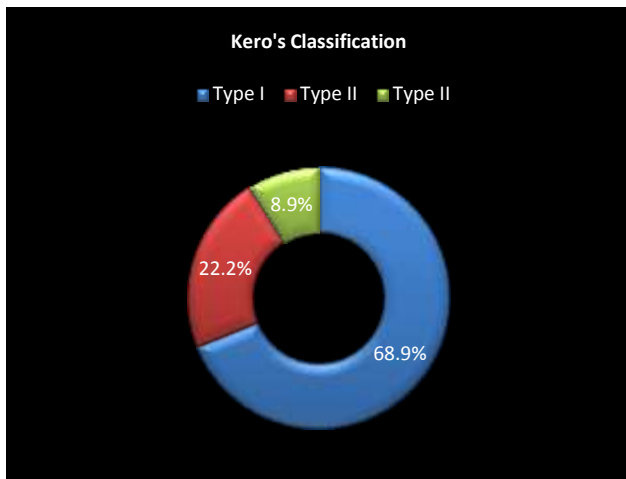


Figure 1: Olfactory fossa depth among cases with kero's classification

Table 2: Percentage of enrolled patients with anatomical variance in the paranasal sinuses

Variables	Frequency	Percentage
Deviated nasal septum (DNS)		
Yes	65	72.2
No	25	27.8
Agger nassi cells		
Yes	61	67.8
No	29	32.2
Concha bullosa		
Yes	35	38.9
No	55	61.1
Haller cells		
Yes	21	23.3
No	69	86.7
Septated maxillary sinus		
Yes	19	22.2
No	71	77.8
Onodi cells		
Yes	16	17.8
No	74	82.2
Hypertrophied ethmoid sinuses		
Yes	3	3.3
No	87	96.7

In accordance to anatomical variation, we found that most of the patients 65 (72.2%) had deviated nasal septum (DNS) followed by agger nassi cells in 61 (67.8%) cases, concha bullosa in 35 (38.9%) cases, haller cells in 21 (23.3%), septated maxillary sinus in 19 (22.2%) cases, onodi cells in 16 (17.8%) and hypertrophied ethmoid sinuses in 3 (3.3%) cases.(table 2)

DISCUSSION

Surgery for sinonasal illness has changed throughout the years as a result of this evolution. Long hospital stays and extensive exterior techniques have been replaced with a less invasive technique known as endoscopic sinus surgery (ESS). This procedure entails opening the clogged ostia in order to restore normal airflow while preserving the neighbouring mucosa and removing the diseased tissue. ESS has been shown in the literature to provide great outcomes. Due to the closeness of PNS to key structures including the orbit and the skull base, problems in surgery are frequently hazardous and detrimental. [13,14]

The anatomy of the sinonasal area is quite variable. Although their involvement in the development of sinusitis is yet unknown, thorough awareness of these variances is critical before the surgical surgery to prevent severe consequences. [14]

In this study 90 sinus patients were presented. Among 90 cases, majority of the patients were males 63 (70%) and 27 (30%) were females with mean age 33.41±8.56 years and had mean BMI 23.22 ±5.31 kg/m². These were comparable to the previous researches.[15,16] It is no longer necessary to resort to invasive surgery or lengthy stays in the hospital thanks to a new minimally invasive method known as FESS. FESS has been hailed in the literature as a success, despite this. Due to its closeness to essential organs and anatomical variations, however, the sinonasal area is particularly prone to surgical damage Researchers assume that sinus mucosal illness is caused by anatomical variances, however the findings in this respect are disputed. There was no link between anatomic variations and sinusitis in a research that found DNS (88.2 percent), CB (76.4 percent), agger-nasi cells (7 percent), haller cells (3.5 percent), and onodi cells (1.6 percent). [17] The surgical relevance of numerous sinonasal anatomic variations such as DNS (26%), CB (18.2%), haller cells (9.1%), and onodi cells (7.8%) was stressed by Adeel et al. in their study of the sinonasal area. [7] As Usman et al. reported, variants such as DNS (31 percent), CB (18.9 percent), UP variations (12 percent), agger-nasi cells (6.8 percent), septal spur (4 percent), and haller cells (3.7 percent) were found in a significant number of patients. [18]

In current study, we found that most of the patients 65 (72.2%) had deviated nasal septum (DNS) followed by agger nassi cells in 61 (67.8%) cases, concha bullosa in 35 (38.9%) cases, haller cells in 21 (23.3%), septated maxillary sinus in 19 (22.2%) cases, onodi cells in 16 (17.8%) and hypertrophied ethmoid sinuses in 3 (3.3%) cases. Also, in one study[19], the frequency of DNS (59.5 percent), CB (67.5 percent), and Agger-Nasi cells was shown to be significantly associated with uncinata and ethmoid bullas, as well as sinus-mucosal infection (74.8 percent). [20] Agger-nasi cells were shown to have a substantial connection with DNS (20.0 percent), CB (11.7 percent), as well as the turbinate forms of rhinosinusitis (78.3 percent). Both Madani and Suri had shown a substantial correlation between anatomical variations and rhinosinusitis, and these findings were consistent. Since the sinonasal area is best assessed with computed tomography (CT), this imaging technique has a significant influence on sinus infections. [21,22]

Anatomical differences exist between the nasal cavity and the PNS. Many variables, including age, race, gender, location, and ethnicity influence these structural variances, but only a handful have been linked to the aetiology of inflammatory sinus-mucosal disorders. To reduce intraoperative and postoperative problems after FESS and skull-base surgery, a thorough knowledge of the sinonasal anatomic variations is critical.

Anatomical changes in the sinus area may be evaluated with CT-PNS, which offers a road map for ENT surgeons.[23,24]

CONCLUSION

We concluded in this study that the prevalence of anatomical variants among patients of paranasal sinus was higher in which the majority of the patients had deviated nasal septum and agger nasi cells. There are several anatomical variations that may be seen in PNS. To ensure the best possible outcome for the patient and minimise the risk of significant consequences, each case must be reviewed in depth before surgery.

REFERENCES

- 1 Zinreich SJ. Rhinosinusitis: radiologic diagnosis. *Otolaryngol Head Neck Surg* 1997; 117: S27-34.
- 2 Ludwick JJ, Taber KH, Manolidis S, Sarna A, Hayman LA. A computed tomographic guide to endoscopic sinus surgery: axial and coronal views. *J Comput Assist Tomogr* 2002; 26: 317-22.
- 3 Jones NS. CT of the paranasal sinuses: a review of the correlation with clinical, surgical and histopathological findings. *Clin Otolaryngol Allied Sci* 2002; 27: 11-7.
- 4 Badia L, Lund VJ, Wei W, Ho WK. Ethnic variation in sinonasal anatomy on CT-scanning. *Rhinology* 2005; 43: 210-4
- 5 Hadi HH, Al-Bayati HA, Al-Gazali SS. Prevalence of normal anatomical variations in the region of paranasal sinuses in patients with chronic rhinosinusitis. *Med J Babylon*. 2018;15(3):243–250.
- 6 Shpilberg KA, Daniel SC, Doshi AH, Lawson W, Som PM. CT of anatomic variants of the paranasal sinuses and nasal cavity: poor correlation with radiologically significant rhinosinusitis but importance in surgical planning. *Am J Roentgenol*. 2015;204(6):1255–1260.
- 7 Adeel M, Rajput MS, Akhter S, Ikram M, Arain A, Khattak YJ. Anatomical variations of nose and para-nasal sinuses; CT scan review. *J Pak Med Assoc*. 2013;63(3):317–319.
- 8 Roman RA, Hedesiu M, Gersak M, Fidan F, Baciut G, Baciut M. Assessing the prevalence of paranasal sinuses anatomical variants in patients with sinusitis using cone beam computer tomography. *Clujul Med*. 2016;89(3):423–429.
- 9 Elsayed NM, Abdalaal LF. The Relation between Anatomical Variations of Osteomeatal Complex & Nasal Structures and Chronic Sinusitis by Computed Tomography. *Int J Med Imaging*. 2015;3(2):16–20.
- 10 Farhan N, Naqvi SU, Rasheed B, Sattar A, Khan M, Rahim A, Murtaza G. Identification of Significant Anatomical Variations in the Nose and Anterior Skull Base Using Computed Tomography: A Cross-Sectional Study. *Cureus*. 2020;12(6):e8449.
- 11 Qureshi N, Nosheen A. Functional Endoscopic Sinus Surgery (FESS) J Rawalpindi Med Coll. 2017;21(1):78–81.
- 12 Gohar MS, Niazi SA, Niazi SB. Functional Endoscopic Sinus Surgery as a primary modality of treatment for primary and recurrent nasal polyposis. *Pak J Med Sci*. 2017;33(2):380–382.
- 13 Mamatha H, Shamasundar NM, Bharathi M, Prasanna L. Variations of ostiomeatal complex and its applied anatomy: a CT scan study. *Indian J Sci Technol* 2010; 3: 904-7
- 14 Adeel, M., Rajput, M. S., Akhter, S., Ikram, M., Arain, A., Khattak, Y. J. (2013). Anatomical variations of nose and para-nasal sinuses; CT scan review. *Journal of the Pakistan Medical Association*, 63(3), 317-319
- 15 Qureshi MF, Usmani A. A CT-Scan review of anatomical variants of sinonasal region and its correlation with symptoms of sinusitis (nasal obstruction, facial pain and rhinorrhea). *Pak J Med Sci*. 2021;37(1):195-200.
- 16 Shpilberg KA, Daniel SC, Doshi AH, Lawson W, Som PM. CT of Anatomic Variants of the Paranasal Sinuses and Nasal Cavity: Poor Correlation With Radiologically Significant Rhinosinusitis but Importance in Surgical Planning. *AJR Am J Roentgenol*. 2015 Jun;204(6):1255-60.
- 17 Tiwari R, Goyal R. Study of anatomical variations on CT in chronic sinusitis. *Indian J Otolaryngol Head Neck Surg*. 2015;67(1):18–20.
- 18 Usman R, Hassan NH, Hamid K, Soban M, Darira J, Saifullah Role of CT- Scan in Assessment of Anatomical Variants of Nasal Cavity and Paranasal Sinuses. *J Bahria Uni Med Dent Coll*. 2016;6(4):219–222
- 19 Dasar U, Gokce E. Evaluation of variations in sinonasal region with computed tomography. *World J Radiol*. 2016;8(1):98–108.
- 20 Espinosa W, Genito R, Ramos RZ. Anatomic variations of the nasal cavity and paranasal sinus and their correlation with chronic rhinosinusitis using Harvard staging system. *J Otolaryngol ENT Res*. 2018;10(4):190–193
- 21 Madani SA, Hashemi SA, Modanloo M. The incidence of nasal septal deviation and its relation with chronic rhinosinusitis in patients undergoing functional endoscopic sinus surgery. *J Pak Med Assoc*. 2015;65(6):612–614
- 22 Suri N, Janardan T, Parmar H. Correlation of anatomical variations of Paranasal sinuses and Chronic Rhinosinusitis. *Int Arch Integrated Med*. 2016;3(12):84–88
- 23 Qureshi MF, Usmani A. Clinically Significant Variation of Paranasal Sinuses on CT-Scan. *J Bahria Uni Med Dent Coll*. 2020;10(2):152–157
- 24 Alsowey AM, Abdulmonaem G, Elsammak A, Fouad Y. Diagnostic performance of multidetector computed tomography (MDCT) in diagnosis of sinus variations. *Pol J Radiol*. 2017;82:713–725