

Role of Diagnostic Laparoscopy in Identifying the cause of Chronic Abdominal Pain

SHAHID HUSSAIN MIRANI¹, DHARMOON ARIJA², MUHAMMAD NAEEM³, ABDUL RASHEED ZAI⁴, MUHAMMAD RAFIQUE PATHAN⁵, MUHAMMAD ANWAR MEMON⁶

^{1,2}Department of Surgery, Ghulam Muhammad Mahar Medical College Sukkur. ³Surgical Unit-1, Department of General Surgery & Surgical Oncology, Shaikh Zayed Hospital, Postgraduate Medical Institute, Lahore. ^{4,5}Department of Surgery, Indus Medical College, Tando Muhammad Khan. ⁶Department of General Surgery, Liaquat University of Medical & Health Sciences

Correspondence to: Dr. Shahid Hussain Mirani, Cell: 0300-8317731 E-mail: srgmirani@gmail.com

ABSTRACT

Background: Chronic abdominal pain is a prevalent and challenging medical condition characterized by persistent pain in the abdomen lasting for more than three months. The pain can be due to a variety of gastrointestinal and extra-gastrointestinal causes, and it often requires a multidisciplinary approach for diagnosis and management. Common causes include irritable bowel syndrome, inflammatory bowel disease, chronic pancreatitis, and adhesions, among others.

Objective: To determine the role of diagnostic laparoscopy in identifying the cause of chronic abdominal pain.

Methodology: This observational study was conducted at Department of Surgery, Ghulam Muhammad Mahar Medical College Sukkur in tertiary-care hospital from 1st January 2022 to 31st December 2023. A total of 80 patients having age of ≥ 20 years were included. Patients who were suffering from abdominal pain for more than 6 months and having non-conclusive diagnosis were included.

Results: Males were comparatively more in number as compared to females. Appendicitis was the main examination outcomes after laparoscopic evaluation followed by bands of adhesion. In 88% of the patients, total relief in pain was observed.

Conclusion: Laparoscopy proves a definitive diagnosis in chronic abdominal pain patients and thus helps in therapeutic intervention.

Keywords: Abdominal pain, Laparoscopy, Irritable bowel syndrome, Inflammatory bowel disease, Diagnostic method.

INTRODUCTION

Chronic abdominal pain refers to persistent or recurrent pain or discomfort in the abdomen that lasts for an extended period, typically defined as at least three months. Unlike acute abdominal pain, which often indicates a sudden and severe medical issue requiring immediate attention, chronic abdominal pain persists over time and may have a less clear-cut cause. Chronic abdominal pain can vary widely in intensity, duration, and location, and it may be accompanied by other symptoms such as bloating, nausea, vomiting, changes in bowel habits, or weight loss¹⁻⁴.

The causes of chronic abdominal pain can be numerous and may include gastrointestinal disorders like irritable bowel syndrome (IBS), inflammatory bowel disease (IBD), gastritis, or peptic ulcer disease. Other potential causes may involve conditions affecting organs in the abdomen such as the pancreas, liver, kidneys, or reproductive organs. Due to the diverse range of potential causes, diagnosing chronic abdominal pain can be challenging and may require a comprehensive evaluation by a healthcare provider. Treatment approaches often depend on identifying and addressing the underlying cause, which may involve lifestyle changes, medications, dietary modifications, or in some cases, surgical intervention⁵⁻⁷.

Diagnostic laparoscopy, also known as exploratory laparoscopy, is a minimally invasive surgical procedure used to visually inspect the organs inside the abdomen and pelvis. It involves making small incisions in the abdomen through which a thin, flexible tube with a camera (laparoscope) is inserted. This allows the surgeon to view the abdominal organs on a monitor in real-time. The role of diagnostic laparoscopy in identifying the cause of chronic abdominal pain can be significant, especially when other diagnostic methods, such as imaging studies or laboratory tests, have been inconclusive⁸⁻¹⁰. Present study aimed to find the role of diagnostic laparoscopy in identifying the cause of chronic abdominal pain. Result of the study will prove beneficial in early diagnosis of abdominal pain which would prove vital for quality of life of the patient.

MATERIALS AND METHODS

This observational study was conducted at Department of Surgery,

Received on 12-12-2023

Accepted on 26-01-2024

Ghulam Muhammad Mahar Medical College Sukkur in tertiary-care hospital from 1st January 2022 to 31st December 2023. This study was approved by ethical review board of the hospital. Patients who were suffering from abdominal pain for more than 6 months and having non-conclusive diagnosis were included in present study. Patients who had cardiovascular disease, acute abdominal pain, abdominal malignancy, H-pylori, sepsis and on any type of anti-psychotic drugs were excluded from the present study. Patients were informed about the study objectives and written informed consents were taken from study participants. A total of 80 patients having age of ≥ 20 years were included. Sample size was determined on WHO sample size calculator by using 80% power of test and 95% CI. Patients were operated under general anesthesia and were in supine position. A Veress needle was used in abdominal area where no previous scarring or suspicion of the massive intra-abdominal adhesions was observed. Upper-quadrant of left-side was mostly opted. Pneumo-peritoneum, prior creation of a 3-trocar technique which is a standardized method was applied and through umbilical a 2 lateral-trocars of 5mm were made. Complete investigation of abdominal cavity from liver to gall bladder to anterior surface of stomach and spleen was made. Smooth-conditioned graspers were used for detailed examination of each structure. Furthermore, an atraumatic-grasper was also employed for small-bowel examination starting from Treitz ligaments up to ileocecal-valve. Similar technique was employed for the investigation of appendix and colon. Douglas pouch and uterus was also examined in women for recording fluid consistency. Specimens were also collected for histopathological analysis. Patients who underwent another surgery who required further surgery post diagnosis. Data was analyzed using SPSS version 26.0.

RESULTS

Mean age of the participants was 37 ± 14.8 and majority of the patients were in 35-65 years of age group. Males were comparatively more in number as compared to females (Table 1). In 88% of the patients, total relief in pain was observed whereas 6% of the patients recorded reduced and persistent pain as well (Fig. 1).

Around 46% of the patient's pain site was right lower quadrant while 22.5% of the patients had pain in left lower quadrant. There were 13.7% of the patients who had pain in pre-

umbilical cord site. Moreover, appendicitis is the main examination outcomes after laparoscopic evaluation followed by bands of adhesion (Table 2).

Table 1: Age, gender and duration of study participants

Variables	No.	%
Age (Years)		
20-34	24	30.0
35-65	42	52.5
>65	14	17.5
Gender		
Male	46	57.5
Female	38	47.5
Pain duration	8±1.3	

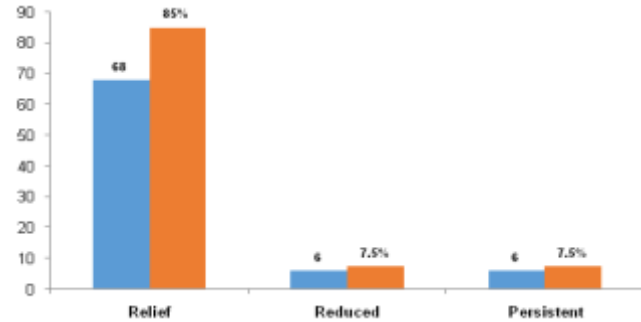


Fig 1: Pain response of patients after laparoscopic procedure

Table 2: Pain sites and laparoscopic examination of patients with chronic abdominal pain

Variables	No.	%
Pain site		
Left lower quadrant	18	22.5
Left upper quadrant	9	11.2
Right lower quadrant	37	46.2
Right upper quadrant	3	3.7
Diffuse	2	2.5
Pre-umbilical	11	13.7
Laparoscopic examination outcomes		
Appendicitis	47	58.7
Bands of adhesion	12	15.0
Peritoneal omental deposits	8	10.0
Koch's abdomen	7	8.7
Inconclusive	6	7.5

DISCUSSION

Laparoscopy provides a direct and magnified view of the abdominal organs, allowing the surgeon to visually inspect for abnormalities such as adhesions, scar tissue, tumors, or inflammation that may not be detected by other imaging modalities. It's essential to recognize that laparoscopy is a surgical procedure with potential risks and complications, albeit less invasive than traditional open surgery. Therefore, it is typically reserved for cases where non-invasive diagnostic methods have been inconclusive, and the potential benefits of obtaining direct visualization and tissue samples outweigh the risks associated with the procedure¹¹⁻¹³. In this study, importance of laparoscopic procedure tried to be highlighted for proper diseases evaluation and better diagnosis.

In the present study, mean age of the study participants was 37±14.8 years and majority of the patients were in 35-55 years of age group. Duration of the pain was noticed as 8±1.3 months. Findings of the present study was inconsistent with already published data¹⁴⁻¹⁶. Result of the present study revealed, appendicitis is the main cause of chronic pain in majority of the

patients followed by bands of adhesion. Causes of pain and their incidence rate was also similar with other findings^{17,18}. In few patients, exact cause of the pain was not fully determined even after laparoscopy. A study conducted by Ahmed et al.¹⁸ also indicated ~15% of the patients with no exact diagnosis even after laparoscopic procedure. Another study performed by Lingala et al.¹⁹ observed the similar findings.

Overall, laparoscopy is a safe surgical method for investigating chronic abdominal pain. It not only determines the cause of pain but also prove advantageous in therapeutic intervention which can be performed at the same time thus avoid further surgical invasion and hospitalization. Furthermore, it is generally regarded as safe and minimally invasive protocol and execute reliable results¹⁹⁻²². Result of the present study also suggests, it could be an effective protocol for evaluating the exact of abdominal pain.

CONCLUSION

Laparoscopy proves a definitive diagnosis in chronic abdominal pain' patients and thus helps in therapeutic intervention. It can also employed as a therapeutic procedure with minimal chances of morbidity.

REFERENCES

- Mendelson R. Imaging for chronic abdominal pain in adults. *Aust Prescr*. 2015;38(2):49-54.
- Parthasarathy A. Partha's fundamentals of pediatrics. JP Medical Ltd; 2013.
- Naniwadekar RG, Kabra MV, et al. Role of diagnostic laparoscopy in chronic abdominal pain. *J Evol Med Dent Sci* 2016;5(17): 859-63.
- Tulaskar N, Nichkaode P, et al. Evaluation of role of laparoscopy in chronic abdominal pain. *Int J Biol Med Res* 2013;4(2):3230-33.
- Kumar A, Sarwar MY, et al. Role of diagnostic laparoscopy in nonspecific chronic abdominal pain: experience of 100 cases. *J Evol Med Dent Sci* 2013;48(2):9361-6.
- Gallili O, Shaoul R, et al. Treatment of chronic recurrent abdominal pain: laparoscopy or hypnosis? *J Laparoendosc Adv Surg Tech A* 2009;19(1):93-6.
- Husain M, Sachan PK, et al. Role of diagnostic laparoscopy in chronic and recurrent abdominal pain. *Trop Gastroenterol* 2014;34(3):170-73.
- Rubbia A, Faryal GA, et al. Role of diagnostic laparoscopy in patients with acute or chronic nonspecific abdominal pain. *World J Laparosc Surg* 2015;8:7-12.
- Saxena P. The role of laparoscopy in diagnosis of patients with chronic abdominal pain. *Int Surg J* 2016;4(1):326-33.
- Rao TU. Role of diagnostic laparoscopy in chronic abdominal conditions with uncertain diagnosis. *Int Surg J* 2016;4(1):15-8.
- Nar AS, Bawa A, et al. Role of diagnostic laparoscopy in chronic abdominal conditions with uncertain diagnosis. *Niger J Surg* 2014;20(2):75-8.
- Chaphekar A, Vankipuram S, et al. Does Laparoscopy Have a role in Chronic Abdominal Pain? *Int J Contemp Med Res* 2016;3: 2582-5.
- Vijay K, Mohan A. Laparoscopy as a diagnostic tool in chronic abdominal pain. *MedPulse Int Med J* 2017;4:249-53.
- Penner RM, Fishman MB, et al. Evaluation of the adult with abdominal pain. *UpToDate*; 2016.
- Macaluso CR, McNamara RM. Evaluation and management of acute abdominal pain in the emergency department. *Int J Gen Med* 2012;5:789.
- Alam MS, Rahman MM, et al. Role of diagnostic laparoscopy in unexplained chronic abdominal pain. *J Armed Forces Med College* 2015;10:9-14.
- Makama JG, Kache SA, Ajah LJ, Ameh EA. Intestinal obstruction caused by appendicitis: a systematic review. *J West Afr Coll Surg* 2017;7(3):94-115.
- Ahmad MM, Dar HM, Waseem M. Role of laparoscopy in nonspecific abdominal pain. *Saudi Surg J* 2014;2:71-4.
- Lingala R. A study of diagnostic laparoscopy in chronic abdominal pain. *J Evid Based Med Healthcare* 2018;5(28):2113-7.
- Sayed ZK, Verma RA, et al. Role of diagnostic laparoscopy in chronic abdominal pain. *Int J Sci Stud* 2015;3:31-5.
- Buia A, Stockhausen F, Hanisch E. Laparoscopic surgery: A qualified systematic review. *World J Methodol* 2015;5(4):238-54.
- Zhao J, Samaan JS, Toubat O, Samakar K. Laparoscopy as a diagnostic and therapeutic modality for chronic abdominal pain of unknown etiology: a literature review. *J Surg Res* 2020;252:222-30.

This article may be cited as: Mirani SH, Arija D, Naeem M, Zai AR, Pathan MR, Memon MA: Role of Diagnostic Laparoscopy in Identifying the cause of Chronic Abdominal Pain. *Pak J Med Health Sci*, 2024; 18(1): 85-86.