

## CASE REPORT

# Anterior Cruciate Ligament Tear Treated with Arthroscopic Primary Repair - A Case Report and Literature Review

ARMUGHAN AHMAR<sup>1</sup>, ADNAN QAMAR<sup>2</sup>, SAAD SULTAN RANA<sup>3</sup>, MIAN ABDULLAH ANWAR<sup>4</sup>, REHAN RAZA SHAN<sup>5</sup>, MUHAMMAD HAIDER ALI<sup>6</sup>

<sup>1,3,4,5</sup>Trainee Resident

<sup>2</sup>Assistant Professor

<sup>6</sup>House Officer

Department of Orthopaedic Surgery, Shaikh Zayed Hospital, Lahore

Correspondence to Dr. Armughan Ahmar, Email: [armughanhk@gmail.com](mailto:armughanhk@gmail.com); Cell: 03124210100

## INTRODUCTION

Anterior cruciate ligament (ACL) tear is one of the most common injuries encountered in Orthopaedics worldwide<sup>1</sup>. ACL is a vital ligament attached on the medial wall of the lateral femoral condyle, the lateral intercondylar ridge marking its anterior border, proximally. Distally, it attaches between the intercondylar eminences on the anterior tibia. It consists of two bundles, anteromedial and posterolateral. Primarily, it prevents the anterior translation of the tibia on the femur<sup>2</sup>. In the extended knee, the posterolateral bundle is tight and the anteromedial bundle is lax. As the knee is flexed, the anteromedial bundle tightens and the posterolateral bundle relaxes. The anteromedial bundle is the primary restraint against anterior tibial translation while the posterolateral bundle stabilizes the knee in full extension especially against rotatory loads. The nerve supply to the ACL originates from the tibial nerve serving as vasomotor, sensory and proprioceptive functions. The blood supply to the ACL originates from branches of the middle genicular artery which form a network around the ligament.

Besides sports being the leading cause of injury, trauma is also a common cause in Pakistan<sup>3</sup>. The recognized possible causes of an ACL injury include abruptly changing directions while jogging or running, landing awkwardly on an extended knee after a jump or contact trauma to the knee<sup>4</sup>. The consequences of this injury include acute pain and swelling, instability of the knee joint, and difficulties in daily activities of the patient. The gold standard treatment these days is reconstruction of ACL arthroscopically with tendon autograft<sup>1,5,6</sup>. With these typical complaints, a patient presented to us in the outpatient clinic.

## CASE PRESENTATION

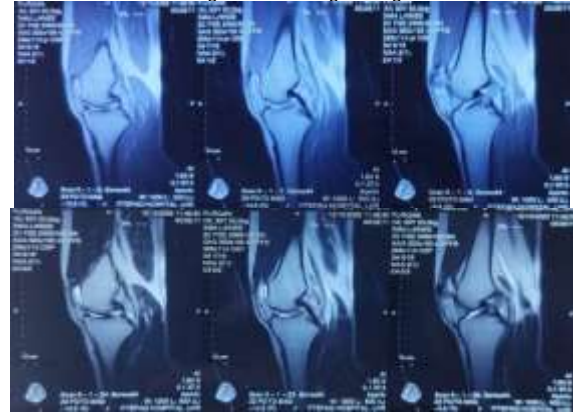
A 35 years old, Pakistani male with an office job, previously healthy, consulted our outpatient department complaining of painful left knee and inability to fully bear weight on this leg since the past two weeks. He reported to have had a road traffic accident while riding a bike and sustaining a direct blow to his left knee and subsequently unable to fully bear weight on this leg. He was on oral pain medications and was using walking aids at the time. The left knee was tender with no swelling, range of motion was painful at the knee joint hence a local anesthetic agent was infiltrated in the knee joint for proper examination. Lachman and anterior drawer tests were positive with no endpoint. McMurray test for medial meniscus was also positive. Rest of the examination was unremarkable. X-ray of the injured left knee showed no fracture. Magnetic resonance imaging (MRI) showed a partial thickness tear of the ACL and intrasubstance changes in the posterior horn of medial meniscus.

Patient was admitted, informed consent was taken and pre-operative optimization was done. Patient was taken to the operation theater on the next elective list with a plan of arthroscopic repair with a backup of arthroscopic reconstruction for ACL and repair of the medial meniscus. Patient was given spinal anesthesia and was prepared and draped in supine position with the knee flexed till 90 degrees. Intravenous antibiotic was given before applying esmarch and inflation of tourniquet.

Received on 07-07-2023

Accepted on 17-11-2023

Fig. 1A & 1B: T1 and T2 weighted MRI images. Sagittal view of the left knee.



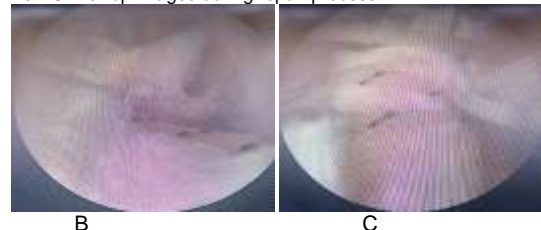Diagnostic arthroscopy was performed, lateral port was created for introduction of the telescope in the knee joint, and irrigation pump was used throughout the procedure. Medial port was created under vision. On inspection of the joint cavity, medial meniscus seemed to be intact, lateral meniscus and posterior cruciate ligament (PCL) were also intact. ACL rupture from the femoral attachment was identified. Plan of repair was initiated. The femoral attachment site of the ACL was shaved and freshened up for tunnel placement. Subsequently, in a hyper flexed knee (over 100 degrees), anteromedial drilling at 2 'O'clock position in the coronal plane was carried out, followed by shallow reaming for only a few millimeters.

After identifying the two bundles (anteromedial and posterolateral), a fiber suture was passed through the substance of each bundle separately near the ruptured end. Then loaded on a 5.0mm suture anchor (Peek + TiT) and tightened in the femoral tunnel. The free ends of the fiber sutures were passed through a free endobutton and placed on the proximal tibia for internal bracing of the construct.

Fig. 2A: Doratek 5.0mm suture anchor (Peek + TiT).

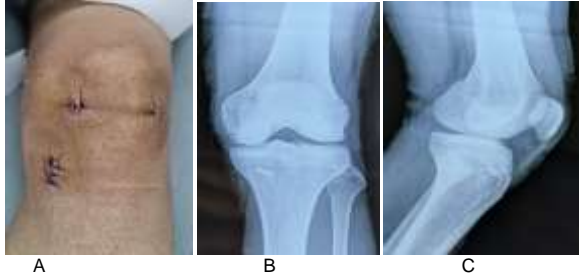

Fig. 2B & 2C: Per-op images during repair process.



Knee joint cavity was thoroughly washed and drained, ports were closed with Polypropylene sutures. Antiseptic dressing done and knee immobilizer was given.

Figure 3 **A:** Post-op wounds. **B:** Post-op X-ray AP view. **C:** Post-op X-ray Lateral view.



In the immediate postoperative period, immobilization of the knee joint, icing and elevation was continued. Physiotherapy of the knee joint was started on day one postoperatively with isometric knee contraction and complete extension of the knee. Patient was discharged after 4 days and physiotherapy/rehabilitation continued as planned for the next 6 months with frequent follow-ups in the outpatient department.

The patient's rehab has come along quite well. The knee is stable with full range of motion, he is able to walk, climb and descend stairs and perform his daily activities with ease.

**DISCUSSION**

Historically, open repair of the ligament was done frequently in the 1970's and 1980's but it was abandoned subsequently due to high failure rates<sup>7,9</sup>. Recently, interest in the repair technique is again on the rise due to better understanding of the pathophysiology, healing capabilities, selection criteria for appropriate surgical candidates, modern surgical equipment and minimally-invasive surgical techniques<sup>8,9</sup>.

The location of the tear also has a bearing on the procedure choice being repair or reconstruction and the technique to be used. Sherman et al. suggested that proximal tears (Type 1) have better healing capabilities than distal ones and hence good outcomes<sup>10</sup>. In this case, the tear was indeed proximal, as it was ruptured from the femoral end, the ligament was in good condition due to recent injury and hence repair of the ligament was chosen.

In the postoperative period and subsequently, regular physiotherapy was being carried out according to set protocols. In the 6 month follow-up, patient has already returned to his pre-injury daily activities and work with no active complaints. On the 6 month follow-up, The Lysholm Knee Score was 95. As DiFelice et al reported, primary repair does show good results in the medium term follow up with only one re-rupture encountered in their case series<sup>11,12</sup>.

Consequently, this resurgence in enthusiasm for repair in the acute setting has resulted in several arthroscopic repair techniques being reported. The advantages and disadvantages of primary ACL repair enlisted in Table 1 are also attractive for favorable outcomes.

**CONCLUSION**

ACL rupture, being one of the most common injuries in Orthopedics, should be dealt with standard interventions approved worldwide. As reconstruction of the ACL is the gold standard in this day and age, more work needs to be done to preserve the native ACL where possible, as is being identified by the specific selection criteria tabulated for repair of the ligament, as it has many advantages. The re-rupture rates, reported as high as 15% need to be addressed with careful selection, standard repairing techniques which have been tested, and appropriate rehabilitation. This is the first case report on primary repair of an acutely injured proximal

ACL in Shaikh Zayed Hospital, Lahore, with a good outcome, excellent knee range of motion and stability, and patient satisfaction. With the advancement of medical facilities and better understanding, a subset of ACL injuries can have primary repair as the gold standard treatment in the future, provided work is done to standardize the selection criteria and techniques used.

Table 1: The advantages and disadvantages of primary ACL repair are also attractive for favorable outcomes

| Advantages  | Disadvantages  |
|---|--|
| Maintenance of cellular density                               | Potential for failure  |
| Knee proprioception and kinematics                            | Lack of high level of evidence and long term follow up in literature |
| Avoids donor site morbidity                                   |  |
| Faster healing  |  |
| No difficulty in subsequent reconstruction in case of failure |  |

**Authorship and contribution declaration:** Each author of this article fulfilled following Criteria of Authorship:

1. Conception and design of or acquisition of data or analysis and interpretation of data.
2. Drafting the manuscript or revising it critically for important intellectual content.
3. Final approval of the version for publication.

All authors agree to be responsible for all aspects of their research work.

**Conflict of interest:** None

**Funding:** None

**REFERENCES**

1. Kan SL, Yuan ZF, Ning GZ, Yang B, Li HL, Sun JC, Feng SQ. Autograft versus allograft in anterior cruciate ligament reconstruction: a meta-analysis with trial sequential analysis. *Medicine*. 2016;95(38).
2. Kittl C, El-Daou H, Athwal KK, Gupte CM, Weiler A, Williams A, Amis AA. The role of the anterolateral structures and the ACL in controlling laxity of the intact and ACL-deficient knee. *The Am JSports Medicine*. 2016;44(2):345-54.
3. Shah F, Riaz MU, Hassan D, Abbas Z. Factors contributing anterior cruciate ligament injury and pattern of presentations.
4. Dar AJ, John A, Ashraf S, Faridi TA, Zahid S, Nazir AB. MRI Diagnosis and Grading of Anterior Cruciate Ligament Injuries. *Pakistan BioMedical J*. 2022;31:341-5.
5. Murray MM. Optimizing outcomes of ACL surgery—Is autograft reconstruction the only reasonable option?. *Journal of Orthopaedic Research*. 2021;39(9):1843-50.
6. Hirzinger C, Tauber M, Korntner S, Quirchmayr M, Bauer HC, Traweger A, Tempfer H. ACL injuries and stem cell therapy. *Archives of orthopaedic and trauma surgery*. 2014;134:1573-8.
7. Mahapatra P, Horriat S, Anand BS. Anterior cruciate ligament repair—past, present and future. *J experimental orthopaedics*. 2018;5(1):1-0.
8. Heusdens CH. ACL repair: a game changer or will history repeat itself? A critical appraisal. *J Clinical Medicine*. 2021;26;10(5):912.
9. Kandhari V, Vieira TD, Ouanezar H, Praz C, Rosenstiel N, Pioger C, Franck F, Saithna A, Sonnery-Cottet B. Clinical outcomes of arthroscopic primary anterior cruciate ligament repair: a systematic review from the scientific anterior cruciate ligament network international study group. *Arthroscopy: J Arthroscopic & Related Surgery*. 2020;1;36(2):594-612.
10. Sherman MF, Lieber L, Bonamo JR, Podesta L, Reiter I. The long-term follow up of primary anterior cruciate ligament repair: defining a rationale for augmentation. *The Am JSports Medicine*. 1991;19(3):243-55.
11. DiFelice GS, Villegas C, Taylor S. Anterior cruciate ligament preservation: early results of a novel arthroscopic technique for suture anchor primary anterior cruciate ligament repair. *Arthroscopy: J Arthroscopic & Related Surgery*. 2015;1;31(11):2162-71.
12. Achtnich A, Herbst E, Forkel P, Metzloff S, Sprenger F, Imhoff AB, Petersen W. Acute proximal anterior cruciate ligament tears: outcomes after arthroscopic suture anchor repair versus anatomic single-bundle reconstruction. *Arthroscopy: J Arthroscopic & Related Surgery*. 2016;32(12):2562-9.

**This article may be cited:** Ahmar A, Qamar A, Rana SS, Anwar MA, Shan RR, Ali MH: Anterior Cruciate Ligament Tear Treated With Arthroscopic Primary Repair - A Case Report And Literature Review. *Pak J Med Health Si*, 2023; 17(12):79-80.