

Evaluation of Percutaneous Peritoneal Drainage Among Patients with High Risk Perforated Peritonitis in Tertiary Care Hospital

SHAHID NAWAZ¹, SARAH REHMAN², RAZA HASSAN³, SANULLAH PATHAN⁴, MUBARAK HUSSAIN⁵, NASEER HASSAN⁶

¹Associate professor and HOD, Department of Neurosurgery, Gomal Medical College DI Khan.

²Demonstrator Department of Community Medicine, Gomal Medical College DI Khan.

³Assistant Professor, Department of Orthopaedics, Northwest General Hospital and Research Centre.

^{4,5}Assistant professor of Neurosurgery, Liaquat university of medical and health sciences, Jamshoro.

⁶Associate Professor/Chairman, Department of Neurosurgery and Neurotrauma, Qazi Hussain Ahmad Medical Complex/ Nowshera Medical College.

Corresponding author: Naseer Hassan, Email: dnaseerhassan@gmail.com

ABSTRACT

Objective: This study aimed to share our experience in treating various types of injection-induced peripheral nerve injuries and explore numerous problems that are related to this category of peripheral nerve injuries.

Study Design: Retrospective study

Place and Duration: Department of Neurosurgery, Gomal Medical College DI Khan in the duration from October, 2022 to March, 2023.

Methods: Total 130 patients of both gender with age 8-70 years were included. Patients with post-operative peripheral nerve injuries were following intramuscular injections, brachial nerves block procedures, subclavian and jugular venous cannulation procedures for central line placements, and routine intravenous injections in the peripheral veins of the limbs. Frequency of peripheral nerve injuries and its management among all cases were assessed. SPSS 22.0 was used to analyze all data.

Results: In all 130 patients, 82 (63.1%) cases were males and 48 (36.9%) patients were females. 45 (34.6%) patients had age 8-15 years, 30 (23.1%) cases had age 16-25 years, 33 (25.4%) cases had age 26-35 years and 22 (16.9%) patients had age >35 years. Mean duration of peripheral nerve injury was 2.4±7.38 months. Most common reason was intramuscular injection found in 104 (80%) cases. Most common affected nerve was sciatic nerve in the gluteal region, the radial nerve in the arm and axillary nerve in the shoulder region. Non-functional status among all cases were found in 58 (44.6%) cases. Six (4.6%) of the patients in our series experienced neurological impairment following surgery in the form of motor weakness. The best outcomes, 115 (88.5%), were reported with the repair of the radial nerve after surgery.

Conclusion: We came to the conclusion that a quick referral to a specialized peripheral nerve center, an early intervention, and early diagnosis are just a few crucial elements that can lead to a positive outcome and reduce the frequency of medicolegal lawsuits. By having in-depth anatomical understanding and providing patients with adequate counseling before to the treatment, the problem can be avoided in the vast majority of cases.

Keywords: Peripheral nerve injury, Surgery, Improvement, Injection

INTRODUCTION

When a nerve is stretched, compressed, hypoperfused, directly injured, exposed to neurotoxic substance, or any combination of these during the perioperative period, peripheral nerve injury may result.[1,2]

Nerve damage frequently lacks a definite origin [3,4]. The physical rupture of the vasa nervorum, intraneural hemorrhage, and/or endoneural oedema are frequently the common pathophysiological precipitants of these injuries, which result in ischaemia and nerve hypoperfusion[5]. These cause a variety of histological abnormalities in the brain, including poor axoplasmic transportation, axonal degeneration, Schwann cell damage, myelin loss, segmental demyelination, and total Wallerian degeneration[7]. Nerve impulse transmission may be permanently disrupted or only temporarily so, depending on the depth and length of the ischemic insult. Although in an animal model of the compression harm, the degree of histological damage to nerves has been associated with the degree and duration of compression, the severity of the initial pathophysiological system, degree of nerve ischaemia, and subsequent clinical presentation are only loosely related.[8]

The following are the most frequent differential diagnoses to take into account when there is a suspicion of peripheral nerve injury during anesthesia: peripheral neuropathy caused by diabetes mellitus, alcohol, hypothyroidism or nutritional deficiency, myelopathy, radiculopathy, spinal cord trauma or infarction, and muscle disease. It is important to recognize the prevalence of pre-existing peripheral neuropathy, which affects between 2 and 8% of the general population[16] and rises to 26% and 58% of patients with type-2 diabetes mellitus, respectively.[9]

When an anesthetist suspects a peri-operative peripheral nerve injury, they should record a history of the symptoms, perform a systemic examination, and check the motor and sensory systems of all four limbs as well as the cranial nerves. The following blood tests should be requested: a complete blood count, renal function,

liver function, sedimentation of erythrocytes rate, blood glucose, vitamin B12, and thyroid stimulating hormone.[10]

A neurologist or neurophysiologist should be in charge of conducting more research into the potential causes of nerve injury. This could involve nerve biopsy, targeted serum and plasma analyses, nerve conduction investigations, electromyography, magnetic resonance imaging (MRI), and nerve imaging. Nerve conduction investigations and electromyography are frequently delayed until around 2 weeks after the alleged injury because during this time, neuronal degeneration might take up to 2 weeks to complete. As a result, these tests can yield deceptively comforting results. When a peripheral nerve injury caused by anesthesia is proven, further research should be done to look for underlying, but unidentified disease processes like diabetes mellitus.[11]

A peripheral nerve injury must be identified as soon as possible. A motor or mixed nerve's chances of making a significant recovery are increased with prompt and adequate treatments, which can also lessen the likelihood of neuropathic pain sensitivity. Diagnostic success depends on repeated, meticulous clinical examination. Orthopaedic surgeons must have technical expertise as well as in-depth understanding of musculoskeletal and neurovascular anatomy, the pathophysiology of nerve injury, and procedural training for a specific intervention[12].

The devastating injection-induced accidental peripheral nerve palsies result in considerable neurological impairment and severe mental distress. An estimated 50% or more of intramuscular injections are given in unlicensed or informal healthcare settings. Numerous procedures affecting the limbs have been carried out using the nerve block approach over the past ten years as an alternative to, as well as to avoid, general or spinal anesthesia. The installation of central lines in the subclavian or jugular veins has also significantly increased, in both the intensive

care unit (also known as the and during major surgical procedures.[13,14]

MATERIALS AND METHODS

This retrospective study was conducted at Department of Neurosurgery, Gomal Medical College DI Khan in the duration from October, 2022 to March, 2023 and comprised of 130 patients. After taking informed written consent detailed demographics of enrolled cases included age, sex, body mass index and complaint were recorded. Patients <8 years of age, severe medical illness and those did not provide any written consent were excluded.

Retrospective analyses of the presenting symptoms, neurological, electrophysiological, and radiological results were performed on all 130 surgically treated patients. The visual analog scale (VAS) was used to rate the severity of the neurogenic pain symptom, with 0 denoting no pain and 10 denoting excruciating, agonizing pain. The paresthesia was categorized as mild, moderate, or severe. The Medical Research Council (MRC) scale was used to rate the muscle power charting. All 130 patients underwent an electrophysiological examination (EMG-NCV) before surgery. Prior to surgical intervention, it was established in all patients that the preoperative recording of delay or block in conduction across the damaged nerve on the nerve conduction (NC) study and evidence of degeneration in the affected nerve on the electromyography, or EMG, study both existed. The damaged area was subjected to a magnetic resonance image (MRI) examination. A second MRI neurography was also completed on 21 patients.

Patients who experienced severe neurogenic pain and paresthesia after receiving injectable therapy and whose symptoms did not improve with medical care underwent surgery. Additionally, there was a noticeable disruption in these individuals' daily functioning. Patients with sensorimotor neurological abnormalities following injectable therapy who had not improved after three months of monitoring and conservative treatment were also given the option of surgery. Patients with post-injection palsy who needed surgery to repair damaged nerves were postponed for more than two years. The surgical alternatives included sural nerve cable grafting, removal of the neuroma/contused part of the nerve, and external neurolysis. All patients had surgery with required intraoperative nerve stimulation and monitoring of muscle activity.

With a mean of 22 months, the follow-up length in our series ranged from 6 months to 84 months. For two years following surgery, the follow-up regimen included a comprehensive clinical evaluation and periodic electrophysiological testing every six months. The neurogenic pain, paresthesia, and sensorimotor neurological impairments were evaluated and contrasted with the preoperative status and earlier clinic visits during the follow-up visits. The Medical Research Council (MRC) power grade 3 or higher functional motor recovery and improvement in the sensory complaints were used to evaluate the findings.

RESULTS

In all 130 patients, 82 (63.1%) cases were males and 48 (36.9%) patients were females. 45 (34.6%) patients had age 8-15 years, 30 (23.1%) cases had age 16-25 years, 33 (25.4%) cases had age 26-35 years and 22 (16.9%) patients had age >35 years. Mean duration of peripheral nerve injury was 2.4±7.38 months. Most common reason was intramuscular injection found in 104 (80%) cases.(table 1)

Table-1: Characteristics of the cases that have been enrolled

Variables	Frequency (n=130)	Percentage
Gender		
Male	82	63.1
Female	48	36.9
Age of patients		
8-15 years	45	34.6
16-25 years	30	23.1
26-35 years	33	25.4

>35 years	22	16.9
Injection type		
intramuscular injection	104	80
intravenous injection	26	20
Mean duration of injury (months)	2.4±7.38	

Most common affected nerve was sciatic nerve in the gluteal region, the radial nerve in the arm and axillary nerve in the shoulder region.(figure 1)

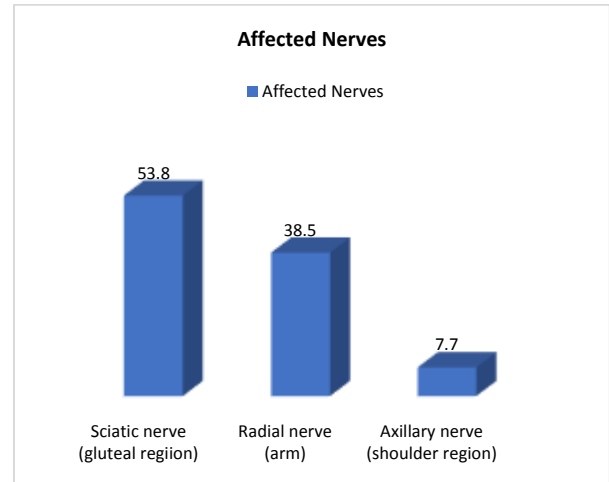


Figure-1: Affected nerves among all cases

Non-functional status among all cases were found in 58 (44.6%) cases. Six (4.6%) of the patients in our series experienced neurological impairment following surgery in the form of motor weakness.(table 2)

Table-2: Functional status and association of neurological impairment

Variables	Frequency	Percentage
Functional status		
Yes	72	55.4
No	58	44.6
Neurological impairment		
Yes	6	4.6
No	124	95.4

The best outcomes, 115 (88.5%), were reported with the repair of the radial nerve after surgery.(table 3)

Table-3: Outcomes of radial nerve impairment

Variables	Frequency	Percentage
Outcomes		
Good	115	88.5
Poor	15	11.5

Post-treatment mean pain score reduced to 1.4±7.16 and functional power grade 2 was noted among 62 (47.7%) cases.(table 4)

Table-4: Pain score and functional power among all cases

Variables	Pre-operative	Post-operative
Outcomes		
Mean pain score	7.6±12.52	1.4±7.16
Functional power grade		
0	24	8
1	70	40
2	36	62
2	0	20

DISCUSSION

Peripheral nerve damage brought on by injections is an iatrogenic issue. The earlier literature suggests a range in the overall

incidence of 1.5% to 15%.[14,15]In the poor world, there is a significant prevalence of the use of intramuscular injections without consideration. Due to a good healthcare system that only allows skilled persons to be engaged in the treatment of patients, the prevalence of post-injection palsy has significantly decreased in the industrialized world.[16]

In current study 130 patients of both genders were presented with peripheral nerve injuries. In all 130 patients, 82 (63.1%) cases were males and 48 (36.9%) patients were females. 45 (34.6%) patients had age 8-15 years, 30 (23.1%) cases had age 16-25 years, 33 (25.4%) cases had age 26-35 years and 22 (16.9%) patients had age >35 years. These results were inline with the previous studies.[17,18] Although a recent, thorough research has been conducted, the mechanism of nerve damage visible after peripheral nerve block is still not fully understood [19]. In animal models, it has been demonstrated that intraneural extrafascicular injection, which is more harmful than totally extraneural injection, causes the most damage to the nerve micro-architecture, followed by intraneural, intrafascicular needle trauma, and injection of local anesthetic [20]. Even in the absence of neuronal compression caused by intraneural injection, disruption of the fascicle's protective perineurium caused by intrafascicular injection can cause axons to become vulnerable to inflammatory processes, toxicity caused by local anesthetics, and detrimental direct mechanical injury. Intraneural injections must be avoided, there is no question about that [21].

As the operation has a rather high morbidity rate, intramuscular injections in youngsters should be avoided at all costs. The idea that avoiding intravenous injections in children will have unfavorable effects need to be disregarded. Injuries caused by intramuscular injections will be significantly less common as a result of this. In our research, 80 percent of the patients experienced an immediate neurological deficit after receiving injectable therapy. It happened a few hours to days after the injectable therapy in 7% of the patients. The presence of an instant neurological deficit points to a direct neural injury caused by the injection's needle and the medicine it releases into the nerve. There is intraneural bleeding, myelin sheath injury, and axon damage, all of which eventually cause nerve denervation and perineural scarring. A delayed neurological insult, however, is most likely brought on by perineural injury brought on by the caustic impact of the drugs. The nerve is tethered to the surrounding muscle and soft tissue, and there is accompanying muscle necrosis with additional neural injury.[22,23]

Following intramuscular injection, post-brachial block, and intravenous cannulation procedures in the neck and limbs, the majority of patients in our series had neurogenic pain and motor paralysis right away. These results demonstrated that neural injury occurred immediately after the injection therapy and that secondary involvement of the nerve that emerges later was not a typical occurrence. Following a block surgery and intravenous cannulation in the neck, patients with brachial plexus injury frequently presented with involvement of the C8-T1 roots to the lower trunk in our series. The probable cause of these roots being involved was the close proximity of the subclavian and jugular veins to the lower roots and the medial direction of the needle during the block procedure and the intravenous cannulation. Severe neurogenic pain (VAS >6) was more common in patients following a brachial plexus block and an intravenous cannulation procedure. In contrast, severe neurogenic pain was not a common manifestation following an intramuscular injection-related peripheral nerve injury. The probable cause of this difference was more severe axonal damage due to repeated attempts at puncturing the tissues during the brachial block and intravenous cannulation procedure.[24,25]

The peroneal nerve was injured in 100% of the patients following sciatic nerve injury caused by intramuscular injections in the gluteal region. However, only 45.7% of patients' tibial nerves were impacted. The peroneal nerve is located posterolaterally within the sciatic nerve, where it has less connective tissue, axons,

and vascularity than the tibial nerve. These factors together may explain why there is a higher prevalence of peroneal nerve involvement than tibial nerve involvement.[26]

In current study, Post-treatment mean pain score reduced to 1.4±7.16 and functional power grade 2 was noted among 62 (47.7%) cases. Patients who underwent surgery six months after their injuries who had sustained post-injection injuries to their sciatic nerves, brachial plexus, and various other peripheral nerves saw a significant decline in their outcomes. Patients with post-injection damage to the peroneal nerve or C8-T1 roots to their lower trunk saw even poorer outcomes. Following the harm from the injection, the delayed intervention extensively denervated the afflicted nerve. When external neurolysis was used instead of nerve grafting, the functional results were better. These results agreed with the research review.[27,28]

CONCLUSION

We came to the conclusion that a quick referral to a specialized peripheral nerve center, an early intervention, and early diagnosis are just a few crucial elements that can lead to a positive outcome and reduce the frequency of medicolegal lawsuits. By having in-depth anatomical understanding and providing patients with adequate counseling before to the treatment, the problem can be avoided in the vast majority of cases.

REFERENCES

- 1 Denny-Brown D, Doherty M. Effects of transient stretching of peripheral nerve. *Archives of Neurology and Psychiatry* 1945; 54: 116–29.
- 2 Cheney FW, Domino KB, Caplan RA, Posner KL. Nerve injury associated with anesthesia a closed claims analysis. *Anesthesiology* 1999; 90: 1062–9.
- 3 Sawyer RJ, Richmond MN, Hickey JD, Jarratt JA. Peripheral nerve injuries associated with anaesthesia. *Anaesthesia* 2000; 55: 980–91.
- 4 Denny-Brown D, Brenner C. Paralysis of nerve induced by direct pressure and by tourniquet. *Archives of Neurology and Psychiatry* 1944; 51: 1–26.
- 5 Stoelting R. Postoperative ulnar nerve palsy – is it a preventable complication? *Anesthesia and Analgesia* 1993; 76: 7–9.
- 6 Alvine F, Schurrer M. Postoperative ulnar-nerve palsy. Are there predisposing factors? *Journal of Bone and Joint Surgery* 1987; 69: 255–9.
- 7 Welch MB, Brummett CM, Welch TD, et al. Perioperative peripheral nerve injuries. *Anesthesiology* 2009; 111: 490–7.
- 8 Martyn CN, Hughes RA. Epidemiology of peripheral neuropathy. *Journal of Neurology, Neurosurgery, and Psychiatry* 1997; 62: 310–8.
- 9 Yim G, Lin Z, Shirley C, Isherwood P, Power D. The late diagnosis of nerve injuries following interscalene block and shoulder surgery. *J Musculoskelet Surg Res* 2019;3:1:141-145
- 10 Barlas K, George B, Hashmi F, Bagga T. Open medial placement of Kirschner wires for supracondylar humeral fractures in children. *J Orthop Surg (Hong Kong)* 2006; 14:53–57
- 11 Gadsden JC, Lindenmuth DM, Hadzic A, Xu D, Somasundaram L, Flisinski KA: Lumbar plexus block using high-pressure injection leads to contralateral and epidural spread. *Anesthesiology* 2008;109:683–688.
- 12 Theron PS, Mackay Z, Gonzalez JG, Donaldson N, Blanco R: An animal model of "syringe feel" during peripheral nerve block. *Reg Anesth Pain Med* 2009;34:330–332.
- 13 Auroy Y, Narchi P, Messiah A, Litt L, Rouvier B, Samii K. Serious complications related to regional anesthesia: Results of a prospective survey in France. *Anesthesiology* 1997;87:479-86
- 14 Villarejo FJ, Pascual AM. Injection injury of the sciatic nerve (370 cases). *Childs Nerv Syst* 1993;9:229-32
- 15 Gilles FH, French JH. Postinjection sciatic nerve palsies in infants and children. *J Pediatr* 1961;58:195-204.
- 16 Napiontek M, Ruszkowski K. Paralytic drop foot and gluteal fibrosis after intramuscular injections. *J Bone Joint Surg Br* 1993;75:83-5
- 17 Desai K, Warade AC, Jha AK, Pattankar S. Injection-related iatrogenic peripheral nerve injuries: Surgical experience of 354 operated cases. *Neurol India* 2019;67, Suppl S1:82-91
- 18 Reina MA, de Leon-Casasola OA, Lopez A, De Andres J, Martin S, Mora M: An in vitro study of dural lesions produced by 25-gauge Quincke and Whitacre needles evaluated by scanning electron microscopy. *Reg Anesth Pain Med* 2000;25:393–402.

- 19 Candido KD, Sukhani R, Doty R Jr, et al: Neurologic sequelae after interscalene brachial plexus block for shoulder/upper arm surgery: the association of patient, anesthetic, and surgical factors to the incidence and clinical course. *Anesth Analg* 2005;100:1489–1495, table of contents
- 20 Bigeleisen PE: Nerve puncture and apparent intraneural injection during ultrasound-guided axillary block does not invariably result in neurologic injury. *Anesthesiology* 2006;105:779–783.
- 21 Khan R , Birch R . Iatrogenic injuries of peripheral nerves. *J Bone Joint Surg Br* 2001; 83:1145–1148
- 22 Gentili F, Hudson AR, Kline D, Hunter D. Early changes following injection injury of peripheral nerves. *Can J Surg* 1980;23:177-182
- 23 Shukla DP, Bhat DI, Devi BI, Gopalakrishnan MS, Moiyadi A. Injection injuries of peripheral nerves. *Indian J Neurotrauma* 2004;1:21-3
- 24 Karakaya D, Baris S, Güldogus F, Incesu L, Sarihasan B, Tür A. Brachial plexus injury during subclavian vein catheterization for hemodialysis. *Clin Anesth* 2000;12:220-
- 25 Trentman TL, Rome JD, Messick JM Jr. Brachial plexus neuropathy following attempt at subclavian vein catheterization. *Case Report. Reg Anesth* 1996;21:163-5
- 26 Gaur SC, Swarup A. Radial nerve palsy caused by injections. *J Hand Surg [Br]* 1996;21:338-40.
- 27 Dziewas R, Lüdemann P. Hypoglossal nerve palsy as complication of oral intubation, bronchoscopy and use of the laryngeal mask airway. *European Neurology* 2002; 47: 239– 43.
- 28 Warner M, Warner D, Matsumoto J, Harper M, Schroeder D, Maxson P. Ulnar neuropathy in surgical patients. *Anesthesiology* 1999; 90: 54– 9.