

# Histopathological Review of Skin Diseases: A Three Years Survey of 510 Skin Biopsies in Multan

SEHAR SHAMSHAD ALI<sup>1</sup>, KANWAR SAJID ALI<sup>2</sup>, ROZINA KANWAR<sup>3</sup>, HAFIZ MUHAMMAD KAMRAN KHALID<sup>4</sup>, ZERTAJ KASHIF<sup>5</sup>

<sup>1</sup>Assistant Professor Pathology MBBS, M Phil Haematology, Bakhtawar Amin Medical & Dental College, Multan

<sup>2</sup>Associate Professor Pathology Bakhtawar Amin Medical & Dental College, Multan

<sup>3</sup>Clinical Assistant Mississauga (Toronto) Canada

<sup>4</sup>DHQ Muzaffargarh

<sup>5</sup>FCPS Histopathology Professor Pathology Bakhtawar Amin Medical & Dental College, Multan

Correspondence author: Zertaj Kashif, Email: [zkashif786@icloud.com](mailto:zkashif786@icloud.com), Cell: 0314 6121201

## ABSTRACT

**Introduction:** Skin ailments share a major disease burden worldwide (1, 2). They are considerably frequent in underdeveloped nations and encompass simple ailments like inflammation and pimples to certain grave diseases like skin melanomas (3). However, the type and prevalence of skin disorders differ from area to area on account of dissimilar habitat (4, 5). Skin disorders influence human lives in various ways and many a times the dermal epidermal conditions point some internal ongoing serious disease (6). A vast majority of skin diseases are treated on the basis of clinical diagnosis without confirmation through biopsy. Microscopic examination is mandatory for verification and precise diagnosis and to direct the clinician to opt suitable treatment (7). Considering their importance, the research work being done on the prevalence of specific disorders in particular regions in our country appears deficient especially considering the clinicopathological consonance. The current research was outlined to acumen the skin diseases related burden in our institute.

**Aim & Objective:** The aim of this research is to evaluate the histopathological diversity of skin diseases and their prevalence in Multan region along with the clinic-pathological consonance.

**Study Design:** Retrospective cross sectional study

**Place and Duration:** Histopathology and dermatology departments of Bakhtawar Amin Medical & Dental College and Trust Hospital Multan, from January 2020 to December 2022.

**Material and Methods:** Histopathological reports of all skin biopsies were sorted. The required data like age, gender, clinical presentation, site of the lesion, dermatologist's findings, and their clinical provisional impression with differential diagnoses were documented along with the histopathological microscopic opinion. The particulars were gathered from clinical files, histopathological demand forms and documented reports.

**Results:** A sum of 510 skin biopsies was received in histopathology section. Out of these, 280 (54.9%) were females and remaining 230 (45.1%) were males. The mean age was 34.70 years (ranging from 2 to 84 years). Most of them were between ages 16-30 years. Majority of the lesions were benign non cancerous and related to skin appendages. Epidermal inclusion cyst appeared to be the most prevalent. Out of 510 biopsies, 68 (13.3%) turned out to be malignant neoplasms.

**Conclusion:** A vast majority of skin diseases are treated only on the basis of clinical diagnosis. The present study revealed that the histopathological opinion was consistent with the clinical judgment in 63 % of the cases, unveiling the significance of histopathological examination that is must for saving time and expenses of the patients. It also helps in reduction of the morbidity related to various skin disorders

**Keywords:** Histopathology, dermatology, skin disorders, skin cancers, epidermal inclusion cyst

## INTRODUCTION

Skin diseases are frequently experienced in clinical practice and affect a noteworthy percentage of people in all the communities globally; being more prevalent in underdeveloped nations where these lesions are substantially neglected because of low resources<sup>(8,9)</sup>. Skin disorders result from a disparity in metabolism and congruence of various minerals, vitamins and other products in body leading to diversified ailments from acne, alopecia to lethal neoplasms<sup>29</sup>. Most of these disorders are straightforward and easily curable<sup>8</sup>. Many a times people go with painless skin disorders like inclusion cysts, freckles, acne etc without seeking any treatment especially in underdeveloped countries with low resources. Other times because of lack of awareness and insufficient understanding the skin lesions especially the dermatosis and infectious diseases go neglected and treated only by clinical impression without confirmation through histopathological examination and lead to incorrect and late diagnosis with subsequent greater morbidity<sup>(10,11)</sup>. Several skin lesions have indistinguishable clinical presentations for which microscopic diagnosis is must. Various others have overlapping and interchangeable histological features with different clinical way of presentations. Considering these overlapping features, clinical correspondence along with microscopic examination is must for the final analysis<sup>3</sup>. The goal of our study was to determine the range of microscopic conclusion of skin lesions along with their frequency as well as to verify the clinico-pathological harmony related to their diagnosis. It will help in establishing a set criterion for diagnosis of skin lesions and save time and money of the patients as well as aid in the reduction of morbidity associated with

several skin diseases. Given the prevalence of skin diseases and their related complications especially in underdeveloped nations, we barely find accurate figures and established consensus related to the clinico-pathologic correlation, pervasiveness of various dermatologic disorders and diagnostic measures. Our study will definitely explore and address all the above mentioned points with suggestions for further research works.

## MATERIAL AND METHODS

**Research Design:** Retrospective cross-sectional study.

**Time and Duration:** Bakhtawar Amin Medical & Dental College and Hospital, Multan for duration of 3 years from January 2020 to December 2022.

**Population:** Every age group including both genders in Multan & periphery

**Sampling and Sample Size:** Histopathological transcripts of all skin biopsies were incorporated. Total 510 skin biopsies were received in 3 years.

**Data Collection Procedure:** Statistics like age, gender, location of the lesion, presenting complaints, clinical observations with their provisional and differential impressions were noted along with the microscopic histopathological opinion of every skin biopsy. The data was obtained from medical record charts and request forms.

**Data Analysis Plan:** The data was entered in Microsoft word and descriptive details were procured. Relevant variables were noted and their percentages were enumerated. Appropriate graphs were figured.

**RESULTS**

A total of 510 skin biopsies were received in histopathology laboratory. The age range was from 02 to 84 years with mean age 34.70 years. A large portion of patients was between ages 16 to 30 years. Total 280 (54.9%) were females and 230 (45.1%) were males.

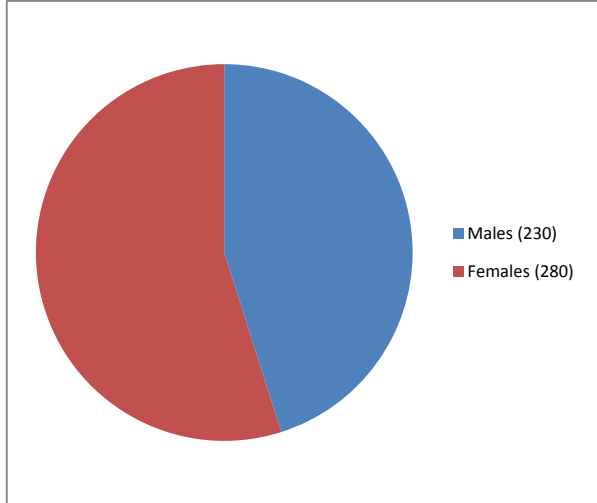


Figure 1: Gender Distribution

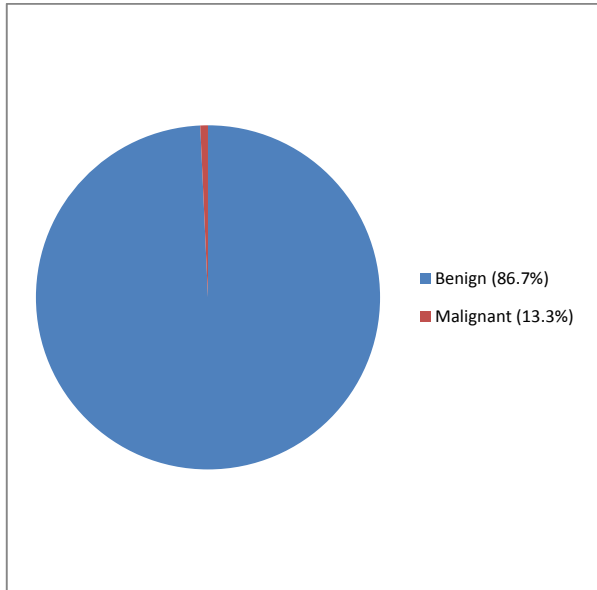


Figure 2: Benign & Malignant Cases Distribution

Out of total 510, 442 (86.7%) skin biopsies were reported as benign; only 68 (13.3%) turned out to be malignant. Disorders of skin appendages were the commonest followed by skin infections and vesico-bullous lesions. Epidermal inclusion cyst was the commonest benign lesion. Basal cell carcinoma was the most frequently encountered malignant tumor (63/68) 92.6%. Pemphigus vulgaris was the most common bullous lesion followed by bullous pemphigoid. Among infections, viral warts and leishmaniasis appeared most prevalent. Psoriasis and Lichen Planus were the frequent papulosquamous disorders. Melanocytic nevi were the most common pigmented lesions found. Pyogenic granulomas and keloids encompass major portion of the miscellaneous others group.

Table 1: Distribution of skin diseases

Types of skin disorder	Number of cases (n=510)	Percentage of cases (%)
Vesicobullous lesions	78	15.3
Infectious lesions	97	19
Autoimmune connective tissue lesions	12	2.4
Eczematous lesions	09	1.8
Skin appendage lesions	110	21.6
Papulosquamous lesions	15	2.9
Pigmented lesions	19	3.7
Other miscellaneous lesions	37	7.3
Benign tumors	65	12.7
Malignant tumors	68	13.3

Table 2: Histopathological diagnosis of malignant lesions

Histopathological diagnosis	Number of cases (n=68)	Percentage (%)
Basal cell carcinoma	55	81
Squamous cell carcinoma	09	13
Melanoma	02	3
Merkel cell carcinoma	01	1.5
Cutaneous T cell Lymphoma	01	1.5

Table 3: Histopathological and clinical correlation of skin diseases

Skin Diseases	Total number of cases	Correct clinical diagnoses (Number & percentage % of cases)	Histopathological Proven diagnosis (Number & percentage % of cases)
Non infectious, infectious benign skin lesions	442	256 (57.9%)	442 (100 %)
Malignant skin lesions	68	66 (97 %)	68 (100%)
Total number of cases	510	322 (63.1 %)	510 (100%)

**DISCUSSION**

In our study, most of the skin diseases were identified in the ages 16-30 years and were benign / infective in nature. The mean age of patients was 34.70 years that is comparable with several studies conducted in Pakistan and abroad by Shahbaz H et al, Albasari AM, Azam F and Suleri ZS<sup>12,13,14,15</sup>. The gender distribution in our study was 280 (54.9%) females and 230 (45.1%) males which is in accordance with the studies by Ndukwe CO et al where 48 (42.7%) of the patients were males and 199 (57.3%) were females and Shahbaz H where females were 55% and males 45% (9, 12). The overall occurrence of benign lesions in our research was 442/510 (86.7%) as compared to 68/510 (13.3%) malignant lesions. This outcome is supported by various studies<sup>16,17</sup>. Only 13.3% of the cases turned out to be malignant. This is comparable with the study by Azam F where the neoplastic lesions were 10.5% (14). Epidermal inclusion cyst was the commonest benign lesion in accordance with several other studies<sup>9,13,18</sup>. Basal cell carcinoma was the most frequently encountered malignant tumor (63/68) 92.6% comparable to studies by Garrubba C, Gallo JC et al and Al-Dawsari NA<sup>19,20,21</sup>. Pemphigus vulgaris was the most common bullous lesion followed by bullous pemphigoid comparable with various other studies<sup>5,22</sup>. The study conducted by Ali J also found these two as the frequently encountered bullous lesions<sup>23</sup>. Among infections, viral warts and leishmaniasis appeared most prevalent in accordance with several other researches<sup>24,25,26</sup>. Psoriasis and Lichen Planus were the frequent papulosquamous disorders relatable with the studies by Ndukwe CO and Gandhi J<sup>9,27</sup>. Melanocytic nevi were the most common pigmented lesions found comparable with the study by Sharma DC<sup>28</sup>. The neoplastic lesions especially the malignant cases were found mostly in head and neck region. The non infectious benign disorders were seen on trunk followed by the extremities<sup>30</sup>. The histopathological opinion was consistent with clinical diagnosis in 322 out of 510 cases making an overall consonance of 63% of cases. This is consistent with study conducted by Venugopal R where the clinical and

pathological harmony was found to be 67.5%<sup>31</sup>. The clinicopathological harmony was eminent for malignant cases (97 %). Sixty six out of 68 malignant cases on microscopic examination were diagnosed as malignant by the dermatologists as well. Only two underdiagnosed cases by the clinicians proved to be malignant by the histopathologists. This overall high clinical and histological concordance for malignant cases has been proved by various other studies<sup>11,32</sup>. Significant variation in consonance among various clinical and histopathological diagnoses was noticed with an overall low concordance; contemplating the fact that the clinicians only take biopsies when they are not able to treat patients on the basis of their clinical diagnosis. The reasons of low harmony are the similarities in clinical presentation of various skin lesions and multiple differential diagnoses. Many patients were wrongly managed on the basis of clinical evaluation and when there is no improvement in symptoms, the biopsies were sent.

## CONCLUSION

Non neoplastic benign conditions are the usually encountered skin pathologies. Epidermal inclusion cyst and basal cell carcinoma were most frequently noticed benign and malignant skin disorders respectively. It is suggested that clinicians must take skin biopsies for histopathological confirmation of their diagnosis to reduce morbidity due to various skin disorders.

**Limitations:** Single institute; small number of skin biopsies referred by dermatologists. In our country a large majority of people don't consult physicians for skin problems until and unless there is any noticeable inconvenience; even if they do, many physicians treat cases on the basis of their clinical diagnosis only without going for histopathological confirmation. Due to such delay even mild non neoplastic benign / infective conditions deteriorate. Similar studies in various regions of country are suggested to make a set criterion including both clinical and histological evaluation and to outline protective prophylactic schemes for reduction of numerous skin disorders associated morbidity.

## REFERENCES

- Flohr C, Hay R. Putting the burden of skin diseases on the global map. *British Journal of Dermatology*. 2021 Feb 1;184(2):189-90.
- Seth D, Cheldize K, Brown D, Freeman EE. Global burden of skin disease: inequities and innovations. *Current dermatology reports*. 2017 Sep;6:204-10.
- Chalise S, Dhakhwa R, Pradhan SB. Histopathological study of skin lesions in a tertiary care hospital: A descriptive cross-sectional study. *JNMA: Journal of the Nepal Medical Association*. 2020 Apr;58(224):218.
- Sheroze MW, Zaidi SA, Mehmood BB, Khan E, Ali SA, Mazher S, Jamal K. Frequency of skin diseases and associated factors in a tertiary care hospital in Karachi. *Journal of Pakistan Association of Dermatologists*. 2020;30(3):456-60.
- Aman S, Nadeem M, Mahmood K, Ghafoor MB. Pattern of skin diseases among patients attending a tertiary care hospital in Lahore, Pakistan. *Journal of Taibah University Medical Sciences*. 2017 Oct 1;12(5):392-6.
- Sampaio AL, Bressan AL, Vasconcelos BN, Gripp AC. Skin manifestations associated with systemic diseases—Part I. *Anais Brasileiros de Dermatologia*. 2022 Jan 17;96:655-71.
- Goswami P, Parekh M, Goswami A. Histopathology spectrum of skin lesions in teaching institution. *Journal of Family Medicine and Primary Care*. 2022 Aug 1;11(8):4610-3.
- Mengist Dessie A, Fenta Feleke S, Getaye Workie S, Getinet Abebe T, Mossu Chanie Y, Kassa Yalew A. Prevalence of Skin Disease and Its Associated Factors Among Primary Schoolchildren: A Cross-Sectional Study from a Northern Ethiopian Town. *Clinical, Cosmetic and Investigational Dermatology*. 2022 Apr 29:791-801.
- Ndukwe CO, Chiemeka ME, Eziagu UB, Ndukwe CC, Uzoigwe JC. Histopathological spectrum and clinicopathological concordance of nonneoplastic skin lesions at a teaching hospital in South-Eastern Nigeria: A 16-year retrospective study. *Journal of Nature and Science of Medicine*. 2021 Oct 1;4(4):373.
- Nageen S, Waqas N, Mehmood A. Association Of Clinical Diagnosis With Histopathology In Various Skin Diseases. *Journal of Ayub Medical College, Abbottabad: JAMC*. 2021 Apr 1;33(2):252-6.
- Al-Saif FM, Binsufayan SA, Alhussain AH, Alkaff TM, Alshaikh HM, Aldosari MS, Binsufayan SA, AlTaleb RM, Alotaibi HM, Alshahwan MA. Clinicopathological concordance in the diagnosis of skin diseases: a retrospective analysis of 5000 histopathology reports. *Annals of Saudi Medicine*. 2019 Dec;39(6):388-94.
- Shahbaz H, Sohail A, Amir S. Frequency of various skin disorders among patients attending outpatient department of a tertiary care hospital. *Journal of Pakistan Association of Dermatologists*. 2020 Sep 30;30(2):316-22.
- Albasri AM, Ansari IA. The histopathological pattern of benign and non-neoplastic skin diseases at King Fahad Hospital, Madinah, Saudi Arabia. *Saudi Medical Journal*. 2019;40(6):548.
- Azam F, Munir S, Ashraf A, Imran AA, Rashid T. Histopathological analysis of skin biopsies in a tertiary care setting. *Journal of Pakistan Association of Dermatologists*. 2017;27(2):154-7.
- Suleri ZS, Rani Z, Suleri KM. Pattern of skin diseases presenting in outpatient department of dermatology, Khawaja Muhammad Safdar Medical College Sialkot. *Journal of Pakistan Association of Dermatologists*. 2020 Sep 30;30(2):327-30.
- Bansal M, Sharma HB, Kumar N, Gupta M. Spectrum of skin lesions including skin adnexal tumors in a North Indian tertiary care hospital. *Head and neck*. 2019;58:17.
- Sherpa P, KC SR. Histopathological Evaluation of Skin Neoplasms. *Nepalese Medical Journal*. 2018 Dec 2;1(2):89-93.
- Weir CB, St Hilaire NJ. (2022). Epidermal inclusion cyst.
- Garrubba C, Donkers K. Skin cancer. *Jaapa*. 2020 Feb 1;33(2):49-50.
- Gallo JC, Schneider JW, de Wet J, Moxley K, Jordaen HF, Visser WI, Tod B. A Profile and Three-Year Follow-Up of Patients with Basal Cell Carcinoma in the Western Cape, South Africa. *Journal of Skin Cancer*. 2022 May 5;2022.
- Al-Dawsari NA, Amra N. Pattern of skin cancer among Saudi patients attending a tertiary care center in Dhahran, Eastern Province of Saudi Arabia. A 20-year retrospective study. *International journal of dermatology*. 2016 Dec;55(12):1396-401.
- Kudligi C, Thirunavukkarasu A, Kuntoji V, Bhagwat PV, Rathod R, Girian S, Sharma A, Andanappanavar V. Clinical and pathological study of autoimmune vesiculobullous disorders. *Journal of Pakistan Association of Dermatologists*. 2017;27(3):270-8.
- Ali J, Islam S, Ali SM, Yaqeen SR, Aslam A, ul ain Khan Q, Malik UA, Irfan M, Naqvi H, Hashmi AA. Morphological spectrum of vesiculobullous skin lesions: An institutional perspective. *Cureus*. 2021 May 30;13(5).
- Asghar N, Asghar M, Rehman N, Afridi IU, Khalid S. Epidemiological and clinical patterns of viral warts presenting to dermatology OPD of Hayatabad Medical Complex, Peshawar: Epidemiological and clinical patterns of viral warts. *Journal of Pakistan Association of Dermatologists*. 2022 Mar 29;32(1):78-84.
- Kayani B, Sadiq S, Rashid HB, Ahmed N, Mahmood A, Khaliq MS, Maqsood R, Rashid H, Hasan S, Mushtaq MH, Zia UU. Cutaneous Leishmaniasis in Pakistan: a neglected disease needing one health strategy. *BMC Infectious Diseases*. 2021 Dec;21:1-0.
- Yousuf MJ, Ahmad N, Masood Z, Majeed S, Hassan HU, Ibrahim M, Khooharo AR, Khooharo E, Mastoi AH, Zafar N, Shaikh FM. Prevalence of cutaneous leishmaniasis in the largest populated city Karachi, Pakistan. *Brazilian Journal of Biology*. 2021 Dec 17;83.
- Gandhi J, Agrawal S, Gupta S, Verma K, Mohite A. Pattern of Papulosquamous Disorders in Children: A Clinico-Epidemiological Study. *Cureus*. 2022 Jan 13;14(1).
- Sharma DC. Pigmented skin lesions: are they all of melanocytic origin? A histopathological perspective. *Rajesh Singh Laishram, Barida Ginia Myrthong, Sharmila Laishram, Rachel Shimray, Arun. Journal of Pakistan Association of Dermatologists*. 2013 Sep 30;23(3).
- Bezbaruah R, Baruah M. Histopathological spectrum of skin lesions-A hospital based study. *Indian J Appl Res*. 2018;8:51-2.
- NAGAYACH P, KUMAR L, RAWAL D, SINGH P, KUMAR H, CHAHAR Y. Evaluation of Histomorphological Spectrum of Skin Lesions at a Teaching Institute in Agra: A Cross-sectional Study. *Journal of Clinical & Diagnostic Research*. 2022 Sep 1;16(9).
- Venugopal R, Shankar P, Pathania V. Clinicopathological correlation in the diagnosis of skin diseases: A retrospective study. *Medical Journal of Dr. DY Patil University*. 2020 Nov 1;13(6):648-52.
- Sa DK, Kumar P. Clinicopathological consistency in diagnosis of skin disorders: a retrospective study of 371 histopathology reports. *Journal of Pakistan Association of Dermatologists*. 2016 Nov 17;26(2):96-8.