

# Histopathological Diagnosis of Hysterectomy Specimens in Abnormal Uterine Bleeding

HUMA TAHSEEN<sup>1</sup>, SHABANA KHOKHAR<sup>2</sup>, NAILA ATIF<sup>3</sup>, SAIMA QURBAN<sup>4</sup>, HAFIZA NAVEEDA KHURSHID<sup>5</sup>, MAHLIQA MAQSUD<sup>6</sup>

<sup>1</sup>Associate Professor Department of Obs and Gyne, Azra Naheed Medical College, Superior University

<sup>2</sup>Associate Professor Department of Obs and Gyne Rahbar Medical And Dental College Lahore

<sup>3</sup>Professor of Pathology Rashid Latif Medical College

<sup>4</sup>Associate Professor Department of Obs and Gyne RLKU Medical College, Hameed Latif Teaching Hospital Lahore

<sup>5</sup>Assistant Professor Azra Naheed Medical College

<sup>6</sup>Professor Department of Obs and Gyne Unit 2, SIMS / Services Hospital, Lahore

Correspondence to: Shabana Khokhar, Email: [khokhar.shabana@gmail.com](mailto:khokhar.shabana@gmail.com), Cell: 03213104423

## ABSTRACT

**Background:** Abnormal uterine bleeding (AUB) is a common and distressing condition effecting predominantly perimenopausal women. Heavy menstrual bleeding (HMB) is the most common presentation of AUB. There are many structural and non structural causes of AUB. Histopathology of endometrial curettings is well studied before but the histopathological patterns of hysterectomy specimens are not well studied.

**Objective:** The objective of this study is to: Find out histopathological diagnosis of hysterectomy specimens in patients of AUB.

**Study Design:** Retrospective Cohort study.

**Place and Duration of Study:** Gynecology and Pathology departments of Azra Naheed and Rashid Latif medical colleges from January 2022 to January 2023.

**Methods:** Histopathology reports of all hysterectomies done for AUB in both medical colleges allied hospitals were retrieved retrospectively and evaluated in detail. Four age groups were defined 30-40 years, 41-50, 51-60 and 61-70 years. Various patterns were recorded overall and separately for each group and results established.

**Results:** A total of 221 abdominal hysterectomy histopathology reports were retrieved and evaluated. All hysterectomies were performed for AUB during one year period between January 2022 to January 2023. 40(18.09%) women were between 30-40 years of age, 134(60.6%) were between 41-50 years of age, 39(17.6%) were between 51-60 years of age and 08(3.61%) patients were between 61-70 years of age. Distorted proliferative phase endometrium was seen in 28(12.6%) of cases, Adenomyosis was seen in 76(34.38%), endometrial polyps in 19(8.55%), fibroids in 92(41.6%), metaplasia 07(3.1%), hyperplasia 10(4.5%), and endometrial carcinoma was seen 09 (4.07%) of cases.

**Conclusion:** AUB is most common in perimenopausal women. Fibroids, Adenomyosis, and disordered proliferative endometrium were most common in perimenopausal women while carcinoma endometrium was most common cause of AUB in postmenopausal women. This study will help Gynecologists to better find out the cause of AUB and treat accordingly.

**Keywords:** Abnormal uterine bleeding (AUB), Heavy menstrual bleeding (HMB), Perimenopausal, Hysterectomy, Histopathology, Endometrium

## INTRODUCTION

Abnormal uterine bleeding (AUB) is a common and distressing condition which can effect women of any age but commonly effects perimenopausal women<sup>1</sup>. AUB is a variation from normal menstrual cycle in terms of frequency, regularity, duration, or volume of blood flow in the absence of pregnancy<sup>2</sup>. Variations in any of these 4 parameters constitute AUB<sup>1,2</sup>. AUB has variable presentations and women can present with heavy menstrual bleeding (HMB), intermenstrual bleeding (IMB) or combination of heavy and prolonged menstrual bleeding. The most common clinical presentation of AUB with which women report to gynecological clinics is heavy menstrual bleeding (HMB)<sup>3</sup>. HMB causes chronic anemia, easy fatigability and poor quality of life in women in developing countries and is under reported disease as well<sup>4</sup>. Previously used terminologies like menorrhagia, metrorrhagia, hypermenorrhea, menometrorrhagia, polymenorrhoea and dysfunctional uterine bleeding have been standardized and replaced with the terminology of heavy menstrual bleeding (HMB), intermenstrual bleeding, and unscheduled bleeding or breakthrough bleeding by international federation of gynecology and obstetrics in FIGO system 1S<sup>5</sup>. Similarly regarding the etiology of AUB various causes were proposed in various proportions. To bring harmony and consensus etiology of AUB was classified into structural and non-structural causes in FIGO system 2, published in 2011 using the PALM-COEIN acronym<sup>3,6</sup>.

PALM represents virtually objective structural criteria: Polyp, Adenomyosis, Leiomyoma, Malignancy

COEIN for causes unrelated to structural anomalies: Coagulopathy, Ovulatory disorders, Endometrial, Iatrogenic, Not classified causes

The first line treatment of AUB is hormonal in various dosages and regimens<sup>7</sup> but when the conservative treatment fails

the definite treatment which cures the disease completely is hysterectomy<sup>8,9</sup>.

To rule out malignancy and to fine out structural causes of AUB endometrial biopsies by curettage are often advised by clinicians. Many previous studies are based on histopathological pattern of uterine curettage in patients with AUB<sup>10</sup> and hysterectomy specimens are not well studied. The aim of this study is to find out the histopathological patterns in patients undergoing hysterectomy for AUB. This will help to find out histological changes in endometrium and myometrium in detail in patients with AUB and help Gynecologists to better understand the etiology of AUB and treat the patients of AUB more effectively.

## METHODOLOGY

**Research Design:** This was a retrospective Cohort study which was record based.

**Population:** All patients who present with AUB at allied teaching hospitals of Azra Naheed Medical College and Rashid Latif medical college Lahore were taken as population

**Sample and Sampling Technique:** All patients who underwent hysterectomy at gynecology and pathology departments of Azra Naheed Medical College and Rashid Latif medical college Lahore from January 2022 to January 2023 were taken as Cohort. Simple random sample technique was applied.

**Development of Instrument:** After ethical approval from both medical colleges histopathology reports of all hysterectomy specimens done due to AUB during one year period from January 2022 to January 2023 were retrieved from pathology departments of both medical colleges. All these reports were verified by consultant histopathologists and were written in detail.

**Data Collection Procedure:** Complete histopathology reports were thoroughly read and important observations like ID, age, date of surgery and diagnosis in uterine specimens were noted.

Patients according to age were grouped as between 30-40 years, 41-50, 51-60, and 61-70 years. Diagnosis were recorded collectively and in each group separately and results established.

**Data Analysis Plan:** Descriptive statistics like mean, frequencies of various diseases was calculated using SPSS.

**RESULTS**

A total of 221 abdominal hysterectomy histopathology reports were retrieved and evaluated from both teaching hospitals, 133 from Rashid Latif and 88 from Azra Naheed Hospital. All hysterectomies were performed for AUB during one year period between January 2022 to January 2023. Mean age of patients was 46.2 years (SD±6). Mean of age of women with AUB was comparable to other studies when two sample t test was applied and statistically insignificant difference noted ( $p > 0.05$ )<sup>10</sup>. Age ranged between 35-70 years. 40(18.09%) women were between 30-40 years of age, 134(60.6%) were between 41-50 years of age, 39(17.6%) were between 51-60 years of age and 08(3.61%) patients were between 61-70 years of age (figure 2).

Normal proliferative phase endometrium was seen in 73(33%) of cases while normal secretory phase endometrium was

observed in 17(7.6%) of specimens. Distorted proliferative phase endometrium was seen in 28(12.6%) of cases, chronic endometritis in 13(5.8%), atrophic endometrium in 30(13.57%), autolytic changes were seen in 25(11.3%) of cases. Adenomyosis was seen in 76(34.38%), endometrial polyps in 19(8.55%), fibroids in 92(41.6%), metaplasia 7(3.1%), hyperplasia 10(4.5%), atypical hyperplasia 4(1.8%) and endometrial carcinoma was seen 09 (4.07%) of cases. No statistically significant difference noted between frequency of various diseases in women of different age groups in different studies  $p > 0.05$ .

In age group 30-40 most common finding was fibroid uterus found in 22(55%) specimens followed by normal proliferative phase endometrium found in 17(42%) specimens. In age group 41-50 most common finding was fibroid uterus in 61(45.5%) cases followed by Adenomyosis in 49(36.5%) specimens. In age group 51-60 most common finding was Adenomyosis in 15(38.45%) specimens followed by atrophic endometrium in 12(30.7%) specimens. In age group 61-70 years most common finding was atrophic endometrium in 5(62.5%) specimens followed by endometrial carcinoma, metaplasia and autolytic changes in 3(37.5%) specimens (figure 3).

Table 1: Most Common Pathologies in Various Age Groups

Age	30-40 years	41-50 years	51-60 years	61-70 years
Maximum pathology noted	Fibroids 55% specimens followed by normal proliferative endometrium 42%	Fibroids 45.5% specimens followed by Adenomyosis 36.5%	Adenomyosis 38.45 followed by atrophic endometrium 30.7%	Atrophic endometrium 62.5% followed by CA endometrium, metaplasia and autolytic changes 37.5%

Table 2: Overall Summary of Pathologies Noted in Hysterectomy Specimens

Age in years	Histopathological				Total
	30-40	41-50	51-60	61-70	
Findings					
Proliferative phase endometrium	17	45	10	01	73(33%)
Secretory phase	03	14	Nil	Nil	17(7.6%)
Disordered proliferative	07	15	04	02	28(12.6%)
Chronic endometritis	02	08	02	01	13(5.8%)
Atrophic endometrium	03	10	12	05	30(13.57%)
Autolytic changes	02	15	05	03	25(11.3%)
Adenomyosis	11	49	15	01	76(34.38%)
Endometrial polyps	05	11	03	Nil	19(8.55%)
Fibroids	22	61	09	Nil	92(41.6%)
Metaplasia	Nil	02	02	03	07(3.1%)
Hyperplasia	02	07	01	Nil	10(4.5%)
Atypical hyperplasia	Nil	03	01	Nil	4(1.8%)
Endometrial carcinoma	Nil	02	04	03	09(4.07%)

**DISCUSSION**

AUB which is one of the most common complaint of women presenting to gynecological clinics has many structural and non structural causes. The first portion PALM of famous acronym PALM-COEIN given by international federation of gynecology and obstetrics (FIGO) describes structural causes as polyp, Adenomyosis, leiomyoma, malignancy and hyperplasia. The second portion COEIN stands for nonstructural causes coagulopathy, ovarian dysfunction, endometrial disorders, iatrogenic and not other classified<sup>3,5,13</sup>. The most common presentation of AUB is heavy menstrual bleeding (HMB) and most commonly affects women of perimenopausal age group. HMB in this age group leads to anemia and distressing symptoms<sup>3,4</sup>. As majority of women in this age group has completed their families so women tend to opt for hysterectomy which is the definite treatment of AUB<sup>1,3,8</sup>. In our study 134 (60.06%) cases of hysterectomies were found to be of women of perimenopausal age group 41-50 years. The incidence of AUB is highest in this age group due to falling levels of estrogen resulting in anovulatory cycles. The studies conducted by Vijayaraghavan A Sr, et al<sup>10</sup> and Sharma R et al<sup>11</sup> also showed same results.

In our study endometrial polyps were noted in 19(8.55%) of hysterectomy specimens. Although the incidence of endometrial polyps in our study is low, other studies as conducted by Hussain S, et al<sup>12</sup> report endometrial polyps in AUB as high as 16-20%. Adenomyosis is a benign condition in which endometrial tissue grows into the myometrium of the uterus and can lead to variety of symptoms including AUB<sup>13</sup>. Adenomyosis can coexist with other conditions like leiomyomas and endometriosis as in our study 38(50%) of Adenomyosis co existed with leiomyomas. In our study 76(34.38%) specimens showed Adenomyosis which is nearly similar to the study conducted by Ansari A et al<sup>14</sup>.

Leiomyomas or fibroids are the most common benign tumors in perimenopausal women. Although they are benign but can lead to variety of symptoms including AUB especially when they are located submucosal<sup>15</sup>. In our study leiomyomas were found in 92(41.6%) hysterectomy specimens. Fibroids are more common in perimenopausal women and it is evident from our study as well as 61(45.5%) patients in group 41-50 years had fibroids. Overall 85% of specimens having fibroids had other conditions as well including Adenomyosis, distorted proliferative endometrium and endometritis and seldom fibroids found as an isolated pathology.

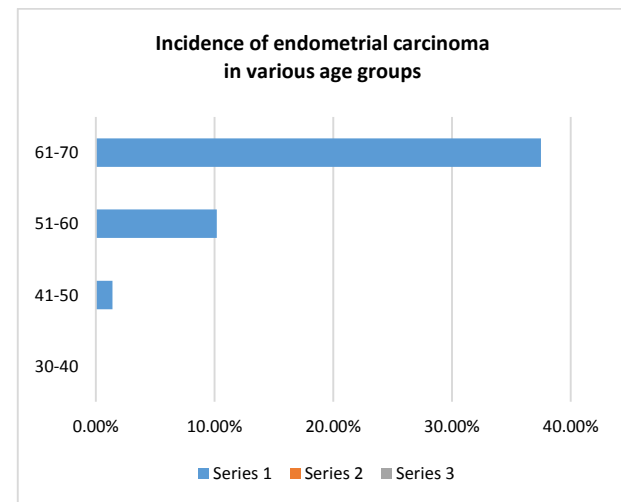


Figure 1: Endometrial Carcinoma in Histopathology Specimens in Various Age Groups

An important indication of hysterectomy in AUB is risk of malignancy. In our study endometrial carcinoma was found in 09(4.07%) overall hysterectomy specimens.

Highest incidence of carcinoma endometrium 37.5% was noted (03 specimens out of 08 )in age group 60-70 years followed by 10.2% in age group 51-60, 1.4% was noted in age group 41-50 years while in age group 30-40 no case of ca endometrium was found (figure 5). AUB in post menopausal women should be thoroughly investigated as risk of malignancy is high in this age group<sup>11,16</sup>. In a study conducted by Soja M et al<sup>17</sup> the incidence of carcinoma in post menopausal women was found to be 8.5 % which is more than our study.

Endometrial hyperplasia especially associated with atypia and metaplasia are significant conditions and can be premalignant lesions<sup>18</sup>. Metaplasia was noted in 3.1% specimens, hyperplasia in 4.5% while atypical hyperplasia was noted in 1.8% specimens. In a study conducted by Manga SM et al<sup>19</sup> in Cameron hyperplasia as high as 28% was noted.

Normal proliferative endometrium was noted in 33% specimens while secretory phase endometrium was observed in 7.6% of specimens. Disordered proliferative endometrium was observed in 12.6 % specimens. These results are nearly similar to the study conducted by Vani BS, et al in India<sup>20</sup>. Atrophic endometrium which is also physiological in post-menopausal women was noted in 13.57% specimens and was most commonly seen 62.5% specimens in age group 61-70. Weather atrophic endometrium causes AUB is debatable<sup>21</sup>. Chronic endometritis is a long standing inflammation of endometrium, having variety of causes which is characterized by infiltration of plasma cells in the endometrial stromal area<sup>22</sup>. Chronic endometritis usually does not exist as a single pathology in AUB .In our study 5.8% specimens were found to have chronic endometritis and none of the finding existed alone.

## CONCLUSION

AUB having many structural and nonstructural causes is most common in perimenopausal women. Among structural causes fibroids, Adenomyosis and disordered proliferative endometrium were most common in perimenopausal women while carcinoma endometrium was most common cause of AUB in postmenopausal women.

**Limitations:** As this was a retrospective observational study on histopathology specimens retrieved from pathology labs and hospital record registers, many limitations like lack of complete information regarding parity of patients was seen.

## REFERENCES

1. Bhardwaj TT, Hiwale KM, Vagha S. Correlation of Morphological Findings of Endometrium With Concerned Hormone Levels in Patients With Abnormal Uterine Bleeding: A Narrative Review. *Cureus*. 2022; 14(10): 30063. doi: 10.7759/cureus.30063. PMID: 36381922; PMCID: PMC9637461.
2. Chapagain S, Dungal G. Clinical and Histopathological Presentation of Abnormal Uterine Bleeding in Perimenopausal Women in Tertiary Center of Nepal. *J Nepal Health Res Coun*. 2020; 18(2): 248-252. doi: 10.33314/jnhrc.v18i2.2512. PMID: 32969387.
3. Elmaogullari S, Aycan Z. Abnormal Uterine Bleeding in Adolescents. *J Clin Res Pediatr Endocrinol*. 2018; 10(3): 191-97. doi: 10.4274/jcrpe.0014. Epub 2018 Feb 28. PMID: 29537383; PMCID: PMC6083466.
4. Kocaoz S, Cirpan R, Degirmencioglu AZ. The prevalence and impacts of heavy menstrual bleeding on anemia, fatigue and quality

- of life in women of reproductive age. *Pak J Med Sci*. 2019; 35(2): 365-70. doi: 10.12669/pjms.35.2.644. PMID: 31086516; PMCID: PMC6500811.
5. Munro MG, Critchley HOD, Fraser IS. The two FIGO systems for normal and abnormal uterine bleeding symptoms and classification of causes of abnormal uterine bleeding in the reproductive years. *Int J Gynaecol Obstet*. 2018; 143(3): 393-08. doi: 10.1002/ijgo.12666.
6. Achanna KS, Nanda J. Evaluation and management of abnormal uterine bleeding. *Med J Malaysia*. 2022 May;77(3):374-383. PMID: 35638495.
7. Marnach ML, Laughlin-Tommaso SK. Evaluation and Management of Abnormal Uterine Bleeding. *Mayo Clin Proc*. 2019; 94(2): 326-35. doi: 10.1016/j.mayocp.2018.12.012. PMID: 30711128.
8. Wouk N, Helton M. Abnormal Uterine Bleeding in Premenopausal Women. *Am Fam Physician*. 2019; 99(7): 435-43. PMID: 30932448.
9. Soisalo p, et al. Hysterectomy Provides Benefit in Health-Related Quality of Life: A 10-Year Follow-up Study. *J Minim Invasive Gynecol*. 2020; 27(4): 868-74. doi: 10.1016/j.jmig.2019.08.009. Epub 2019 Aug 9. PMID: 31404711.
10. Vijayaraghavan A Sr, Jadhav C, Pradeep B, Bindu H, Kumaran S. A Histopathological Study of Endometrial Biopsy Samples in Abnormal Uterine Bleeding. *Cureus*. 2022; 14(11): e31264. doi: 10.7759/cureus.31264. PMID: 36505162; PMCID: PMC9731800.
11. Sharma R, Mishra P, Kumar N, Srivastava P. Histomorphological spectrum of endometrial lesion in women presenting with abnormal uterine bleeding: a 3-year study at a tertiary care center. *Trop J Pathol Microbiol*. 2018; 4: 525-531. [Google Scholar]
12. Husain S, Al Hammad RS, Alduhaysh AK, AlBatly MM, Alrikabi A. Pathological spectrum of endometrial biopsies in Saudi women with abnormal uterine bleeding: A retrospective study of 13-years. *Saudi Med J*. 2021; 42(3): 270-279. doi: 10.15537/smj.2021.42.3.20200814.
13. Chapron C, et al. Diagnosing adenomyosis: an integrated clinical and imaging approach. *Hum Reprod Update*. 2020 Apr 15;26(3):392-411. doi: 10.1093/humupd/dmz049.
14. Ansari A, Urooj U. Study of causes behind abnormal uterine bleeding according to PALM- COEIN classification at a tertiary care hospital. *J Pak Med Assoc*. 2020; 70(1): 154-157. doi: 10.5455/JPMA.2749. PMID: 31954043.
15. Lasmar RB, Lasmar BP. The role of leiomyomas in the genesis of abnormal uterine bleeding (AUB). *Best Pract Res Clin Obstet Gynaecol*. 2017; 40: 82-8. doi: 10.1016/j.bpobgyn.2016.09.008.
16. Clarke MA, Long BJ, Del Mar Morillo A, Arbyn M, Bakkum-Gomez JN, Wentzensen N. Association of Endometrial Cancer Risk With Postmenopausal Bleeding in Women: A Systematic Review and Meta-analysis. *JAMA Intern Med*. 2018; 178(9): 1210-22. doi: 10.1001/jamainternmed.2018.2820.
17. Soja M, Masternak M, Piwowarczyk I, Janas Ł, Szyłto K, Nowak M. Analysis of the results of invasive diagnostic procedures in patients referred to gynecologic department due to abnormal uterine bleeding. *Prz Menopauzalny*. 2020 Dec;19(4):155-159. doi: 10.5114/pm.2020.101942. Epub 2021 Jan 7.
18. Sobczuk K, Sobczuk A. New classification system of endometrial hyperplasia WHO 2014 and its clinical implications. *Prz Menopauzalny*. 2017; 16(3): 107-11. doi: 10.5114/pm.2017.70589. Epub 2017 Oct 12.
19. Manga SM, et al. Pathology findings among women with alterations in uterine bleeding patterns in cameroon. *Gynecol Oncol Rep*. 2021; 37: 100821. doi: 10.1016/j.gore.2021.100821.
20. Vani BS, Vani R, Jijiya Bai P. Histopathological evaluation of endometrial biopsies and curettings in abnormal uterine bleeding. *Tropical journal of pathology and microbiology*. 2019; 5(4): 190-7.
21. Rotenberg O, Goldberg GL. The significance of "atrophic endometrium" in women with postmenopausal bleeding. *Arch Gynecol Obstet*. 2022; 306(3): 579-83. doi: 10.1007/s00404-022-06540-1.
22. Kimura F, et al. Chronic endometritis and its effect on reproduction. *J Obstet Gynaecol Res*. 2019; 45(5): 951-60. doi: 10.1111/jog.13937. Epub 2019 Mar 6.