

# Outcome of Vertical Skeletal Pattern in the Buccal Corridor Area Show during Posed Smile

FASILA RASHID<sup>1</sup>, AMNA BILAL<sup>2</sup>, NAMRAH BASHIR<sup>3</sup>, RASHID HASSAN<sup>4</sup>

<sup>1</sup>Orthodontist, Dento Scope Dental Practice, Rawalpindi

<sup>2</sup>General Dentist & Chief Operating Officer,

<sup>3</sup>Oral Pathology, National University of Medical Sciences, Rawalpindi

<sup>4</sup>Professor, DentoScope Institute of Advanced Dentistry Rawalpindi

Correspondence Dr. Amna Bilal, E-mail: [amna0795@yahoo.com](mailto:amna0795@yahoo.com) Cell: 0323-5800081

## ABSTRACT

**Aim:** To determine link between a patient's buccal relationship and vertical skeletal corridor region display during a posed grin.

**Study design:** Descriptive study.

**Place and duration of study:** Department of Orthodontic, Ayub Dental College from 1<sup>st</sup> July 2022 to 31<sup>st</sup> December 2022.

**Methodology:** One hundred and seventy patients with normal, additional and insignificant buccal corridors were enrolled. The patient's Frankfort Horizontal plane parallel to the floor, their lips relaxed, and their teeth in centric occlusion, lateral cephalograms were obtained.

**Results:** The measurement of the buccal corridor area visible during a frontal grin varies from 0 mm to 4.50mm. The average size of the buccal corridor was  $1.799 \pm 0.9904$  mm. The ratio of lower anterior facial height towards total anterior facial height ranged from 48° to 67° with mean anterior facial height was  $45.246 \pm 2.48$ .

**Conclusion:** Lower anterior facial height has a substantial impact on how much of the buccal corridor region shows during posed smiles, and a rise in ratio causes less buccal corridor area to display.

**Keywords:** Inter-commissure width, Inter-pre-molar width, Inter-pupillary distance

## INTRODUCTION

Good soft tissues provide a face equilibrium and desirable<sup>1</sup>. The phenomenon known as beauty causes people to feel good when they see perception of balance<sup>2</sup>. Several important factors contribute to facial beauty, including proportional relationships between the hard and soft tissues, balanced skeletal bases, and harmonious soft tissues. In clinical orthodontics, the resurgence of the soft tissue paradigm has made creating and analysing smiles essential components of treatment planning. In conclusion, a person's face beauty is significantly influenced by their grin. The universally polite welcome across all cultures is a smile<sup>1</sup>.

A large, appealing grin facilitates the patient's quick psychological integration into the society.<sup>3</sup> It is said out of enjoyment, emotive pact, amusement, a kind gesture and to demonstrate sympathy. The significance of facial and physical charm wherein the smile plays a significant part has been examined and linked to social interactions, voting and jury judgements, first impressions, susceptibility to peer acceptance, and job recruiting decisions<sup>4</sup>.

People's opinions of how attractive smiles are have been impacted by a variety of circumstances, including gender, age, and money. There are two sorts of smiles: posed and unposed; this study only takes into account posed smiles because they can be replicated. A posed smile, often known as the social smile, is one that a person voluntarily employs when posing for a picture or in social situations. Micro aesthetics is a subfield of diagnosis during the frontal orthodontic patient assessment.<sup>5</sup> It comprises of the framework for smiling, the gingival display when smiling, the exhibition of the incisors, and the display of the buccal corridor area. Numerous characteristics, such as consonance in a grin, adequate incisal show when smiling, harmonious gingival scaffolding, colourful gingiva, limited buccal corridors, and so on, are believed to boost the agreeable impact of a smile or to make it more beautiful. A grin is made perfect by all of these.<sup>6</sup> The findings of several researches that have been undertaken support the facts listed above. Both men and women like having less buccal passages as an aesthetic characteristic. The buccal corridor area appears differently during posed grins depending on a variety of hard and soft tissue traits, including inter-premolar width, lower

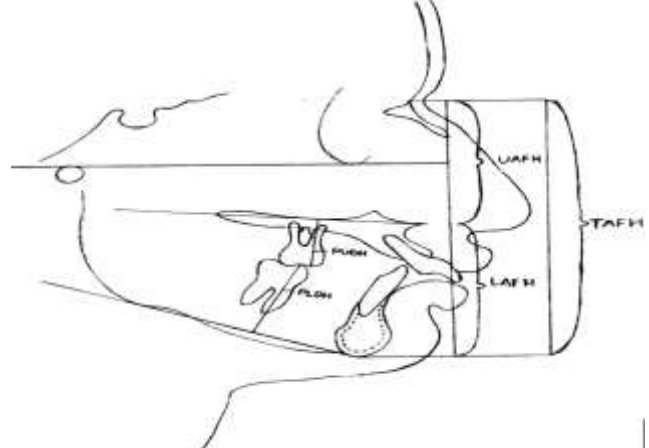
anterior face height ratio, arch form, inter-commissure width and lip length, among others<sup>5</sup>.

This study set out to determine the link between a patient's buccal relationship and vertical skeletal corridor region display during a posed grin. This can help orthodontists arrange an orthodontic case while considering the cosmetic effects of the vertical skeletal pattern on the region visible in the buccal corridor.

## MATERIALS AND METHODS

Non-probability sequential sampling was employed to choose the participants for the study while observance in mind the inclusion criteria (total = 170, 70 men & 100 women subjects with normal, additional and insignificant buccal corridors). The research encompassed male and female participants of any age pursuing orthodontic treatment for any type of malocclusions who had entire permanent dentitions, no additional or missing teeth (apart from wisdom teeth), symmetrical arch forms, and normal upper lip length. Individuals who had significant malocclusions or cant of the maxillary plane, temporomandibular joint problems, cleft palate & lip or any other condition, had orthognathic surgery, or who were having any surgical periodontal procedure were excluded from the research.

Fig 1: Ratio of lower face height to total anterior face height



Received on 10-10-2022

Accepted on 23-03-2023

With the patient's Frankfort Horizontal plane parallel to the floor, their lips relaxed, and their teeth in centric occlusion, lateral cephalograms were obtained. A typical lit view box was used to draw radiographs on 8x10 inch translucent acetate tracing paper using a lead pencil (# 2 12 HB). In order to determine the patient's vertical skeletal connection, the ratio between the lower anterior facial height and the overall anterior facial height was noted on the patient's data form. By using the Pearson correlation coefficient, this ratio was connected to whether the buccal corridor showed more or less during the posed grin (Fig. 1). Data were examined using SPSS-24. We employed descriptive statistics. The inter-commissure width, inter-premolar width, and vertical skeletal connection with the buccal corridor area were all assessed using the Pearson correlation coefficient. The range of the r value was between -1.0 and +1.0.

Tab 1: Descriptive statistics of the patients (n=170)

Variable	Minimum	Maximum	Mean	SD
Buccal corridor area (mm on frontal smile)	0.00	4.50	1.80	0.99
Ratio of lower anterior facial height to total anterior facial height (degrees)	48.0°	67°	45.246°	2.48°

Table 2: Buccal corridor area show (mm on frontal smile)

Ratio of lower anterior facial height to total anterior facial height (degrees)	No.	Mean±SD	P value
< 67°	13	2.16±0.50	0.015
Normal	80	1.70±0.81	
> 71°	77	1.40±1.03	

## DISCUSSION

The study's pre-treatment sample was chosen because it represented the usual orthodontic patients that needed treatment. These participants differed substantially because a pre-treatment sample was employed. The variety of smiles and dentofacial differences in the sample made it possible to correlate the hard tissue features to the resultant grin configurations over a wide range of smiles. As the sample was not selected based on gender, there were more female participants in this study. It was already noted the issue list, treatment plans, and goals all include minimising buccal corridor area displayed during posed smiles. A smile is a crucial facial characteristic. Orthodontic therapy has the power to drastically modify it. Many investigations have been conducted to determine the causes of buccal corridor region appear during posed smiles as well as its diagnosis and consequences. It should be reduced as much as possible.<sup>9-11</sup> Based on the ratios of lower anterior facial height to total anterior facial height, 3 groups were formed. Individuals whose lower facial height to total anterior facial height ratio was between 43% and 45% were classified as belonging to the normal group, while those whose ratio was under 43% were categorised as having decreased LAFH, and those whose ratio was over 45% as having increased LAFH<sup>12</sup>.

Our results for the face heights were lower than those from Yang's study<sup>8</sup>, where the mean value was 46.78±6.17°, while McNamara's<sup>13</sup> sample results were slightly higher with a mean value of 59.7±7.5°. Values for the lower anterior face height varied according to how much of the buccal corridor was visible.<sup>11</sup> Nevertheless, they also discovered that the buccal corridor area indicate change was influenced by the vertical skeletal pattern of the lower face rather than the upper facial height, which also affects the overall vertical pattern<sup>12</sup>. One explanation could be its connection to the actions of the lips' muscles, which are restricted to the bottom part of the face. Thus, a longer face has less buccal corridor area display<sup>13</sup>.

In order to standardized the people in the normal anterior facial height group, only subjects whose ratio of lower anterior facial height to total anterior facial height fell inside the sort suggested by research on white American female and male participants were included in this group. In cephalometric studies and measurements, white American standards are still employed as a benchmark.<sup>9</sup> Participants in the other groups were less likely

## RESULTS

The measurement of the buccal corridor area visible during a frontal grin ranged from 0 mm to 4.50 mm. The average size of the buccal corridor was 1.80 mm, with a standard variation of 0.9904 mm. With a mean of 45.246° & a SD of 2.48°, the ratio of lower anterior facial height towards total anterior facial height ranged from 48° to 67° (Table 1).

There was a negative and statistically significant association amongst buccal corridor area display and the ratio of lower anterior face height to total anterior facial height. The ratio of lower anterior face height to total anterior facial height and the buccal corridor area display were significantly correlated (P-value 0.05). The results show that as the ratio of lower anterior face height to total anterior facial height upsurges, the mean buccal corridor area declines (Table 2).

to have increased lower anterior facial heights when it came to sample distribution according to LAFH. If the lower anterior face height is lower than normal, extrusive or intrusive mechanics can be used to change it.<sup>13</sup> This result should be taken into account while dealing preparation and choosing the types of mechanics and appliances<sup>14</sup>.

## CONCLUSION

Lower anterior facial height has a substantial impact on how much of the buccal corridor region shows during posed smiles, and a rise in ratio causes less buccal corridor area to display. After orthodontic treatment, the buccal corridor area displayed in posed smiles may be brought into the normal range by adjusting lower anterior face height, which eventually improves the facial profile.

**Conflict of interest:** Nil

## REFERENCES

- Fan Z, Zhang Q, Jiang Y, Qin Q, Huang S, Guo J. Mandibular retromolar space in adults with different sagittal skeletal patterns: Cone-beam computed tomography analysis. *Angle Orthodontist* 2022;92(5):606-12.
- Marghalani HY, Guan G, Hyun P, Tabbaa S, Linjawi AI, Al-Jewair T. Relationship between mandibular symphysis dimensions and skeletal pattern in adults. *Folia Morphologica* 2022; 81(2): 464-71.
- Moon CH, Park HK, Nam JS, Im JS, Baek SH. Relationship between vertical skeletal pattern and success rate of orthodontic mini-implants. *Am J Orthod Dentofac Orthop* 2010;138(1):51-7.
- Evangelista K, Teodoro AB, Bianchi J, Cevidanes LH, de Oliveira Ruellas AC, Silva MA, Valladares-Neto J. Prevalence of mandibular asymmetry in different skeletal sagittal patterns: a systematic review. *Angle Orthodontist* 2022;92(1):118-26.
- Celikoglu M, Bayram M, Sekerci AE, Buyuk SK, Toy E. Comparison of pharyngeal airway volume among different vertical skeletal patterns: a cone-beam computed tomography study. *Angle Orthodontist* 2014;84(5):782-7.
- Mills JR. The effect of functional appliances on the skeletal pattern. *Br J Orthod* 1991; 18(4): 267-75.
- Cho HN, Yoon HJ, Park JH, Park YG, Kim SJ. Effect of extraction treatment on upper airway dimensions in patients with bimaxillary skeletal protrusion relative to their vertical skeletal pattern. *Korean J Orthod* 2021;51(3):166-78.

8. Yang IH, Nahm DS, Baek SH. Which hard and soft tissue factors relate with the amount of buccal corridor space during smiling?. *Angle Orthodontist* 2008;78(1):5-11.
9. Santander P, Quast A, Olbrisch C, Rose M, Moser N, Schliephake H, Meyer-Marcotty P. Comprehensive 3D analysis of condylar morphology in adults with different skeletal patterns – a cross-sectional study. *Head Face Med* 2020;16(1):1-0.
10. Diwakar R, Bucci R, Kaushik A, Bansal A, Bucci P, Kochhar AS, Spagnuolo G. Three-dimensional assessment of temporomandibular joint morphology and facial asymmetry in individuals with different vertical skeletal growth patterns. *Int J Environmental Res Public Health* 2023;20(2):1437.
11. Davidovitch M, Konstantarakis E, Athanasios V, Sella-Tunis T. Effects of Class II elastics during growth on the functional occlusal plane according to skeletal pattern and extraction vs nonextraction. *Angle Orthodontist* 2023; 93(1): 19-25.
12. Rozzi M, Alesi G, Mucedero M, Cozza P. Dentoskeletal effects of rapid maxillary expander therapy in early mixed dentition patients with different vertical growing patterns without posterior crossbite: a retrospective study. *Am J Orthod Dentofacial Orthop* 2023; 163(3): 319-27.
13. Karandish M, Farmani S, Khademi B, Paknahad M. Evaluation of glenoid fossa morphology in different facial growth patterns: a cone beam computed tomography study. *Dentistry* 2023; 11(1).
14. Chou ST, Tsai PL, Chen SC, Lin SH, Chen CM, Tseng YC. Condylar and ramus volume in asymmetric and symmetric skeletal class III malocclusion: a cone-beam computed tomography study. *J Dental Sci* 2023; 18(1): 175-83.