

Evaluation of Arthroscopic Bankart Repair and Open Latarjet Technique for Treatment of Recurrent Shoulder Dislocation

YOUSAF GUL¹, MUHAMMAD ZUBAIR FAROOQ², INAMULLAH³, MUHAMMAD ASGHAR ESSA², Shafaat Ullah Khan⁴

¹Assistant Professor, DHQ Teaching Hospital/ Gomal Medical College, Dera Ismail Khan

²Assistant Professor, Mufti Mehmood Memorial Teaching Hospital/ Gomal Medical College, Dera Ismail Khan

³Orthopedic Department, DHQ Teaching Hospital, Dera Ismail Khan

⁴Medical Officer, Civil Hospital Thall Hangu KpK

Corresponding author: Yousaf Gul, Email: dr_yousafgul@yahoo.com

ABSTRACT

Background: Arthroscopic Bankart repair and open Latarjet procedures are the most frequent surgical treatments for shoulder instability and recurrent shoulder dislocation.

Objectives: Therefore, we performed research to assess the clinical outcomes and recurrence rate of instability between both Arthroscopic Bankart repair and open Latarjet techniques.

Methods: A cross-sectional study was performed at Lahore General Hospital, Lahore from 2021-23, comprising 74 patients, managed surgically for the condition of recurrent shoulder dislocation. The patients were allocated into two groups viz Group A and B comprising 37 patients in each, who were managed through Arthroscopic Bankart repair and open Latarjet techniques, respectively. Post-operative complications, re-occurrence and success rate were measured in terms of SSV scores.

Results: Average age of patients in Arthroscopic Bankart group was 28.34±5.31 years while in open Latarjet group; it was 29.09±6.19 years. 14 (37.83%) patients of Arthroscopic Bankart repair group revealed recurrent shoulder dislocation, while no such complaint was found in the open Latarjet technique. Twenty-seven patients of Arthroscopic Bankart group showed satisfaction with the procedure and 33 out of 37 patients (89.18%) were satisfied with open Latarjet technique. Patients in open Latarjet technique group showed successful recovery of shoulder dislocation and their SSV was 87.91%, while the patients in Arthroscopic Bankart repair group showed less SSV score of 59.76%.

Conclusion: Open Latarjet group patients had a greater rate of functional satisfaction, while the arthroscopic Bankart repair group showed a trend for more recurrence. Open Latarjet operation had a higher success rate and patients had a better rate of return to previous top-level sports than Arthroscopic Bankart technique.

Keywords: Latarjet; Re-occurrence; Shoulder dislocation; Sports medicine; Surgical complications.

INTRODUCTION

Shoulder dislocation occurs when the head of humerus is removed from the shoulder joint. Shoulder discomfort and instability are chief symptoms. Bankart lesion, rotator cuff tear, Hill-Sachs lesion and axillary nerve smash up are notorious complications. Shoulder dislocations are often caused by falls onto outspread arms or shoulders. Typically, symptoms and X-rays are used to establish a diagnosis. These are categorized as anterior, posterior, inferior, superior, with the majority belonging to the anterior category¹⁻². The anterior dislocation of the shoulder is one of the most common dislocations of all articulations, affecting 2% of populace, with the incidence rate of 23.9 per 100,000 people per annum. Surgical stabilization is the only viable option to treat recurrent shoulder dislocation owed to firm fixation it provides³⁻⁴.

Recurrent episodes of shoulder instability can lead to more severe Bankart lesions, bone abnormalities, and stretching of ligamentous components, compromising joint stability⁵⁻⁶. Shoulder instability is treated with a range of conservative and surgical therapies. Conservative management often entails closure reduction followed by immobilization and physical rehabilitation. While the common surgical options for shoulder instability repair are Arthroscopic Bankart and Latarjet-Bristow procedures⁷⁻⁹.

An arthroscopic Bankart technique is the most widespread surgical treatment for this condition. The torn labrum and inferior glenohumeral ligaments are re-attached to glenoid rim using suture anchors to restore joint's architecture¹⁰⁻¹¹. Up to 40% of individuals who undergo Arthroscopic Bankart surgery may experience recurrence of instability despite surgical intervention¹². While in open Latarjet maneuver, coracoid of scapulae and conjoined tendon are transplanted non-anatomically through subscapularis muscle to glenoid's neck and has great success rate and chances of recurrence array from 0-10%¹²⁻¹⁴.

There are very few comparison studies comparing these methods, and there is scant evidence examining the outcome and effects of either procedure. Therefore, to assess clinical outcomes of Arthroscopic Bankart repair versus open Latarjet maneuver for treating recurrent shoulder dislocation, this research was performed.

MATERIAL AND METHODS

A cross-sectional study was performed at Lahore General Hospital, Lahore during 2021-23, comprising 74 patients, managed surgically for condition of recurrent shoulder dislocation. The patients were allocated into Group A and B comprising 37 patients in each, who were managed with Arthroscopic Bankart repair and open Latarjet techniques, respectively.

The patients' history (occupation, sports, initial trauma, drug abuse, preoperative dislocations number, seizures, etc), patient's age, gender, first Arthroscopic Bankart procedure, reoccurrence, repeat surgery and medical findings, were noted. Radiographs of shoulders were taken. Preoperative data of patients including demographic information, history, kind of surgical procedure and postoperative data including clinical outcomes and complications, was also recorded and analyzed statistically.

Inclusion criterion laid for study comprised the patients with recurrent shoulder dislocation treated by either technique. First-time dislocations, superior labral lesions, multidirectional instability, preceding shoulder surgery, neuromuscular disorders or epilepsy were the exclusion criteria.

Radiographs, MRIs, and CT scans were performed on all patients as part of the standard preoperative imaging protocol. Soft tissues together with Bankart lesions were evaluated using MRI, while skeletal status (Bankart and Hill-Sachs lesions) was evaluated using CT scans. During Arthroscopic Bankart repair, the patients were positioned in lateral decubitus with general anesthesia and an interscalene block. Intra-articular observations being documented and IGHL and antero-inferior labrum were moved until subscapular muscle fibers were perceptible. Three weeks later, arm was placed in a sling once the wounds were closed¹⁵.

In open Latarjet technique, the patients were positioned in a beach-chair position with inter-scapular pillow. Coracoid grafts was preset using two corticocancellous screws measuring 3.5 mm screws measuring 4 mm with washer and were placed parallel to glenoid surface. Subsequent to achieving appropriate fixation, the coracoacromial ligament was regularly sutured to capsule, subscapularis muscle was restored then incision was layered sutured.

However, precautions were taken to protect coraco-clavicular ligament⁴.

For four weeks, a shoulder immobilizer was used for therapy. Immediately following surgery, passive forward flexion exercises and pendulum exercises were initiated. At three months, all directions active range of motion was recommended.

The Ethical Review Committee of Lahore General Hospital granted ethical approval to commence study and written informed permission was acquired from study patients.

Gathered data was statistically analyzed using Chi-Square tests at SPSS software version 20 at significance level at p-value of 0.05.

RESULTS

There were no statistically significant differences in demographics of patients between the Arthroscopic Bankart and open Latarjet groups, according to the data. The study comprised a total of 74 individuals, with 37 participants in each group. The average age of patients in Arthroscopic Bankart repair group was 28.34+5.31 years while in open Latarjet maneuver group it was 29.09+6.19 years. In Arthroscopic Bankart repair group, there were 34 male patients and 3 female patients; in open Latarjet maneuver group, there were 36 male patients and one female patient. In Arthroscopic Bankart repair group, 31 (83.78%) patients had right-sided dislocations, while in open Latarjet maneuver group, 29 (78.37%) patients had right-sided dislocations and 8 (21.62%) had left-sided dislocations. In Arthroscopic Bankart repair and open Latarjet technique groups, 17 (45.94%) and 14 (37.83%) patients were associated with sports and athletes, respectively. Mean dislocations number in Arthroscopic Bankart repair group be

7.19+2.98 and in open Latarjet technique group it was 9.18+3.01 (Table 1).

The assessment of clinical outcomes after both Arthroscopic Bankart repair and open Latarjet surgical maneuvers revealed significant variations in re-occurrence (p<0.05) and 14 (37.83%) patients of Arthroscopic Bankart group (Group A) revealed recurrent shoulder dislocation, while no such complaint was found in open Latarjet technique treated patients (Group B). Average surgery time of Group A and B was 69.87+17.19 and 96.18+15.78 minutes, respectively. An average number of follow-up visits was 7.76+2.45 in Arthroscopic Bankart repair and 3.2+1.6 in open Latarjet maneuver groups. Twenty-seven patients of Arthroscopic Bankart repair group showed satisfaction with the procedure and 33 out of 37 patients (89.18%) were satisfied with open Latarjet technique. However, postoperative complications were found in both techniques i.e. 18.91% in Arthroscopic Bankart and 21.62% in open Latarjet group (Table 2). The common post-op complications observed were sepsis, deep wound infection, mobility problems in shoulder, recurrent instability, and thrombosis with the number of patients of 1, 0, 2, 3, 1 in Arthroscopic Bankart repair group and 3, 1, 0, 0, 4 in open Latarjet technique group, respectively, while no mortality was observed in any treatment group, during the study period (Figure 1).

The assessment of procedure success and shoulder recovery was evaluated using SSV (Subjective Shoulder Score) scoring system measured in 1-100%. The patients treated with open Latarjet maneuver group showed successful recovery of shoulder dislocation and their SSV was 87.91%, while the patients in Arthroscopic Bankart repair group showed less SSV score of 59.76% (Figure 2).

Table 1: Analysis of demographic values of the study groups

S. No	Demographic variable	Group A (Arthroscopic Bankart Repair Group)	Group B (Open Latarjet Technique)	χ ²	p-value
1	No. of patients (n)	37	37	-	-
2	Age (Mean+SD) Years	28.34 + 5.31	29.09 + 6.19	-	-
3	Gender (n)				
	Male	34	36	0	0.9963
	Female	3	1	0.2124	0.6449
4	Aspect (n)				
	Right	31	29	0.0003	0.9855
	Left	6	8	0.0395	0.8424
5	Sports and athletes (n)	17	14	0.0569	0.8115
6	No. of dislocations (n)	7.19 + 2.98	9.18 + 3.01	0.0104	0.9186

Table 2: Assessment of clinical outcomes after the surgical procedures

S. No	Clinical outcome	Group A	Group B	χ ²	p-value
1	Surgery duration (minutes) Mean+SD	69.87 + 17.19	96.18 + 15.78	-	-
2	Re-occurrence (n)	14 (37.83%)	0 (0%)	7.882	0.0049*
3	Follow-up visits (n) Mean+SD	7.76 + 2.45	3.2 + 1.6	-	-
4	Patients satisfaction n (%)	27 (72.97)	33 (89.18)	0.1618	0.6874
5	Complications n (%)	7 (18.91)	8 (21.62)	0.0023	0.9619

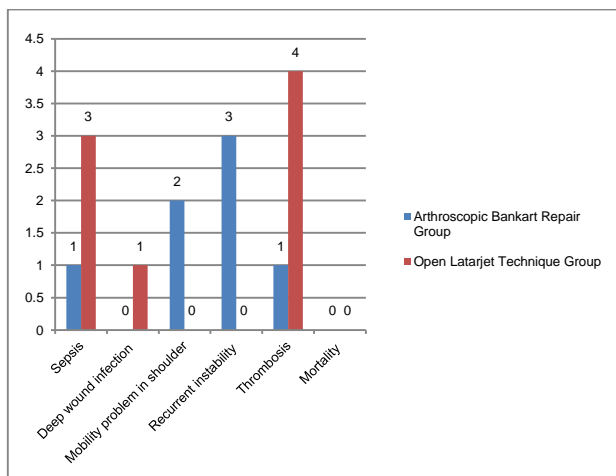


Figure 1: Post-operative complications and their comparative incidence in the study groups

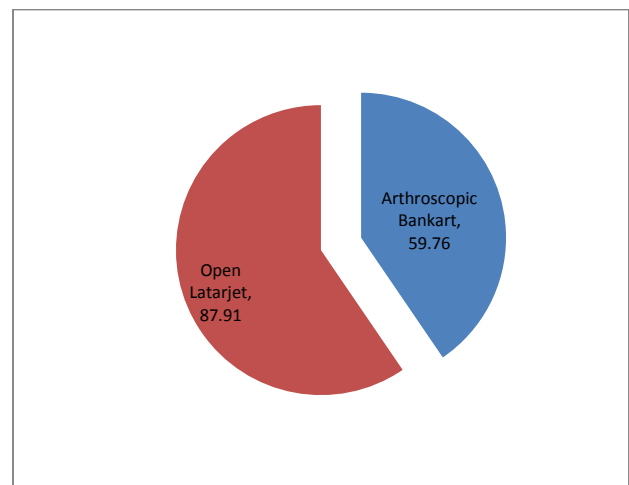


Figure 2: Assessment of procedure success at SSV scoring system (%)

DISCUSSION

The primary finding of our research revealed that Arthroscopic Bankart repair procedure was considerably more related to re-dislocations and requirement for further revision surgery than open Latarjet procedure. Open Latarjet procedure being more effective, resulted in greater patient satisfaction, and was related to a higher rate of patients returning to their previous level of athletic performance and shoulder mobility. Patients in open Latarjet maneuver group revealed privileged SSV scores and none of the patients showed reoccurrence and recurrent shoulder dislocation.

A randomized controlled experiment with 2-year follow-up comparing success rates of Arthroscopic Bankart repair and open Latarjet operation in treatment of traumatic shoulder instability in 122 male youth largely confirmed our findings. In the trial, it was found that Arthroscopic Bankart surgery carried a greater risk of short-term postoperative re-dislocations than open Latarjet surgery in therapy of traumatic antero-inferior instability in boys. Ten (21%) patients in group B and one (2%) in group L had re-dislocations, $p=0.006$. At follow-up, one person (9%) in group B and five patients (56%) in group L returned to their original level of competition ($p=0.004$)¹⁵. In a meta-analysis of 795 shoulders, open Latarjet surgery was associated with a much-reduced menace of recurrence than Arthroscopic Bankart *modus operandi*; recurrence was roughly twofold higher with the Arthroscopic Bankart repair¹⁶.

According to the study, recurrence of instability necessitating surgical intervention was statistically considerably more common following Arthroscopic Bankart revision than open Latarjet. Both WOSI index and SSV score demonstrated statistically significant differences in favor of the revised open Latarjet method^{12,17}. Estimated re-dislocation rate was 7.7% in Arthroscopic Bankart repair and 2.7% in open Latarjet, with a statistically significant difference between these two ($p<0.001$). The prevalence of subjective instability and radiographic arthritis was high across all groups, with no statistically significant differences. Estimated rates of complications were substantially greater for open Latarjet repair (9.4%) than for Arthroscopic Bankart (0%; $p=0.002$)¹⁸.

According to another study, there were non-significant clinical results ($p<0.05$) of two groups. The open Latarjet method yielded greater functional satisfaction. Arthroscopic Bankart maintenance was much more expensive than open Latarjet maintenance. Recurrence occurred in 03 patients in Arthroscopic Bankart repair and none in open Latarjet group. Both operations resulted in satisfactory clinical outcomes. Yet, open Latarjet group had a better percentage of functional satisfaction and reduced operating costs, whereas the arthroscopic Bankart group had a trend toward higher recurrence^{4,19}. Latarjet-Bristow was related to higher frequency of significant adverse events than Arthroscopic Bankart, according to research^{5,20}. A study found that both arthroscopic Bankart repair and open Latarjet treatments yielded excellent functional outcomes in managing recurrent shoulder dislocation. In Arthroscopic Bankart repair, a shorter postoperative hospital stay was seen^{21,22}.

CONCLUSION

Both surgeries resulted in favorable clinical outcomes. Open Latarjet surgical technique presented greater rate of functional satisfaction, while the arthroscopic Bankart repair group showed trend for higher recurrence. Even though Arthroscopic Bankart repair was less invasive, had lower postoperative complications, minimal hospital stay and was more aesthetically pleasing than open Latarjet technique, these results indicated that open Latarjet operation may still be a higher priority. In managing recurrent shoulder dislocation, Arthroscopic Bankart maneuver posed greater hazard for short-term postoperative re-dislocations and requirement for subsequent surgery than open Latarjet procedure. Open Latarjet surgery resulted in a better rate of return to previous

top-level sports than Arthroscopic Bankart technique. The open Latarjet method had a much lower rate of re-dislocation than the arthroscopic Bankart repair. Future research is also required to study the clinical significance and functional consequences of dislocation arthropathy.

REFERENCES

- Bonz J, Tinloy B. Emergency department evaluation and treatment of the shoulder and humerus. *Emerg Med Clin North Am.* 2015 May;33(2):297-310.
- Sherchan B, Rai S, Tamang N, Dhungana S, Sharma LK, Marasini RP, Singh JL, Khanal K. Outcomes of single bundle arthroscopic anterior cruciate ligament reconstruction in a limited resource setting. *J ISAKOS.* 2021 Jul;6(4):187-192.
- Sofu H, Gürsu S, Koçkara N, Oner A, Issin A, Camurcu Y. Recurrent anterior shoulder instability: Review of the literature and current concepts. *World J Clin Cases.* 2014 Nov 16;2(11):676-82.
- Rai S, Tamang N, Sharma LK, Marasini RP, Singh JL, Khanal K, Ghimire KCM, Sherchan B. Comparative study of arthroscopic Bankart repair versus open Latarjet procedure for recurrent shoulder dislocation. *Journal of International Medical Research.* 2021 Apr;49(4):3000605211007328.
- Eberlin CT, Varady NH, Kucharik MP, Naessig SA, Best MJ, Martin SD. Comparison of perioperative complications following surgical treatment of shoulder instability. *JSES International.* 2022;6:355-361.
- Huxel Bliven KC, Parr GP. Outcomes of the Latarjet procedure compared with Bankart repair for recurrent traumatic anterior shoulder instability. *J Athletic Train* 2018;53:181-3.
- Balg F, Boileau P. The instability severity index score. A simple pre-operative score to select patients for arthroscopic or open shoulder stabilisation. *J Bone Joint Surg Br* 2021;89:1470-7.
- Laboute E, Hoffmann R, Bealu A, Ucay O, Verhaeghe E. Recurrence and return to sport after surgery for shoulder instability: arthroscopic Bankart versus Latarjet procedure. *JSES Int* 2021;5:609-15.
- Mancini MR, Levasseur MR, Hawthorne BC, Marrero DE, Mazzocca AD. Venous thromboembolism complications in shoulder surgery: current concepts. *J ISAKOS* 2021;6:283-9.
- Bessi_ere C, Trojani C, Carles M, Mehta SS, Boileau P. The open Latarjet procedure is more reliable in terms of shoulder stability than arthroscopic Bankart repair. *Clin Orthop Relat Res* 2014;472:2345e51.
- Cole BJ, Romeo AA. Arthroscopic shoulder stabilization with suture anchors: technique, technology, and pitfalls. *Clin Orthop Relat Res* 2001;(390):17e30.
- Elamo S, Selanne L, Lehtimäki K, Kukkonen J, Hurme S, Kauko T, Aarimaa V. Bankart versus Latarjet operation as a revision procedure after a failed arthroscopic Bankart repair. *JSES International.* 2020;4:292-296.
- Latarjet M. [Apropos d'traitements des luxations r_écidivantes de l'_épaule Treatment of recurrent dislocation of the shoulder]. *Lyon Chir* 1954;49:994e7.
- Edwards TB, Walch G. The Latarjet procedure for recurrent anterior shoulder instability: rationale and technique. *Oper Tech Sports Med* 2012;20:57e64.
- Kukkonen J, Elamo S, Flinkkila T, Paloneva J, Mantysaari M, Joukainen A, Lehtinen J, Lepola V, Holstila M, Kauko T, Aarimaa V. Arthroscopic Bankart versus open Latarjet as a primary operative treatment for traumatic antero-inferior instability in young males: a randomised controlled trial with 2-year follow-up. *Br J Sports Med* 2022;56:327-333.
- An VVG, Sivakumar BS, Phan K, et al. A systematic review and meta-analysis of clinical and patient-reported outcomes following two procedures for recurrent traumatic anterior instability of the shoulder: Latarjet procedure vs. Bankart repair. *J Shoulder Elbow Surg* 2016;25:853-63.
- Harris DJ, Jefferson CB, Mark PC, Faucett SC, Dhawan A. Research pearls: the significance of statistics and perils of pooling. Part 1: clinical versus statistical significance. *Arthroscopy* 2017;33:1102e12.
- Rollick NC, Ono Y, Kurji HM, Nelson AA, Boorman RS, Thornton GM, Lo IK. Long-term outcomes of the Bankart and Latarjet repairs: a systematic review. *Journal of Sports Medicine.* 2017;8:97-105.
- Thomazeau H, Courage O, Barth J, et al. Can we improve the indication for Bankart arthroscopic repair? A preliminary clinical study using the ISIS score. *Orthop Traumatol Surg Res* 2010; 96: S77-S83.
- Varady N, Ameen B, Chen A. Is delayed time to surgery associated with increased short-term complications in patients with pathologic hip fractures? *Clin orthopaedics Relat Res* 2020;478:607-15.
- Nakagawa S, Mae T, Sato S, Okimura S, Kuroda M. Risk factors for the postoperative recurrence of instability after arthroscopic Bankart repair in athletes. *Orthop J Sports Med.* 2017;5(9):1-9.
- Bavarel L, Colle PE, Saffarini M, Anthony Odri G, J. B. Open Latarjet procedures produce better outcomes in competitive athletes compared with recreational athletes: a clinical comparative study of 106 athletes aged under 30 years. *Am J Sports Med.* 2018 46(6):1408-15.