

## ORIGINAL ARTICLE

**Evaluation of Clinical Implications of Renal Vessel Morphology during Renal Surgeries**MOTASIM BILLAH<sup>1</sup>, ABBAS ALI RAZA<sup>2</sup>, AHMAD FARZAD QURESHI<sup>3</sup>, SABEEN AKHTAR<sup>4</sup><sup>1</sup>Assistant Professor Anatomy, Gajju Khan Medical College, Swabi<sup>2</sup>Senior Registrar General Surgery, Bacha Khan Medical College, Mardan<sup>3</sup>Assistant Professor Anatomy, Services Institute of Medical Sciences, Lahore<sup>4</sup>Demonstrator Anatomy department, Multan Medical & Dental College, MultanCorresponding author: Abbas Ali Raza, Email: [mad.eyes001@gmail.com](mailto:mad.eyes001@gmail.com)**ABSTRACT****Objective:** Aim of this research to examine renal vessels and their morphologies as well as their clinical consequences during renal surgery.**Study Design:** Cross-sectional study**Place and Duration:** Anatomy department of Bacha Khan Medical Complex, Mardan and Multan Medical & Dental College Multan during the period from April 2022 to September 2022.**Methods:** There were 90 cases of both genders presented in this study. Included patients were aged between 20-80 years. With suspected abdominal diseases, patients were referred for abdominal CECT examinations. In contrast-enhanced MDCT images of the Abdomen, the renal arteries were examined for their normal structure and any abnormalities. SPSS 21.0 was used to analyze complete data.**Results:** Males were higher in numbers 61 (67.8%) than females. Mean age of the patients was 51.3±8.43 years and mean BMI 22.4±8.42 kg/m<sup>2</sup>. We found frequency of anatomical variations of the renal vessel in 62 (68.9%) cases. Frequency of variations of the renal artery was 47 (52.2%). Among 47 cases, supplementary renal artery was found in 41 (45.6%) cases. Early bifurcation of renal artery in 15 (16.7%). In 11 patients on the right side, 12 patients on the left side, and 3 individuals on both sides, an earlier branching of the renal artery was found. The right side was more often affected by renal vein variations, with 25 (27.8%) patients having late renal vein confluence and 6 (6.7%) patients having additional renal veins. Patients with late renal vein confluence (3.3%) and retroaortic vein (3.3%) were seen on the left side.**Conclusion:** Our findings in this research show renal artery alterations are common. Endovascular, laparoscopic, and urological procedures benefit from morphological examination of the renal vessels.**Keywords:** Abdominal disease, Renal Artery, Conventional Angiography, Anatomical Variations**INTRODUCTION**

In order to execute any sort of renal surgery, the morphology and changes in the renal vascular structures must be understood prior to any kidney transplantation or interventional radiologic treatments such as the treatment of renal artery stenosis. Open or endovascular surgery to repair abdominal aortic aneurysms must also consider renal vascular alterations [1, 2] before proceeding. Even while conventional angiography is the gold standard approach for inspecting vascular structures, it is an intrusive operation and does not provide sufficient information to evaluate renal vein changes in depth [3, 4]. Using a technique known as multidetector computed tomography (MDCT), one may see not just the kidney's arteries and veins but also their whole vascular system as a whole.[5]

Between T12 and L2, the renal artery's origin may be found. For example, it is possible that an atypical artery may arise from the contralateral renal artery or from the superior or inferior mesenteric, as well as the right colic and/or spermatic vessels. There are several various labels for such arteries, including "aberrant," "abnormal," "accessory," "added," "extra," "supernumerary," and "supplementary," among others. These variations are referred to in the literature as "many" to emphasize the importance of different vascular entities [6,7]. Twenty to thirty percent of people have multiple renal arteries (MRAs) (two in 22 percent, three in 1-2 percent, and four in 0.1 percent) [8]. An embryological explanation for the existence of MRA was provided by Felix et al. [9].

According to Sampaio and Passos [8], there are four renal arteries that penetrate the kidneys in different ways. They are the extra-hilar artery, which originates from an extra-hilar renal artery from the abdominal aorta; the Hilar and Extra-Hilar arteries; and the Superior and Inferior Polar arteries, which originate from the aorta and penetrate the kidneys in different ways.

The nomenclature they used for identifying renal arteries has been used in subsequent studies [10,11]. The presence of several branches is more common in renal arteries than in any other artery of comparable size. Thanks to technological advancements, it is

now simpler to discover and identify arteries, veins, and renal parenchyma through CT and MRI reconstructed images and images of their parenchyma. An MRA-based procedure may be used to prevent surgical complications and the consequent infarction of the targeted segment. As a consequence, surgery planning has become simpler and patient outcomes have improved. [12]

By using contrast-enhanced MDCT, our research seeks to examine the renal vessels' shape, changes, and clinical consequences.

**MATERIAL AND METHODS**

This cross-sectional study was conducted at the Department of Anatomy, Bacha Khan Medical Complex Mardan and Multan Medical & Dental College, Multan during the period from April 2022 to September 2022.

The study consisted of 90 patients. Informed agreement was obtained prior to recording demographics such as gender and BMI for all enrolled patients. Those with a history of kidney illness, kidney transplantation, or kidney donation were ruled out of the running for the role of donor.

Patients between the ages of 20 and 80 were included in the study. CECT abdominal exams were recommended for individuals with suspected abdominal disorders. The normal anatomy and any anomalies of the renal arteries were investigated in contrast-enhanced MDCT images of the abdomen. IBM SPSS Statistics 21.0 Windows was used to perform the analysis in this paper. For categorical variables, the findings are shown in percentages. Analysis of renal arterial types and laterality was conducted using chi-square testing with continuity correction. – A statistically significant difference was defined as one with a p-value lower than 0.05.

**RESULTS**

In current study, males were higher in numbers 61 (67.8%) than females 29 (32.2%).(fig 1)

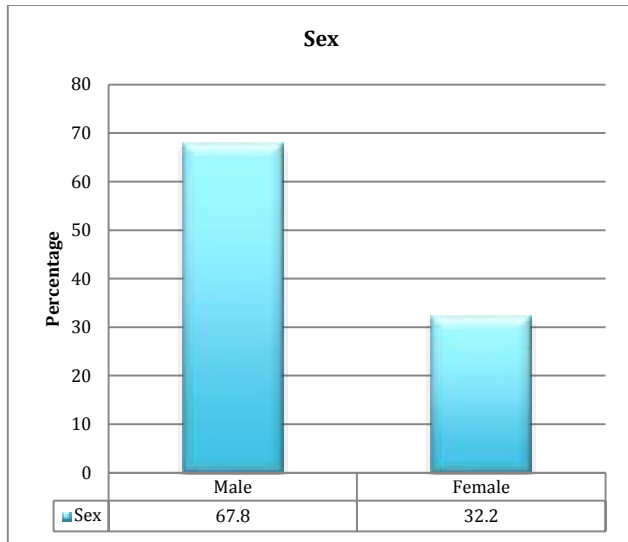


Figure-1: Distribution of gender among enrolled cases

Mean age of the patients was  $51.3 \pm 8.43$  years and mean BMI  $22.4 \pm 8.42$  kg/m<sup>2</sup>. Among 90 cases, 50 (55.6%) were married. 43 (47.8%) cases were from urban areas and 37 (41.1%) patients were educated.(table 1)

Table-1: Demographic details of enrolled cases

Variables	Frequency	Percentage
Mean age (years)	51.3±8.43	
Mean BMI (kg/m <sup>2</sup> )	22.4±8.42	
<b>Marital status</b>		
Yes	50	55.6
No	40	44.4
<b>Residency</b>		
Urban	43	47.8
Rural	47	52.2
<b>Education status</b>		
Literate	37	41.1
illiterate	53	58.9

We found frequency of anatomical variations of the renal vessel in 62 (68.9%) cases. Frequency of variations of the renal artery was 47 (52.2%). Among 47 cases, supplementary renal artery was found in 41 (45.6%) cases. Early bifurcation of renal artery found in 15 (16.7%). In 11 patients on the right side, 12 patients on the left side, and 3 individuals on both sides, an earlier branching of the renal artery was found. (table 2)

Table-2: Distribution of renal variations among enrolled cases

Variables	Frequency	Percentage
<b>Anatomical Variations</b>		
Yes	62	68.9
No	28	31.1
<b>Variations of Renal Artery</b>		
Yes	47	52.2
No	43	47.8
<b>Types</b>		
Supplementary	41	45.6
Early bifurcation	15	16.7
<b>Sides</b>		
Left	11	12.2
Right	12	13.3
Bilateral	3	3.3

The right side was more often affected by renal vein variations, with 25 (278%) patients having late renal vein confluence and 6 (6.7%) patients having additional renal veins. Patients with late renal vein confluence 3 (3.3%) and retroaortic vein (3.3%) were seen on the left side.(table 3)

Table-3: Variations of renal veins with

Variations of renal veins	Left	Right
Late renal vein confluence	25 (278%)	3 (3.3%)
Retroaortic vein	0	3 (3.3%)
Supplementary RV	6 (6.7%)	0
Single Main hilar renal vein	88 (97.8%)	90 (100%)

side distribution

Among 41 cases of supplementary renal arteries, 20 cases had variations in the left kidney and 21 cases had in the right kidney. We found that one hilar supplementary artery was the most common among both groups.(table 4)

Table-4: Distribution of supplementary arteries with sides of kidney

Variations of renal veins	Left (20)	Right (21)
3-hilar	0	1
2-hilar	1	3
1-hilar	12	11
1-superior polar	2	2
1-inferior polar	1	2
1-hilar supplementary and 1- superior polar	1	1
2-superior polar	1	0
2-superior polar and one hilar supplementary	2	1

Nnnfgdyestrd

## DISCUSSION

Renal vessels are known for their wide range of shapes and sizes. Having a thorough understanding of renal vascular variations and abnormalities, as well as their clinical consequences and embryological foundation, is critical. Blood flow to kidneys varies greatly and this research provides a full account of their clinical and embryological significance.

In our study 90 patients were presented. Males were higher in numbers 61 (67.8%) than females. Mean age of the patients was  $51.3 \pm 8.43$  years and mean BMI  $22.4 \pm 8.42$  kg/m<sup>2</sup>. Among 90 cases, 50 (55.6%) were married. 43 (47.8%) cases were from urban areas and 37 (41.1%) patients were educated. These results were comparable to the studies conducted in the past.[13,14] Short arteries may make vascular anastomosis more difficult and lengthen the period spent in warm ischemia during the operation, which makes their form and size critical in kidney donation. [15] We found frequency of anatomical variations of the renal vessel in 62 (68.9%) cases. Frequency of variations of the renal artery was 47 (52.2%). Among 47 cases, supplementary renal artery was found in 41 (45.6%) cases. Early bifurcation of renal artery found in 15 (16.7%). In 11 patients on the right side, 12 patients on the left side, and 3 individuals on both sides, an earlier branching of the renal artery was found. Previous study showed same results.[16]

For the left kidney, the proportion of extra and early-branching renal arteries was determined to be 16 and 21 percent, respectively, whereas for the right kidney, it was 22 and 15 percent, respectively [17]. In the study by Majos M et al. (2018) [18], it was discovered that 43.35 percent of patients had a single renal artery (RA), 37.30 percent had a single renal artery with prehilal branching, and 19.35 percent had multiple renal arteries.

The right side was more often affected by renal vein variations, with 25 (278%) patients having late renal vein confluence and 6 (6.7%) patients having additional renal veins. Patients with late renal vein confluence 3 (3.3%) and retroaortic vein (3.3%) were seen on the left side. According to Zainel MA et al (2020) [19], 26.3% of the Iraqi population had abnormal renal arteries, according to their findings in Iraq. To begin with, it's more prevalent on one side (32.1 percent) than the other (20.7 percent). It was discovered that 25.3% of the population in Turkey had renal artery abnormalities in Bolatli G et al (2021) [20]. As a result, 17.8 percent of these 25.3 percent alterations were early branching and 7.4 per cent extrarenal.

Among 41 cases of supplementary renal arteries, 20 cases had variations in the left kidney and 21 cases had in the right kidney. We found that one hilar supplementary artery was the most common among both groups. It was found in Famurewa OC et al.

(2018) [21] that the inferior polar artery was the most prevalent form of accessory renal artery among Nigerians. Both sides of our study showed an increased prevalence of an additional renal vein, which was the most prevalent form of renal vein we saw in our study participants. In 3.0% on the right and 2.5% on the left, venous changes were revealed to be a late confluency. More than two-thirds of those surveyed (2.5 percent) had many veins, and two-thirds (2.0 percent) had a retroaortic left renal vein visible. On the left, late venous confluence into the IVC is more frequent, as discovered by Vedaraju KS et al (2018) [22]. (14 out of 20). There were two instances of retroaortic left renal vein and one case of circum-aortic left renal vein. Thirty-three of the 100 kidney donors' renal veins were examined by Kumaresan M (2016) [23]. There were 19 people with auxiliary renal veins and 4 people with retro aortic left renal veins in this group. 80.7 percent of patients had just one renal vein, whereas 17.5 percent had several renal veins. In contrast, in the current investigation, just one renal vein was detected in 91.6 percent of the patients on the right side and in 100 percent of the patients on the left side. Only 8.3% of patients on the right side of the body had extra renal veins, making this the least common side of the body to have this problem.[24]

In renal transplantation, vascular reconstruction, and the like, preoperative assessment of renal artery architecture is essential. [25]. It is our hope that this research will add to the body of knowledge and raise public awareness of the fact that the renal arteries are many. This will go a long way toward lowering the likelihood of surgical failure and postoperative problems.

## CONCLUSION

Our findings in this research show renal artery alterations are common. Endovascular, laparoscopic, and urological procedures benefit from morphological examination of the renal vessels.

## REFERENCES

- Hänninen EL, Denecke T, Stelter L et al (2005) Preoperative evaluation of living kidney donors using multirow detector computed tomography: comparison with digital subtraction angiography and intraoperative findings. *Transpl Int* 18:1134–1141
- Turkvatan A, Akinci S, Yildiz S, Olçer T, Cumhuri T (2009) Multi-detector computed tomography for preoperative evaluation of vascular anatomy in living renal donors. *Surg Radiol Anat* 31:227–235
- Kadir S (1986) Angiography of the kidneys. In: Kadir S (ed) *Diagnostic angiography*. Saunders, Philadelphia, pp 445–495
- Spring DB, Salvatierra O Jr, Palubinskas AJ, Amend WJ, Vincenti FG, Feduska NJ (1979) Results and significance of angiography in potential kidney donors. *Radiology* 133:45–47
- Çinar C, Türkvatan A (2016) Prevalence of renal vascular variations: evaluation with MDCT angiography. *Diagn Interv Imaging* 97:891–897
- Eizenberg N, Briggs C, Adams C: *General Anatomy Principles and Applications*. McGraw-Hill Education, Sydney; 2008. 303.
- Moore KL, Dalley AF, Agur AM: *Clinically Oriented Anatomy*. Wolters Kluwer Health, Philadelphia; 2013.
- Sampaio FJ, Passos MA: Renal arteries: anatomic study for surgical and radiological practice. *Surg Radiol Anat*. 1992, 14:113-7.
- Felix W, Keibel F, Mall F: The development of the urogenital organs. *Manual of Human Embryology II*. J. B. Lippincott Company, Philadelphia; 1912. 979.
- Merlin RJ, Michels NA: The variant renal and suprarenal blood supply with data on the inferior phrenic, ureteral and gonadal arteries: a statistical analysis based on 185 dissections and review of the literature. *J Int Coll Surg*. 1958, 29:41-76
- Budhiraja V, Rastogi R, Jain V: Anatomical variations of renal artery and its clinical correlations: a cadaveric study from central India. *J Morphol Sci*. 2013, 30:228-33.
- Natsis K, Paraskevas G, Panagoulis E, Tsarkalis A, Lolis E, Piagkou M, Venieratos D: A morphometric study of multiple renal arteries in Greek population and a systematic review. *Rom J Morphol Embryol*. 2014, 55:1111-22.
- Pradhay G, Gopidas G S, Karumathil Pullara S, et al. (October 21, 2021) Prevalence and Relevance of Multiple Renal Arteries: A Radio-anatomical Perspective. *Cureus* 13(10): e18957.
- Hostiuc S, Rusu MC, Negoii I, Dorobanțu B, Grigoriu M. Anatomical variants of renal veins: A meta-analysis of prevalence. *Sci Rep*. 2019 Jul 25;9(1):10802.
- Kumaresan M, Pk S, Gunapriya R, Karthikeyan G, Priyadarshini A. Morphometric study of renal vein and its variations using CT. *Indian J. Med. Res. Pharm. Sci*. 2016;3:41–49
- Manu Gupta, Nisha V Kaul, Ashish Kumar Shukla. A Contrast Enhanced MDCT Study on the Morphology of Renal Vessels, Their Variations and Clinical Implications. *Int J Anat Res* 2022;10(1):8275-8282.
- Raman SS, Pojchamarnwiputh S, Muangsomboon K, Schulam PG, Gritsch HA. Utility of 16-MDCT angiography for comprehensive preoperative vascular evaluation of laparoscopic renal donors. *AJR*. 2006; 186:1630-1638
- Majos M, Stefanczyk L, Szemraj-Rogucka Z, Elgatal M, CaroRD, Macchi V, Polgaj M. Does the type of renal artery anatomic variant determine the diameter of the main vessel supplying a kidney? A study based on CT data with particular focus on the presence of multiple renal arteries. 2018;40: 381-388
- Zainel MA & Suhelmawloodalnajar. Incidence and Variations of Aberrant Renal Arteries in Kidney Donors Cases. *Medico-legal Update*. 2020; 20(1)
- Bolatli G, Kardeniz MU, Koplay M, Musa Acar, Zarasiz I. Investigation of Renal Artery Variations with Multidetector Computed Tomography Angiography Technique. *Bsj Health Sci*. 2021; 4 (1): 22-25
- Famurewa OC, Asaley CM, Ibitoye BO, Ayoola OO, Aderibigbe AS, Badmus TA, Variations of renal vascular anatomy in a Nigerian population: A computerized tomography study. *Niger J Clin Pract*. 2018; 21(7):840-846
- VedaRaju KS, BooBathi Raja G, Ananda M, Jayashri d. Evaluation of Renal Vascular Anatomy in Prospective Renal Donors Using 128 Slice CT Angiography. *IJARS*. 2018;7(2):20-24
- Kumaresan M, Sankaran PK, Gunapriya R, Karthikeyan G, Priyadarshini. A morphometric study of renal vein and its variations using CT. *IJMRPS*. 2016; 3(11)
- Jose N, Jayaprakash V, Deiva A, Sai V, Jayakumar M. Renal angiographic evaluation of prospective renal donors: Single center data and outcome analysis from South India - A retrospective observational study. *Indian J Transplant*. 2021; 15: 24-8
- Gümüş H, Bükte Y, Ozdemir E, et al.: Variations of renal artery in 820 patients using 64-detector CT-angiography. *Ren Fail*. 2012, 34:286-90.