

ORIGINAL ARTICLE

Quality of Root Canal Filling in Manually and Rotary-Filed Single-Rooted TeethMEHMOOD AHMED RANA¹, SYED ABDUL RAUF SHAH², AZHAR IQBAL³, SAAD HAROON⁴, MANSOOR KHAN⁵, SAQLAIN BIN SYED GILANI⁶¹Assistant professor, Operative Dentistry Department, Bakhtawarmin Medical and Dental College Multan²Professor, Maxillofacial surgeon, Dentistry / Oral & Maxillofacial Department, Quetta³Assistant Professor Department of Restorative Dentistry, College of Dentistry, Jouf University, Saudi Arabia⁴Specialist Endodontist, Dental Department, Muaither Health Center, Primary Healthcare Cooperation, Qatar⁵Assistant Professor, Operative Dentistry Department, Foundation University, Islamabad⁶Assistant Professor, Oral Biology, Foundation University, IslamabadCorresponding author: Syed Abdul Rauf Shah, Email: surgeon.raufshah99@yahoo.com**ABSTRACT****Objective:** This study aimed to determine if there was a significant difference in root canal obturation quality between single-rooted teeth produced using a manual approach and those prepared using a rotational method, as determined by intraoral periapical radiographs.**Study Design:** Randomized control trial**Place and Duration:** This randomized study was conducted at Bakhtawarmin Medical and Dental College during in the period from April, 2022 to September, 2022.**Methods:** Total 80 patients of both genders were presented. All the included cases had single rooted teeth. Age, gender, and residence were some of the detailed demographic information that was documented after getting informed written consent. Patients were equally divided in two groups. Group I underwent manual root canal treatment in 40 cases while in group II rotary endodontic preparation. Outcomes among both groups were recorded in terms of quality of root canal filling. SPSS 23.0 was used to analyze all data.**Results:** There were 45 (56.3%) females and 35 (43.7%) males. Mean age of the patients in group I was 33.3±8.35 years and in group II mean age was 34.9±7.23 years. We did not find any significant difference in root canal filling and homogeneity among both groups. Group II showed a significantly good results of T score as compared to group I with p value <0.005.**Conclusion:** According to the results of this research, the rotary approach yielded higher quality obturations in terms of taper and overall quality than did the traditional method. Despite this, there was no difference between rotary and manual instrumentation in terms of the radiographic technical quality of the root canal obturation with respect to length and density.**Keywords:** obturation quality, Root Canal Treatment, Manual technique, Rotary Technique**INTRODUCTION**

The main objective of root canal preparation during root canal treatment is to reduce the maximum number of invading bacteria from the root canal system, remove organic tissue and alter the shape of the root canal system so that it is more receptive of a root canal filling material while maintaining the original shape of the prepared root canal.

Traditionally canal preparations have been carried out using stainless steel hand files. These instruments have efficient cutting capability but are not suitable for treating curved canals because of their limited flexibility. The rigid nature of these files may lead to iatrogenic errors like ledge formation, canal straightening, canal transportation and canal perforation. Hand files also lack larger tapers which may be helpful in developing adequately tapered root canals. An adequately tapered root canal allows better irrigation of the apical areas and is easier to obturate compared to a non-tapered or less tapered canal. [1]. Various preparation techniques such as the step-back or the crown down canal preparation technique have been designed to allow the preparation of an adequately tapered root canal with the help of hand files while reducing the incidence of iatrogenic errors. These techniques are however time consuming and have shown limited ability to avoid root canal straightening in severely curved root canals [2].

The recent development in endodontics has been the introduction of Nickel Titanium files (NiTi). NiTi files are commonly used with an electrically operated torque-controlled motor. These files are used either in greater taper configurations such as 4 % or 6 % tapers or as in the case of Pro-taper with variable taper incorporated in the same file. Owing to the physical properties of NiTi namely super elasticity and shape memory these files are better suited for managing curved canals and complex root canal anatomy. NiTi files promised the preparation of canals with an adequate taper in complex cases while avoiding the incidence of iatrogenic errors related with canal straightening.

Four factors are associated with predicting the long-term prognosis of teeth post obturation [3]. Two of these factors are

associated with the quality of the obturation namely the length of the root canal filling material and the presence or absence of voids in the final obturation. Studies have shown that those teeth had the most favorable prognosis post-RCT in which the root filling ended 0-2 mm from the radiographic apex. The poorest prognosis was associated with teeth that were over obturated, while the second worst prognosis was associated with teeth where the obturation was more than 2 mm short of the radio graphic apex [8]. In-addition to this the presence of voids in the root filling also leaves potential areas where the surviving bacteria may multiply and seep into the apical area and cause root canal failure.

Most of the outcome studies utilize Periapical paralleling radiographs [6] as an imaging modality to evaluate the obturation quality from a technical standpoint. Although this

In order to evaluate the technical quality of root filling in relation to operator experience, several endodontic epidemiological studies had been conducted in various population groups [7]. However few studies have been done so far to link the quality of the obturation to various canal instrumentation techniques. The current study's aim was to compare the quality of obturation between manual and rotary instruments in clinical practice.

The pulp tissue is directly affected by extensive caries in young children, producing pain and discomfort. Necrotic baby teeth are more likely to be saved thanks to pulpectomy, which helps children avoid bad oral hygiene practices and the need to move other teeth to make room [4]. An accurate diagnosis of the pulp state is necessary for determining the best course of therapy for each individual patient. In order to determine the health of the pulp, it is required to do a thorough clinical examination, pain history, high-quality periapical radiograph, and pulp sensitivity testing [5]. Clinical decision-making should be aided by radiographic diagnosis, which enables for evaluation of caries severity and commitment to supporting tissues. What kind of projection, between bitewing and periapical, is best will depend on the extent of the caries. When it comes to treating the pulp, periapical radiographs are the gold standard since they provide crucial

information about the tooth's overall affectation, bone health, root structure, and even the location of the permanent tooth's germ. When evaluating pulpitis, it is not appropriate to utilize CBCT on a regular basis. Hemostasis, or the absence thereof, during pulpal therapy will serve as the last evidence of pulpal inflammation [6].

Radiographic images are typically used to assess these factors post operatively. Furthermore, clinical factors required for obtaining an acceptable root canal obturation can be discovered during the root canal preparation and obturation phases of therapy [7,8].

The presence of voids in the root filling material, the taper of the canal, and the length of the root filling material in relation to the radiographic apex are all factors that contribute to the determination of the root filling's technical quality. To this day, radiographic evaluation [9] has served as the cornerstone of methodologies used to evaluate the RCT's viability from a technical standpoint.

Root fillings that are placed within 0-2 mm of the radiographic apex had a decreased probability of developing post-treatment disease [10]. This is in comparison to root fillings that are either over obturated or more than 2 mm short of radiographic apex. Root canal treatment (RCT) results have been demonstrated to be substantially impacted by the length of the root filling in relation to the radiographic apex, with studies finding 87-94% healing rates connected with root filling ending 0-2 mm from the radiographic apex. This has been proved to be the case. Lower healing rates were seen for both short root fillings (those that stopped less than 2 mm from the radiographic apex) and long fillings (those that protruded beyond the apex). [11].

One of the features of the prognosis for endodontic treatment is the quality of the shutter. The current gold standard for gauging the quality of endodontic therapy is the periapical radiographic examination. Root canal filling radiography volume, homogeneity, and taper are used to evaluate the success of endodontic treatment. Several research including undergraduates, graduates, and postgraduates have been undertaken, but their results are inconsistent since they all use various approaches to channel preparation for the quality evaluation (manual vs. rotative). [12,13]

This study set out to compare the effectiveness of rotary and hand-filed root canal obturation.

MATERIAL AND METHODS

80 patients were enrolled in this descriptive cross-sectional study carried out at Bakhtawar-amin Medical and Dental College between April 2022 and September 2022, after obtaining the approval from the institutional review board. A thorough descriptions of the procedure was given to the patients and the informed consent was obtained before enrollment in the study. Participant's age and gender were recorded. Patients with multi-rooted teeth, reduced mouth opening or young patients with mixed or deciduous dentition were excluded from the study.

Ages of participants included in the study varied from 20 to 65 years, with a single rooted tooth requiring root canal treatment either due to symptomatic irreversible pulpitis with or without symptomatic apical periodontitis, or patients with pulp necrosis with or without symptomatic apical periodontitis. All the procedures were carried out by a single operator.

The patients were split into two groups at random. Patients in group 1 received manual root canal preparation with M-access manual 2% taper files (Dentsply) using the step back canal preparation technique and Patients in group 2 received rotary root canal preparation using protaper gold file system (Dentsply). Obturation in both groups was done using the cold lateral condensation technique. In group 1 standard 2% gutta percha points (Gapadent) were used during obturation while in group 2 protaper (Dentsply) matching g.ps were used to obtain the apical seal. Accessory g.ps used in both groups were of the standard 2% taper (Gapadent). Seal apex was used as sealant in both groups (Sybron endo). An intraoral periapical

paralleling radiograph was taken after the endodontic treatment using Digora Toto Intra-Oral Sensor (Soredex).

Pre-op and post-obturation the periapical radiographs of each were examined by 2 trained endodontists without the knowledge of instrumentation used (rotary or manual) and observed the fillings length, consistency/density, and taper. The examiners were calibrated before the examination. This calibration was done on 20 cases and an intra-examiner reliability of 0.7 was achieved by intraclass correlation coefficient. Two post-op radiographs were examined on the Digora for windows 2.7 software at 1:1 magnification.

A criterion as shown in table (Barrieshi – Nusair et al) which evaluated the length, density and taper of the root canal filling was used to record the information regarding the root canal fillings. Based on this criterion a t score scoring system was used to evaluate the canals [20]. If all three of the requirements were met (i.e. root filling with in 2mm of radiographic apex, no voids and smooth corono-apical taper) a maximum score of '3' was given which was deemed "perfect". Score '2' was given when 2 of the three requirements were met and score '1' was given to obturations that satisfied only 1 of the parameters. Score '0' was assigned in case none of the obturation parameters were observed.

Table 1: criterion of RCF (Root Canal Filling)

| Variable | Criteria | Definition |
|------------------------------|------------|---|
| Length of root canal filling | Acceptable | Root filling ending ≤ 2 mm short of radiographic apex |
| | Over | Root filling ending beyond the radiographic apex |
| | Under | Root filling ending more than 2 mm short of radiographic apex |
| Density of root filling | Poor | Not uniform density of root filling with clear presence of voids and canal space is visible |
| | Acceptable | Uniform density of root filling without voids and canal space is not visible |
| Taper of root filling | Acceptable | Consistent taper from the coronal to the apical part of the filling, with good reflect to canal shape |
| | Poor | Not consistent taper from the coronal to the apical part of the filling |

The major result was determined by contrasting the two groups' T-scores. The 23.0 version of SPSS was used to examine the data. The quality of obturation was analyzed between the two groups using the chi-square test. Statistical significance was assumed when the p-value was less than 0.05.

RESULTS

In all patients, there were 45 (56.3%) females and 35 (43.7%) males. (Figure 1)

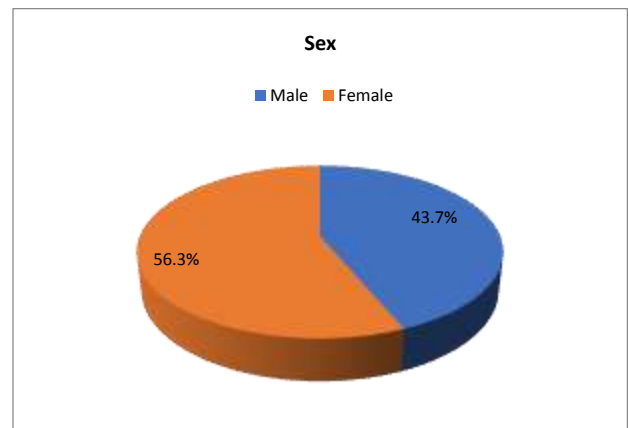


Figure 1: Mean age of the patients in group I was 33.3±8.35 years and in group II mean age was 34.9±7.23 years. (Table 1)

Table-2: Case enrolment characteristics

| Variables | Group I | Group II |
|------------------|-----------|-----------|
| Mean age (years) | 33.3±8.35 | 34.9±7.23 |

In group I 85% cases had adequate length of RCF and in group II 77.5% had adequate length of RCF. As per homogeneity of RCF, 65% cases in group 1 had adequately dense filling and 80% in group II had adequate homogeneity. We found a significant difference of taper of RCF in both groups, 70% cases of group I had adequate taper while in group II 8% cases had adequate taper. (Table 2)

Table-3: Obturation Quality in contrast between two groups

| RCF | Group I | Group II |
|----------------------|----------|------------|
| Adequate Length | | |
| Yes | 34 (85%) | 31 (77.5%) |
| No | 6(15%) | 9 (22.5%) |
| Adequate Homogeneity | | |
| Yes | 26 (65%) | 32 (80%) |
| No | 14 (35%) | 8(20%) |
| Adequate Taper | | |
| Yes | 28 (70%) | 37 (92%) |
| No | 12(30%) | 3(8%) |

Table 4: As per T-score, in group II 25 (62.5%) cases had score 3 and 10 (25%) cases had score 2 and 5 (12.5%) teeth had score 1. While in group I 15 (37.5%) cases had score 3 and 19 (47.5%) cases had T-score 2 and 6 teeth (15%) had score 1.

| Preparation technique | Number of teeth | T Score 1 | T Score 2 | T Score 3 |
|-----------------------|-----------------|-----------|-----------|-----------|
| Manual (Group I) | 40 | 6 | 19 | 15 |
| Rotary (Group II) | 40 | 5 | 10 | 25 |

DISCUSSION

Healthcare professionals are often reluctant to abandon conventional treatment modalities and adopt new methods. They frequently resist adopting unconventional methods of treatment due to concerns regarding the desired outcome. [14] Both clinical and radiographical outcomes have to be favorable in order to deem a root canal treatment successful. absence of clinical signs and symptoms as well as periapical healing and no recurrence within six months, a root canal treatment is deemed successful. In the current study the obturation quality of manual (stainless steel) and rotary (protaper NiTi) canal preparation modalities was compared.

In this study 80 patients of both genders were enrolled. There were 45 (56.3%) females and 35 (43.7%) males. Patients were equally categorized in two groups. Mean age of the patients in group I was 33.3±8.35 years and in group II mean age was 34.9±7.23 years. The percentage of root fillings with adequate length was 77% with manual canal preparation technique and 85% with rotary canal preparation, the frequencies were higher than reported by Er et al. (70%), Lupi-Pegurier et al. (39%), Chueh et al. (62%) and Eleftheriadis & Lambrianidis (63%) [15,16]. When viewed in detail, group I had 5 under-fillings with 1 over-filling, and group II had 7 over-filling with 2 under-fillings.

The lateral adaptation of root canal filling is considered 'inadequate' in case of voids present and Kirkevang et al. reported that such voids lead to root canal failures. In the current study 65% of group I had adequate lateral filling and 80% in group II. Also, the researchers found no significant difference in filling consistency between the two groups. Compared to the conventional group, the rotary group saw a significantly higher frequency of instances with sufficient density (manual). However, in 2011 research by Robia G, it was found that the incidence of instances with acceptable density was observed to be considerably greater in the rotary group compared to the manual group. [17]

Single-rooted teeth (incisors, canines, premolars) were used in this study to evaluate the radiographic obturation quality of two root canal preparation methods as compared to earlier studies that used either molars alone or made no distinction based on the type of teeth involved. When comparing the quality of root canal fillings completed using manual instrumentation against rotary equipment,

no significant differences were seen in between the two groups. It seems that the proportion of properly filed cases was comparable across the two groups.

The canal's natural curve and taper must be preserved throughout preparation, from the canal opening to the apical foramen. [18] A larger percentage of patients in the rotary group had an acceptable taper than in group I (77.5% vs. 32.5%) in this research.

Using a T-score to measure the overall quality of obturation, we found a statistically significant ($p<0.005$) difference between the two groups. The percentage of instances with a T-score of 3 (classified as having perfect obturation) was significantly higher in the rotary group (50%) than in the manual group (25%).[19]

CONCLUSION

According to the results of this research, the rotary approach yielded higher quality obturations in terms of taper and overall quality than did the traditional method. Despite this, there was no difference between rotary and manual instrumentation in terms of the radiographic technical quality of the root canal obturation with respect to length and density.

REFERENCES

- 1 Ansari I, Maria R. Managing curved canals. *Contemp Clin Dent.* 2012 Apr;3(2):237-41.
- 2 Wiene FS. *Endodontic therapy.* 6th ed. St Louis: Mosby; 2004.
- 3 Polyzos NK, Sarris KG, Pita AI, Mikrogeorgis GV, Lyroudia KM. Factors Affecting the Outcome of Non-Surgical Endodontic Treatments Performed by Undergraduate Students in a Greek Dental School. *Eur Endod J.* 2018 Jul 19;3(2):93-100.
- 4 Chauhan, A.; Saini, S.; Dua, P.; Mangla, R. Rotary Endodontics in Pediatric Dentistry: Embracing the New Alternative. *Int. J. Clin. Pediatric Dent.* 2019, 12, 460–463.
- 5 Ghaderi, F.; Jowkar, Z.; Tadayon, A. Caries Color, Extent, and Preoperative Pain as Predictors of Pulp Status in Primary Teeth. *Clin. Cosmet. Investig. Dent.* 2020, 3, 263–269
- 6 Duncan, H.F.; Galler, K.M.; Tomson, P.L.; Simon, S.; El-Karim, I.; Kundzina, R.; Krastl, G.; Dammaschke, T.; Fransson, H.; Markqvist, M.; et al. European Society of Endodontology position statement: Management of deep caries and the exposed pulp. *Int. Endod. J.* 2019, 52, 923–934
- 7 Burch JG, Hulén S. The relationship of the apical foramen to the anatomic apex of the tooth root. *Oral Surg. Oral Med. Oral Pathol.* 1972;34:262–268.
- 8 Chugal NM, Clive JM, Spångberg LSM. Endodontic infection: some biologic and treatment factors associated with outcome. *Oral Surg. Oral Med. Oral Pathol. Oral Radio and Endod.* 2003;96:81–90
- 9 Saunders WP, Saunders EM, Sadiq J, Cruickshank E. Technical standard of root canal treatment in an adult Scottish sub-population. *British Dental Journal.* 1997;182:382–386.
- 10 Boltacz-Rzepkowska E, Pawlicka H. Radiographic features and outcome of root canal treatment carried out in the Łódź region of Poland. *International Endodontic Journal.* 2003;36:27–32.
- 11 Sjögren U, Hägglund B, Sundqvist G, Wing K. Factors affecting the long term results of endodontic treatment. *Journal of Endodontics.* 1990;16:498–504
- 12 Román-Richón S, Faus-Matoses V, Alegre Domingo T, Faus-Llácer VJ. Radiographic technical quality of root canal treatment performed ex vivo by dental students at Valencia University Medical and Dental School, Spain. *Medicina Oral, Patología Oral Cirugía Bucal* 2014;19(1): 93-7
- 13 Makarem A, Ravandeh N, Ebrahimi M. Radiographic assessment and chair time of rotary instruments in the pulpectomy of primary second molar teeth: a randomized controlled clinical trial. *J Dent Res Dent Prospects* 2014; 8(2): 84-9
- 14 Crespo S, Cortes O, Garcia C, Perez L. Comparison between rotary and manual instrumentation in primary teeth. *J Clin Pediatr Dent.* 2008;32:295–8.
- 15 Robia G. Comparative radiographic assessment of root canal obturation quality: manual versus rotary canal preparation technique. *Int J Biomed Sci.* 2014 Jun;10(2):136-42.
- 16 Govindaraju L, Jeevanandan G, Subramanian EMG. Comparison of quality of obturation and instrumentation time using hand files and two rotary file systems in primary molars: A single-blinded randomized controlled trial. *Eur J Dent.* 2017 Jul-Sep;11(3):376-379.
- 17 Robia G. Comparative radiographic assessment of root canal obturation quality: manual versus rotary canal preparation technique. *Int J Biomed Sci.* 2014; 10(2): 136-42
- 18 Yilmaz A, Karagoz-Kucukay I. In vitro comparison of gutta-percha-filled area percentages in root canals instrumented and obturated with different techniques. *J Istanbul Univ Fac Dent.* 2017; 51(2): 37–42
- 19 Casaña Ruiz, M.D.; Martínez, L.M.; Miralles, E.G. Update in the Diagnosis and Treatment of Root Canal Therapy in Temporary Dentition through Different Rotary Systems: A Systematic Review. *Diagnostics* 2022, 12, 2775.
- 20 Barrieshi-Nusair, K & Al-Omari, M.A & Al-Hiyasat, Ahmad. (2004). Radiographic technical quality of root canal treatment performed by dental students at the Dental Teaching Center in Jordan. *Journal of dentistry.* 32. 301-7. 10.1016/j.jdent.2004.01.002.