

ORIGINAL ARTICLE

Effectiveness of Emergency Ligation of Internal ILIAC Artery in Controlling Post-Partum Hemorrhage

HUMAIRA BASHIR¹, SABEEHA KHAN², RUBINA BABER³, REHANA TASKEEN⁴, IRAM RAFIQUE⁵, DURRI SHAHWAR⁶

¹Trainee registrar, Mufti Mehmood Teaching Hospital DI Khan

²Women Medical officer, Gynae/Obs, RHC Ekka Ghund

³Senior medical officer, Gynae/Obs, Mufti mehmood Teaching Hospital DI Khan

⁴Women medical officer, Gynae/Obs, DHQ Hospital Karak

⁵Woman medical officer, Gynae/Obs, THQ Hospital Kabirwala

⁶Woman medical officer, Gynae/Obs, THQ Hospital Dargai

Correspondence to: Humaira Bashir, Email: humairabashir38@gmail.com, Cell: +92 335 4829355

ABSTRACT

Treatment of severe pelvic bleeding remains a major challenge in obstetrics and Gynecology. In this situation, an attempt was made with variable success at bilateral internal iliac artery ligation (BIAL).

Aim: The purpose of this study was to evaluate the effectiveness of this procedure in females with intractable pelvic hemorrhage.

Methods: This observational study was conducted at the Department of Obstetrics and Gynecology of Mufti Mehmood Teaching Hospital D I Khan for one year duration from January 2021 to December 2021. During the study period, a total of 35 emergency internal iliac arteries ligation and, if necessary, gradual uterine de-vascularization or cesarean hysterectomy were performed as a life-saving procedure.

Results: Haemostasis was successfully achieved in 33 patients. Of the 35 patients who required a cesarean hysterectomy, two patients died of multiple organ dysfunction following the hysterectomy. However, no complications related to BIAL were observed in any of the other patients. The mortality rate was 5.7% in this study.

Conclusions: In our study, BIAL was recognized as a safe and effective treatment procedure for life-threatening obstetric haemorrhage. But for unknown reasons, the procedure is much less practiced than other radical options.

Keywords: ligation of internal iliac artery, emergency, pelvic bleeding

INTRODUCTION

Postpartum hemorrhage was the Achilles' heel in controlling maternal deaths¹. Uterine atony is the most common cause of life-threatening obstetric bleeding². Currently, failure of conservative treatment is treated with uterine compression sutures followed by gradual uterine devascularization and artery embolization³. Conventional surgical treatment for patients who do not respond to these procedures is to perform an urgent hysterectomy, which eliminates the possibility of future fertility⁴. BIAL is an alternative rescue operation that maintains reproductive capacity⁵. However, due to inexperience, only a few surgeons prefer this operation over an emergency hysterectomy. The American College of Obstetricians and Gynaecologists (ACOG) continues to advocate the use of BIAL in the treatment of intraoperative bleeding during pelvic surgery or in cases of obstetric bleeding⁶. The rationale behind this is based on haemodynamic studies by Mengert and Burchell in the 1970s, which showed that BIAL reduced pelvic blood flow by 49% and heart rate by 85%. This large reduction in pressure results in venous pressure in the arterial circuit, which promotes hemostasis⁷. The purpose of this study was to evaluate the effectiveness of this procedure in females with intractable pelvic hemorrhage.

MATERIALS AND METHODS

This observational study was conducted at the Department of Obstetrics and Gynecology of Mufti Mehmood Teaching Hospital D I Khan for one year duration from January 2021 to December 2021, a total of 35 internal iliac emergency ligatures were performed. Age, number of deliveries, period of pregnancy, diagnosis, method of delivery, cause of PPH, BIAL indication, number of transfused units, intraoperative and postoperative complications, and follow-up were examined. Atonic or traumatic PPH during vaginal delivery or cesarean delivery were treated with BIAL. Prophylactic BIAL was also used in a patient at risk of developing PPH (abruption, placenta previa). Uterine massage and oxytocic were applied in accordance with the active progress of the birthing protocol for third stage of labour. If these procedures failed to stop the bleeding, BIAL was performed. The internal iliac artery was ligated intraperitoneally (Fig. 1).

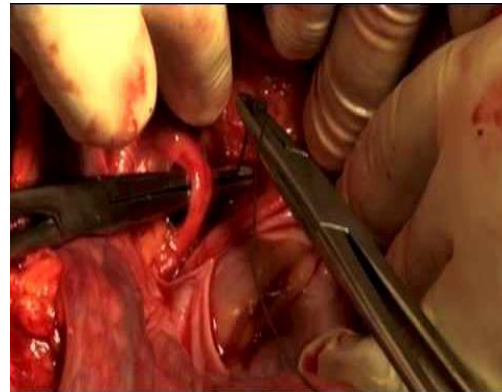


Fig 1: Anterior internal iliac artery branch Ligation

Urgent caesarean section was performed in 19 patients who have placental abruption. They all had atonic PPH, unresponsive to uterotonics. Attempted gradual devascularization of the uterus was made before continuing with BIAL. In four cases of previous caesarean section during active labor, the uterus ruptured, requiring BIAL. However, all patients underwent caesarean hysterectomy due to intractable bleeding. Four women who gave birth vaginally after outlet forceps application had extensive vaginal and cervical tears. A preliminary examination was carried out for tears and suturing was carried out. Due to haemodynamic instability, laparotomy and BIAL were performed. In another two patients with central placenta previa a caesarean section was performed, followed by prophylactic BIAL in the absence of significant uterine bleeding. A caesarean section was performed in a patient with severe abruption and an IUFD. Secondary PPH occurred on 12th postoperative day in six patients. Doppler examinations showed pseudoaneurysm in the left uterine artery. Since there was no possibility of embolization of the uterine artery, BIAL was done and the bleeding was controlled.

RESULTS

A total of 35 BIAL done for PPH and one of them requires prophylactic BIAL during the study period. Uterine atony (68.5%)

was a frequent indication for the therapeutic IIAL. Other indications are uterine rupture, central anterior placenta, and traumatic PPH. The average age was 24.6 years. The parity ranged from nulliparity to para 4.

Table 1: Indications for BIAL n =35

Indication	Number of women (%)
Placenta abruption	19
Genital tract injury	4
Placenta previa	2
Rupture uterus	4
Secondary PPH	6
Total	35

Caesarean hysterectomy was performed in 4 cases due to intractable bleeding after BIAL. In the remaining cases, BIAL performed for therapeutic and prophylactic purposes and the procedure was successful. Two of the 35 patients died of uterine rupture and IUD, or even BIAL, followed by cesarean hysterectomy. In the remaining 33 cases after BIAL, there was no postoperative bleeding. No complications related to BIAL such as gluteal paraesthesia, buttock necrosis and bladder atony were observed. 33 patients were discharged home without any problems or complications other than the procedure developed during their postpartum follow-up. Eleven of the thirty-five patients subsequently had successful pregnancies. None had evidence of reduced fetal growth or PPH.

Table 2: Hysterectomy in women undergoing IIAL for uterine hemorrhage

Indication	Total number of women	Hysterectomy carried out(n)	Uterine salvage rate (%)
Placental abruption	19	0	100
Genital tract injury	4	0	100
Placenta previa	2	0	100
Rupture uterus	4	4	0
Secondary PPH	6	0	100

DISCUSSION

BIAL is an effective emergency procedure to control obstetric and gynaecological bleeding. Managing postpartum bleeding can be life threatening. Efforts to reduce PPH have been evident since time immemorial. In 1893, Sir Howard Kelly was the first to create BIAL. Later, Mengret and Burchel popularized this procedure⁸⁻⁹. The conversion of blood pressure to venous pressure, facilitating stagnation, is the basic principle of BIAL. Pulse pressure is reduced by up to 77% with unilateral ICA ligation and up to 85% with BIAL¹⁰. Lowering your blood pressure will cause blood to clot in the area of the damaged veins without losing blood flow to the pelvis. There are extensive collateral arteries between the aorta and the femoral artery, including the lumbar, iliopsoas, medial sacral, lateral sacral, upper and medial hemorrhoidal and gluteal arteries. Therefore, the collateral circulation becomes apparent 45-60 minutes after the ligation. In a multicentre retrospective study from Turkey, the uterus was preserved in only 17 (32.0%) of 53 patients undergoing BIAL due to severe PPH. Postoperative coagulopathy developed in 26 (49.1%) patients. Therefore, this may explain the low success rate of BIAL in this study compared to another studies¹¹⁻¹². In a prospective study in Egypt, Refaie et al. Assessed 51 pregnant women with an adherent placenta (both increta and accreta). Prophylactically BIAL was administered to all patients after delivery and before removal of the placenta. Satisfactory hemostasis was achieved in 82.6% of patients. However, an additional hysterectomy was performed in 29.6% of patients with placenta increta due to resistant bleeding¹³⁻¹⁴. A prospective study in India looked at the benefits and risks of using BIAL in 64 women. The predominant group were women with the placenta previa (21.8%). BIAL had an efficiency of 96.87%. Four of the sixty-four women died from bleeding complications. However, there were no complications with the procedure. Patients were

followed after 6 weeks and 6 months. After 6 months of ligation of the internal iliac arteries in 60-year-old women, flow was found in the distal part of the ligated internal iliac arteries¹⁵. Only a few other studies mention the re-treatment of recanalization. There is also a risk of severe retroperitoneal bleeding from turbulent flow and recanalized vessels with abnormal hemodynamics. In the largest series of hypogastric artery ligation after pregnancies, seventeen patients had 21 pregnancies over the 13-year study period. Thirteen full-term births, three miscarriages, two ectopic pregnancies; three patients had PPH and received medical treatment¹⁶. The WHO PPH management guidelines included 21 case series and 13 case reports involving 532 women to investigate the results of BIAL. Reported success in preventing hysterectomy ranges from 62% to 100%. The guide also reviews the evidence for arterial embolization. A total of 18 case series involving 340 women and 15 case reports were assessed. Success in avoiding hysterectomy ranges from 82% to 100%. Before proceeding with invasive procedures, guidelines recommend BIAL (with strong recommendation) for intractable PPH or arterial embolization when devices are available. However, they admitted that depending on the degree of the surgeon's advancement, the available devices will determine the order of intervention¹⁷. The Healthcare Research and Quality Agency (AHRQ) has reviewed the literature on PPH. The effectiveness of uterine protection measures in life-threatening PPH ranges from 36% to 98%. The literature was assessed as weak and therefore there is no possibility to compare the studies. Most of the studies have been retrospective and only a few are prospective. Hence, they recommend further research into all interventions in the treatment of PPH¹⁸⁻¹⁹. Several trials have recently been published on selective arterial occlusion or the UAE (uterine artery embolization) versus BIAL. A randomized controlled trial compared the intraoperative ligation of the internal iliac artery with occlusion closure²⁰. A randomized control study compared uterine artery embolization to serial devascularization. A total of 23 women were enrolled in the study, eleven in the UAE group and twelve in the serial devascularization group. In the serial devascularization group, bilateral uterine artery ligation was performed first, and in case of failure, B-lymph sutures were applied. If this was unsuccessful, patients received BIAL. In the BAE group, 9 patients were treated successfully, and 2 patients advanced enough to require a hysterectomy. In the group with serial devascularization, 9 patients were successfully cured and 3 went on to hysterectomy. The complication rates were similar in both groups. The University of Cairo is conducting a study in women diagnosed with the placenta praecura before surgery²¹⁻²². The study compares BIAL with a hysterectomy. The amount of blood loss, complications, morbidity and mortality will be compared between the two groups. Most studies have variants of their own, such as serial devascularization targeting BIAL directly. The amount of blood lost, used units of blood products, secondary infection, accompanying sepsis and multiorgan failure, disseminated intravascular coagulation may all affect the result. This makes comparisons between studies difficult²³⁻²⁴. The test population is small again as seen in the previous 2 studies and the ongoing study. A well-designed multicentre study with a large matched population may further explain the current debate over the superiority of angioembolization over BIAL. Thanks to better prenatal care and greater diagnostic possibilities, patients at risk of PPH can be referred earlier to a high-risk birth centre²⁵.

CONCLUSION

In the current era of vascular interventions, intractable PPH is treated with angioembolization of the uterine arteries. However, the facility and expertise may not be available in many hospitals. Even in centres where uterine artery embolization is available, rigorous, controlled trials are needed to compare the efficacy and cost benefits of BIAL versus uterine artery embolization.

REFERENCES

1. Nayak AK, Dhivya S, Nayak R, Mandpe P. Emergency internal iliac artery ligation in control of postpartum hemorrhage: a life-saving procedure. *INTERNATIONAL JOURNAL OF SCIENTIFIC STUDY*. 2017;4(12):183-6.
2. Selçuk İ, Uzuner B, Boduç E, Baykuş Y, Akar B, Güngör T. Step-by-step ligation of the internal iliac artery. *Journal of the Turkish German Gynecological Association*. 2019 Jun;20(2):123.
3. Wang CY, Pan HH, Chang CC, Lin CK. Outcomes of hypogastric artery ligation and transcatheter uterine artery embolization in women with postpartum hemorrhage. *Taiwanese Journal of Obstetrics and Gynecology*. 2019 Jan 1;58(1):72-6.
4. Dai MJ, Jin GX, Lin JH, Zhang Y, Chen YY, Zhang XB. Pre-cesarean prophylactic balloon placement in the internal iliac artery to prevent postpartum hemorrhage among women with pernicious placenta previa. *International Journal of Gynecology & Obstetrics*. 2018 Sep;142(3):315-20.
5. Hussein AM, Dakhly DM, Raslan AN, Kamel A, Abdel Hafeez A, Moussa M, Hosny AS, Momtaz M. The role of prophylactic internal iliac artery ligation in abnormally invasive placenta undergoing caesarean hysterectomy: a randomized control trial. *The Journal of Maternal-Fetal & Neonatal Medicine*. 2019 Oct 18;32(20):3386-92.
6. Kaya B, Damarer Z, Daglar K, Unal O, Soliman A, Guralp O. Is there yet a role for internal iliac artery ligation in obstetric hemorrhage with the current gain in popularity of other uterus sparing techniques?. *The journal of maternal-fetal & neonatal medicine*. 2017 Jun 3;30(11):1325-32.
7. Li Z, Chen Y, Zeng X, Stephen S, Li Y, Li H, Dong L, He T, Zhang S, Yang P, Jiang W. Clinical and hemodynamic insights into the use of internal iliac artery balloon occlusion as a prophylactic technique for treating postpartum hemorrhage. *Journal of Biomechanics*. 2021 Dec 2;129:110827.
8. Yılmaz EP, Topdağı YE, Eren S, Kumtepe Y. Bilateral iliac artery aneurysm: A rare cause of postpartum recurrent hemorrhage. *Turkish Journal of Obstetrics and Gynecology*. 2020 Mar;17(1):73.
9. Zhou XE, Sun X, Wang M, Huang L, Xiong W. The effectiveness of prophylactic internal iliac artery balloon occlusion in the treatment of patients with pernicious placenta previa coexisting with placenta accreta. *The Journal of Maternal-Fetal & Neonatal Medicine*. 2021 Jan 2;34(1):93-8.
10. Bienstock JL, Eke AC, Hueppchen NA. Postpartum hemorrhage. *New England Journal of Medicine*. 2021 Apr 29;384(17):1635-45.
11. Jain A, Sapkal RU. Internal iliac artery ligation to combat post partum haemorrhage: an institutional review of case series. *International Journal of Reproduction, Contraception, Obstetrics and Gynecology*. 2017 Jun 1;6(6):2347-51.
12. Yasmeen N. Emergency Bilateral Internal Artery Ligation in Control of Post-Partum Hemorrhage. *Annals of Punjab Medical College (APMC)*. 2019 Mar 31;13(1):64-8.
13. Newsome J, Martin JG, Bercu Z, Shah J, Shekhani H, Peters G. Postpartum hemorrhage. Techniques in vascular and interventional radiology. 2017 Dec 1;20(4):266-73.
14. Fan Y, Gong X, Wang N, Mu KT, Feng L, Qiao FY, Chen SH, Zeng WJ, Liu HY, Wu YY, Zhou Q. A participant-assigned interventional research of precesarean internal iliac artery balloon catheterization for managing intraoperative hemorrhage of placenta previa and placenta accreta spectrum disorders after cesarean section. *Current Medical Science*. 2021 Apr;41(2):336-41.
15. Akhtar R, Inayat K, Utman N. INTERNAL ILIAC ARTERY LIGATION FOR ARRESTING POSTPARTUM HEMORRHAGE. *KJMS*. 2018 May;11(2):282.
16. Leleup G, Fohlen A, Dohan A, Bryan-Rest L, Le Pennec V, Limot O, Le Dref O, Soyer P, Pelage JP. Value of round ligament artery embolization in the management of postpartum hemorrhage. *Journal of Vascular and Interventional Radiology*. 2017 May 1;28(5):696-701.
17. Singh SP, Misra S, Sharma N. Role of emergency bilateral internal iliac ligation in postpartum hemorrhage. *International Journal of Reproduction, Contraception, Obstetrics and Gynecology*. 2021 Aug 1;10(8):3086-90.
18. Verit FF, Çetin O, Keskin S, Akyol H, Zebitay AG. Does bilateral uterine artery ligation have negative effects on ovarian reserve markers and ovarian artery blood flow in women with postpartum hemorrhage?. *Clinical and Experimental Reproductive Medicine*. 2019 Mar;46(1):30.
19. Brown M, Hong Jr M, Lindquist J. Uterine Artery Embolization for Primary Postpartum Hemorrhage. *Techniques in Vascular and Interventional Radiology*. 2021 Mar 1;24(1):100727.
20. Said Ali A, Faraag E, Mohammed M, Elmarghany Z, Helaly M, Gadallah A, Taymour MA, Ahmad Y, Ibrahim Eissa A, Ibrahim Ogila A, Ali MK. The safety and effectiveness of Bakri balloon in the management of postpartum hemorrhage: a systematic review. *The Journal of Maternal-Fetal & Neonatal Medicine*. 2021 Jan 17;34(2):300-7.
21. Fan Y, Gong X, Wang N, Mu K, Feng L, Qiao F, Chen S, Zeng W, Liu H, Wu Y, Zhou Q. A prospective observational study evaluating the efficacy of prophylactic internal iliac artery balloon catheterization in the management of placenta previa-accreta: A STROBE compliant article. *Medicine*. 2017 Nov;96(45).
22. Lindquist JD, Vogelzang RL. Pelvic artery embolization for treatment of postpartum hemorrhage. In *Seminars in Interventional Radiology* 2018 Mar (Vol. 35, No. 01, pp. 041-047). Thieme Medical Publishers.
23. Wei Y, Luo J, Luo D. Comparison of efficacy between internal iliac artery and abdominal aorta balloon occlusions in pernicious placenta previa patients with placenta accrete. *Gynecologic and Obstetric Investigation*. 2019;84(4):343-9.
24. Beeresh CS, Doopadapalli D, Krishna L. Efficacy of internal iliac artery ligation for control of post-partum haemorrhage. *International Journal of Reproduction, Contraception, Obstetrics and Gynecology*. 2019 May 1;8(5):1963-7.
25. Prabhudev P, Chigateri S. Efficacy of emergency internal iliac artery ligation in controlling post-partum hemorrhage. *Indian Journal of Obstetrics and Gynecology Research*. 2017;4(3):283-7.