

Pattern of Uterine and Cervical Lesions Marked on Histopathological Examination of Hysterectomy Specimens

HENNA KHALID¹, MARIAM RIAZ², MOMINA KHADIJA ABBASI³, BUSHRA ADEEL⁴, SADIA SHOUKAT⁵, REEMA FATEH⁶

¹Associate Professor Histo-Pathology, Women Medical & Dental College, Abbottabad

²Associate Professor Microbiology / Pathology, Women Medical & Dental College, Abbottabad

³Associate Professor Histopathology, Watim Medical College, Rawat Rawalpindi

⁴Associate Professor Pathology, Rashid Latif Medical College, Lahore

⁵Senior Registrar Gynae & Obs, Shaheed Mohtarma Benazir Bhutto Medical College Lyari / Sindh Govt Lyari General and Teaching Hospital, Karachi

⁶FCPS Gyn Obs, Woman Medical Officer, THQ Hospital Kabal, Swat

Corresponding author: Bushra Adeel, Email: bushraadeel@gmail.com

ABSTRACT

Background: In Gynecology, most of the knowledge circles around the female reproductive tract and uterus has been a vital organ playing central role in female reproductive life cycle both in terms of menstrual and osteoreous cycles. Uterus is subjected to both mechanical and hormonal stresses so uterine pathologies and diseases are the most common pathologies marked in female reproductive systems. These pathologies range from benign uterine pathology to malignancy in many cases. Most of the uterine and cervical pathologies are diagnosed after hysterectomy on histopathological examination only.

Objective: The study was carried out to see histopathological patterns of uterine and cervical lesions in hysterectomy specimens.

Study Design: Histopathology department of Women Medical and Dental College, Abbottabad from August 2021 to August 2022.

Materials and Methods: It was a retrospective study done on hysterectomy samples findings in histopathological examination of uterine and cervical area on 80 specimens over a 1 year period. SPSS latest version was used for DATA.

Results: 80 patients were included based on histopathological reports of the post hysterectomy specimens. Age of patients lies < 30 years to > 60 years. Majority of the cases were between 41-50 years and 51-60 years of the age while patients between 41-50 years age group were 50 %,adenomyosis (09%), atrophied uterus (5%), Hyperplasia (10%), leiomyoma with adenomyosis (18.5%), Leiomyoma (55%) and leiomyosarcoma (2.5%),while cervical pathologies show cervicitis, (62%), cervical dysplasia (21%), cervicitis (papillary) in 07 %, and 10% cases were normal. Different uterine lesions based on the age of the patients show that Leiomyoma is maximally found in patients between 46-60 years and above 60 years of patients and only two cases were marked below 30 Years.

Conclusion: The commonest benign lesion was leiomyoma in uterus followed by adenomyosis combined with leiomyoma, while in cervical canal commonest finding was cervicitis in Hysterectomy specimen.

Keywords: Adenomyosis, Histopathology, Hysterectomy, Leiomyoma, Cervicitis.

INTRODUCTION

Being one of the vital organ in the female body, the uterus is subjected to stressful environment created by hormonal and physical stresses that result in physiological changes responsible for benign and malignant disorders in severe form ⁽¹⁾. Clinical presentation of the morphological changes in the uterus portray complex picture usually apparent in the form of vaginal bleeding or discharges, irregularities in monthly cycle, abdominal pain, urinary problems and often bleeding and sensations of vaginal mass post-menopausal ⁽²⁾. In the reproductive age of the females, the cervix is subjected to many neoplastic and non-neoplastic situations. These conditions lead to high degree morbidity and mortality and exist across all ages in reproductive life ⁽³⁾.

Despite varieties of medical and conservative surgical modalities hysterectomy appears to be most opted decision to tackle these gynecological disorders. In many clinical scenarios like dysfunctional bleeding through uterus, utero-vaginal prolapse, adenomyosis and endometriosis, inflammatory disease in pelvis, others obstetrical complications and gynecological cancers, hysterectomy is the treatment of choice ⁽⁴⁾. All these pathologies need histopathological interventions to diagnose accurately, so every hysterectomy case needs histopathological examination of the specimen collected during surgery. ⁽⁵⁾ This study has been aimed to analyze histopathological and morphological findings in hysterectomy specimens of uterus and cervix received in pathology department for histopathological examination through various tertiary care hospitals.

MATERIAL AND METHOD

A retrospective study on specimens received at Histopathology department of Women Medical and Dental College Abbottabad collected through hysterectomy done at various tertiary care hospitals over a period of one year from August 2021 to August

2022. All the specimens were fixed in 10% formalin as per standard protocol, larger specimens were fixated after cuttings. Fixation of the specimen was done after examination of Gross morphological examination. Multiple representative sections of the specimen were taken, processed and paraffin blocks were made, Hematoxylin and Eosin stains (H & E Staining) were used for staining and histopathological diagnosis was done through microscopic examination.

RESULTS

In the study total 80 patients specimens were included for the study. Ages of patient range from < 30 years to > 60 years. Maximum patients were in the age group 51-60 years (32.5 %) equally balanced by number of patients (32 %) by the age group of 41-50 Years of age. Minimum number of cases were below 30 Years of age (2.5 %.)

Table 1: Age of the hysterectomy patients' for Uterine and Cervical Pathologies

Sr. No.	Age (Years)	No (cases)	%
1	< 30	02	2.5
2	31-40	15	19
3	41-50	25	32
4	51-60	27	32.5
5	> 60	11	14
Total		80	100

Table 2 shows uterine specimens diagnosed for various pathologies, adenomyosis (09%), atrophied uterus (5%), Hyperplasia (10%), leiomyoma with adenomyosis (18.5%), Leiomyoma (55%) and leiomyosarcoma (2.5%) cases.

Table 3 shows the cervical specimens diagnosed for various pathologies, cervicitis, (62%), cervical dysplasia (21%), cervicitis (papillary) in 07 %, and 10% cases were normal.

Table 2: Frequency of Hysterectomy specimens with uterine lesions

Sr. No.	Uterine lesion	No. of cases	Percentage
1	Adenomyosis	07	09
	Atrophied Uterus	04	05
2	Hyperplasia	08	10
3	Leiomyoma with Adenomyosis	15	18.5
4	Leiomyoma	44	55
5	Leiomyosarcoma	02	2.5
	Total	80	100

Table 3: Frequency distribution of Cervical Histopathological findings.

Sr. No.	Cervical Changes	No. of cases	Percentage
1	Cervicitis	51	62
2	Cervical dysplasia	16	21
3	cervicitis (Papillary)	05	07
4	Normal	08	10
	Total	80	100

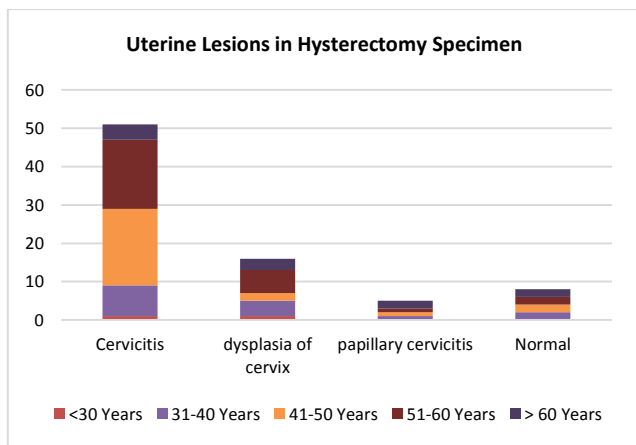


Fig 1: Uterine Lesions in Hysterectomy specimen

Figure 1 shows the uterine lesions % based on the age of the patients, cervicitis cases are predominantly higher in the patients of ages between 41-50 years of age, and 51-60 years of the ages. While dysplasia of cervix was much prevalent in 51-60 Years of ages, less pathologies were found in the patients less than 30 years of the ages.

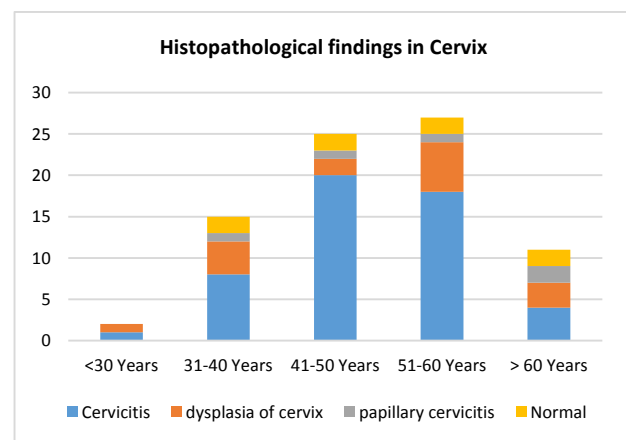


Fig 2: Uterine lesions in Hysterectomy specimen based on age of the patients.

Fig 2 shows the different uterine lesions in hysterectomy specimen based on the age of the patients, Leiomyoma is maximally found in patients between 46-60 years and above 60 years of patients and only two cases were marked below 30 Years.

DISCUSSION

Particularly in Gynecological emergencies (procedures/surgeries), Hysterectomy is usually known as common surgical interventions especially in perimenopausal and post-menopausal females across the globe. History of Hysterectomy is well known by the reference of Charles Clay who was the 1st surgeon performed hysterectomy in England in 1843. It is known as the most successful intervention relieving patients against the post-menopausal bleeding and accidental uterine rupture providing symptomatic relief, establishing patient satisfaction and ultimate remedy in many gynecological emergencies (5). In our study uterine pathologies were maximum in the ages between 51-60 Years of the age, while the most common pathology marked was leiomyoma (55%), adenomyosis (18.5%) on the second number. Cervical pathologies marked in surgical specimen were mostly suffering from cervicitis (62%) while cervical dysplasia in (21%) cases. As the age advances pathological changes become worse and malignant (6). While a study done by Snehal et al India 50% operated patients were found between 41-50 years of age group, same results have been witnessed by Sinha et al. Another study conducted by Ramachandran T et al found the same age group suffering from these pathologies. One of the study conducted by vani et al found the same results with same age group (7). In our study group most common pathology marked was Leiomyoma in uterus and cervicitis in cervical area while the same findings have been marked by Baral R et al and Sreedhar et al (8). Leiomyoma with adenomyosis in uterus and cervical dysplasia is the second most prevalent pathology found in uterine and cervical specimens while in a study conducted by Rizvi et al shows the Adenomyosis the second most common pathology in hysterectomy sample as the adenomyosis has known to be a rare pathology diagnosed preoperatively because clinical course and specified symptoms are muffled and not clear prior to surgery purely on clinical basis (9). Adenomyosis was diagnosed by histopathological examination of hysterectomy specimen only. Adenomyosis has been found along with leiomyoma findings in our study. Study done by Zaid et al found the somewhat similar results regarding leiomyoma with adenomyosis on histopathological examination (10). Same results have been marked by study done by Baral R et al. In our study most common pathology diagnosed on histopathological findings was cervicitis and these results are similar to results verified by Makinen et al (11). Cervical dysplasia was found in 21% patients only three cases were found in a study conducted by Medhi et al. (12). Another study done by Sreedhar et al found mean age of the patients 40-49 years in subtotal hysterectomy patients. In this study majority of the lesions found on histopathological examinations were seen in the endometrium (8). A study done by Imam et al in 2018 found the mean age of the patients was in an age group of 41-50 years, which is observed in our study as well. The commonest histopathological findings in hysterectomy samples was leiomyoma (29.04%) which is also most frequent (52%) in our study followed by adenomyosis which is also second most prevalent condition found in our study but with leiomyoma as well as co-existence. In this study commonest findings in cervical area was chronic cervicitis (91.81%) which is also commonest findings on histopathological examination in our study as well (6). Mallapa et al found the mean age of the patients 46.5±9.4 years in their study. Their study most common hysterectomy procedure was the abdominal approach in their study the most common findings on histopathological finding was proliferative disease of endometrium and myometrium-leiomyoma, cervical pathologies include cervix-chronic cervicitis which is also most common finding in our study as well (13). In a study done in southern Punjab on hysterectomy specimens of peri-menopausal and post-menopausal women found proliferative endometrium the most common histopathological finding in both per-menopausal and post-menopausal women, while hyperplasia of endometrium and endometrial carcinoma were found the least commonest causes (14).

CONCLUSION

Leiomyoma and Leiomyoma with adenomyosis have been found most common pathologies in uterine sample while cervicitis was the commonest cervical pathology in cervical area found on histopathological findings of hysterectomy specimens.

REFERENCES

1. Ayyanar P, Behera G, Mishra TS, Purkait S, Patra S, Mitra S. The clinico-histopathological spectrum of tumors and tumor-like lesions in adult intussusception. *Journal of Gastrointestinal Cancer*. 2022;53(3):511-9.
2. Bindroo S, Garg M, Kaur T. Histopathological spectrum of endometrium in abnormal uterine bleeding. *International Journal of Reproduction, Contraception, Obstetrics and Gynecology*. 2018;7(9):3633-8.
3. Chavhan S, Pathrikar R, Dhoble S, Tiple N. Histopathological spectrum of uterine and cervical lesions in hysterectomy specimens. *J Med Sci Clin Res*. 2018;6(1):32699-701.
4. Forae GD, Aligbe JU. Histopathological patterns of endometrial lesions in patients with abnormal uterine bleeding in a cosmopolitan population. *Journal of Basic and Clinical Reproductive Sciences*. 2013;2(2):101-4.
5. Gowri M, Mala G, Murthy S, Nayak V. Clinicopathological study of uterine leiomyomas in hysterectomy specimens. *Journal of Evolution of Medical and Dental Sciences*. 2013;2(46):9002-10.
6. Imam ZS, Chandra K, Kumar B, Sinha A, Singh A, Singh SK. Histopathological spectrum of hysterectomy specimens--a retrospective analysis at IGIMS, Patna, Bihar. *Journal of Evolution of Medical and Dental Sciences*. 2018;7(30):3352-6.
7. Ramachandran T, Sinha P, Subramaniam. Correlation between clinico-pathological and ultrasonographical findings in hysterectomy. *JCDR*. 2011;5(4):737-40.
8. Sreedhar VV, Jyothi C, Sailaja V, Paul M, Sireesha O, Vani T, et al. Histopathological spectrum of lesions of hysterectomy specimens--a study of 200 cases. *Saudi J Pathol& Microbiol*. 2016;1(2):54-9.
9. Rizvi G, Pandey H, Pant H, Chufal SS, Pant P. Histopathological correlation of adenomyosis and leiomyoma in hysterectomy specimens as the cause of abnormal uterine bleeding in women in different age groups in the Kumaon region: A retrospective study. *Journal of mid-life health*. 2013;4(1):27.
10. Zaid SMO, Thabet MAB. Histopathological findings in hysterectomy specimens: A retrospective study. *Middle east Journal of Internal Medicine*. 2017;10(1):12-24.
11. Mäkinen N, Vahteristo P, Kämpjärvi K, Arola J, Bützow R, Aaltonen LA. MED12 exon 2 mutations in histopathological uterine leiomyoma variants. *European journal of human genetics*. 2013;21(11):1300-3.
12. Medhi P, Dowerah S, Borgohain D. A histopathological audit of hysterectomy: experience at a tertiary care teaching hospital. *Int J Contemp Med Res*. 2016;3(4):1226-8.
13. Mallappa S, Gayathri B, Khatri A, Ramanujam A. A Spectrum of Hysterectomy Findings in a Tertiary Care Hospital, Madikeri. *Disease and Diagnosis*. 2022;11(2):63-8.
14. Kaleem S, Arif A, Hamdani SNR, Syed FN, Afzal K, Saddique S. HISTOPATHOLOGICAL SPECTRUM OF ENDOMETRIUM IN PERIMENOPAUSAL AND POSTMENOPAUSAL WOMEN IN SOUTHERN PUNJAB; AN EXPERIENCE AT TERTIARY CARE HOSPITAL. *Pakistan Journal of Pathology*. 2021;32(2):52-5.