

## ORIGINAL ARTICLE

# ABO Blood Grouping in Partial and Complete Hydatidiform Molar Pregnancy

AFSHEEN ABRO<sup>1</sup>, RUBINA AHMEDANI<sup>2</sup>, SAIMA NAZ SHAIKH<sup>3</sup>, SHEHMEEN KHAN<sup>4</sup>, UROOJ BHATTI<sup>5</sup>, ANDLEEB MUMTAZ SODHAR<sup>6</sup><sup>1</sup>Lecturer Department of Physiology, Bilawal Medical College for Boys, LUMHS, Jamshoro.<sup>2</sup>Associate professor, Physiology department LUMHS Jamshoro<sup>4</sup>Assistant professor Biochemistry department Bilawal medical college Lumhs JAMSHORO<sup>3,5</sup>Assistant professor Physiology department LUMHS Jamshoro<sup>6</sup>Lecturer Biochemistry department in Bilawal medical college LUMHS, JamshoroCorresponding author: Urooj Bhatti, Email: [uroojbhatti@yahoo.com](mailto:uroojbhatti@yahoo.com)

## ABSTRACT

**Objective:** The present study was conducted to analyze the correlation of ABO blood groups in pregnant mother's suffering from partial and complete Hydatidiform mole (HM) reporting at our tertiary care hospital.

**Study Design:** Observational study

**Place and Duration:** Liaquat University Hospital, Hyderabad/Jamshoro from May 2018 to October 2018.

**Methods:** The present observational study analyzed the ABO blood groups of diagnosed cases of partial and complete type HM reporting at the Department of Obstetrics and Gynecology. A sample of 100 pregnant women suffering from Partial and complete HM and of their husbands was studied by inclusion criteria. ABO blood groups of these patients were determined as A, B, AB and O groups. Blood samples were processed for complete blood counts. Tests were performed at the Diagnostic and Research Laboratory, Liaquat University Hospital Hyderabad by forward and reverse ABO blood typing. Severity of GTD was assessed by WHO index score. Statistical comparisons of continuous and categorical variables run on SPSS ver. 21.0 at 95% confidence interval ( $P \leq 0.05$ ).

**Results:** Clinical presenting features bleeding PV, pain, hyperemesis gravidarum, grape like vesicles passage PV, no fetal heart sound, ovarian enlargement and hyperthyroidism. Partial and complete Hydatidiform mole was common in blood group A noted in 53 and 13 respectively. While Partial and complete Hydatidiform mole in blood group O was noted in 20 and 8 patients respectively ( $P=0.0001$ ). The  $\beta$ -hCG ranged from 50,000 to 10,00,000 mIU/mL.

**Conclusion:** It is concluded, the hydatidiform mole proves strong association with blood groups A and O. Pregnant women complaining of bleeding PV, hyperemesis gravidarum, grape like vesicles passage with blood group A and O should be thoroughly investigated to minimize the maternal health risk.

**Keywords:** Hydatidiform mole, Molar pregnancy, ABO blood groups

## INTRODUCTION

Materno – fetal connection plays major role in the development of growing baby as it is the sole route of nutritional supply. On part of fetus, this connection develops from the trophoblastic cells that comprise cytotrophoblast, intermediate trophoblast and syncytiotrophoblast.<sup>1,2</sup> Gestational trophoblastic disease (GTN) is pathological condition of trophoblastic cells of embryo. One of biomarker of GTN is the  $\beta$  – human chorionic gonadotropin ( $\beta$ -hCG) and is diagnostic and specific for trophoblastic proliferation. However, the titers of  $\beta$ -hCG vary for benign and malignant type of GTDs. Some of GTDs synthesize low and others synthesize high  $\beta$ -hCG levels.<sup>1,3</sup> A placental site trophoblastic tumor (PSTT) signifies neoplastic proliferation of intermediate layer of trophoblast. It secretes low levels of  $\beta$ -hCG but high levels of human placental lactogen (hPL).<sup>3</sup> WHO (World Health Organization) classifies GTD into placental site – exaggerated type, placental site – nodule type, PSTT (placental site trophoblastic tumor), partial, complete and invasive Hydatidiform mole (HM), epithelioid trophoblastic tumor (ETT) and malignant type – choriocarcinoma.<sup>3,4</sup> Most common type of GTD is the HM. First mention of HM goes to the Hippocrates (400 BC) that described it as the “dropsy of the uterus”. Prevalence and incidence of GTD varies throughout the globe, occurring due to inconsistent population and hospital-based studies.<sup>5,6</sup> Pregnancy in advance maternal age >40 years shows high incidence of 4.5–5%. HM accounts for 10–34% in adolescent cases in referral centers.<sup>5-7</sup> Since the discovery of ABO blood antigens, it has been reported as a risk factor for ischemic heart diseases, coronary atheroma, peptic ulcer, gastric carcinoma, diabetes mellitus and tooth diseases, etc.<sup>8,9</sup> Gertler and White (1954 AD) firstly mentioned the ABO blood antigens are a non-modifiable minor risk factor of Ischemic heart diseases, was first studied.<sup>5-9</sup> Only a few published studies<sup>7-9</sup> have reported association of GTD to ABO blood groups. ABO pairing of mother and father blood antigens as risk of GTD was investigated in a case-control study. That previous study included 286 pregnant mothers and positive link was found with certain ABO blood group antigens, it was concluded the ABO blood group antigens were associated with GTD risk. GTD risk increased

in those with age >35 years.<sup>9</sup> Thus the link of ABO blood group antigens was related to the development of GTD. Particularly, GTD risk is observed in those where blood group A mothers are married to blood group O men.<sup>8,9</sup> Considering ABO blood group antigens may benefit as new paradigm of diagnostic marker in GTD patients. The present study was conducted to analyze the incidence of ABO blood groups in relation to partial and complete Hydatidiform mole pregnancy in pregnant mothers presenting at our tertiary care hospital.

## SUBJECTS AND METHODS

The present observational study was conducted at the Department of Physiology, Obstetrics and Gynecology, Liaquat University Hospital, Hyderabad/Jamshoro from May 2018 to October 2018. Study proposed to analyze the ABO blood groups of diagnosed cases of partial and complete type Hydatidiform mole (HM) reporting at our tertiary care hospital. Ethics of conducting study was in accordance to the declaration of Helsinki's for human research. Study protocol was approved by the ethical review committee of institute. A sample of 100 pregnant women suffering from Partial Hydatidiform mole (PHM) and complete Hydatidiform mole (CHM) and of their husbands was studied by inclusion criteria. Cases of PHM and CHM were diagnosed by a Consultant Obstetrician and Gynecologist. Consent was taken from all participants and full – volunteers were recruited in study protocol. A sample of 100 pregnant women suffering from Partial and complete HM and of their husbands was studied by inclusion criteria. Abnormal vaginal bleeding during first trimester of pregnancy, hyperemesis gravidarum, uterus enlargement more than expected duration of gestation, no fetal heart sounds, ovarian cystic enlargement and elevated  $\beta$  – human chorionic gonadotropin ( $\beta$ -hCG) level for gestational age. Sonography was performed for the findings of diffuse mixed echoes replacing placenta were included. Exclusion criteria were; normal pregnancy, normal  $\beta$ -hCG levels, normal sonography findings and normal pregnancy of >6 months. Selected sample was taken a through clinical history, examined by a consultant gynecologist, and volunteers were asked for blood sample collection. 5 ml blood was

drawn from ante – cubital vein; 2 ml put in EDTA containing CP bottle and remaining put in plain bottle. ABO blood groups of these patients were determined as A, B, AB and O groups by forward and reverse ABO blood typing. ABO blood typing comprised of 2 – steps, a forward and a reverse blood typing. Complete blood count sample was taken in EDTA containing tubes. Blood sample was collected both from pregnant women and their husbands and processed for complete blood counts on hematology analyzer. Clinical laboratory tests were performed at the Diagnostic and Research Laboratory, Liaquat University Hospital Jamshoro/Hyderabad. A proforma was filled of patient's data as the general Biodata, vital signs, life-style, past medical, menstrual and obstetric history. Statistical comparisons of continuous and categorical variables run on SPSS ver. 21.0. Results of continuous variables were presented as mean  $\pm$  SD using Student's t – test. Categorical variables were cross – tabulated using Chi – square test. Level of significance was taken at 95% confidence interval ( $P \leq 0.05$ ).

## RESULTS

Age distribution of study sample is shown in table – 1. Thirty-three (33) partial HM and 11 complete HM were in their 4<sup>th</sup> decade. Patients in 2<sup>nd</sup>, 3<sup>rd</sup> and 5<sup>th</sup> decade are shown in table 1. Fifty one (51) partial HM and 9 complete HM were in first trimester, while 25 partial HM and 15 complete HM were in second trimester ( $P=0.0001$ ). Clinical presenting features – pain, bleeding PV, hyperemesis gravidarum, grape like vesicles passage PV, no fetal heart sound, ovarian enlargement and hyperthyroidism are shown in table – 3. Partial and complete HM were common in blood group A noted in 53 and 13 respectively. Partial and complete HM in blood group O was noted in 20 and 8 patients respectively ( $P=0.0001$ ). 1 – 2 cases of partial and complete HM were found in blood group B and AB (table – 4 and graph – 1). The  $\beta$ -hCG (mIU/mL) levels are shown in table – 5 and graph – 2. The  $\beta$ -hCG ranged from 50,000 to 10, 00,000 mIU/mL.

Table 1: Age distribution of study sample

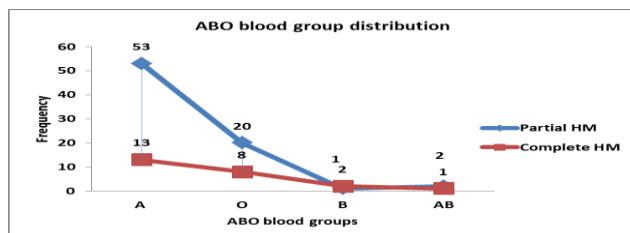
Age (years)	Partial HM (n=76)	Complete HM (n=24)
<19.9	3	1
20 - 29.9	19	5
30 - 39.9	33	11
>40	21	7
Total	76	24

Table 2: Trimester wise distribution of study sample

	Partial HM	Complete HM	P-value
I	51	9	0.0001
II	25	15	
III	0	0	
Total	76	24	

Table 3: Clinical presentation of study sample

	Partial HM (n=76)	Complete HM (n=24)
Pain	13	15
Bleeding PV	71	21
Hyperemesis gravidarum	70	23
Grape like vesicles	31	19
No fetal heart sound	9	0
Ovarian enlargement	19	23
Hyperthyroidism	01	00



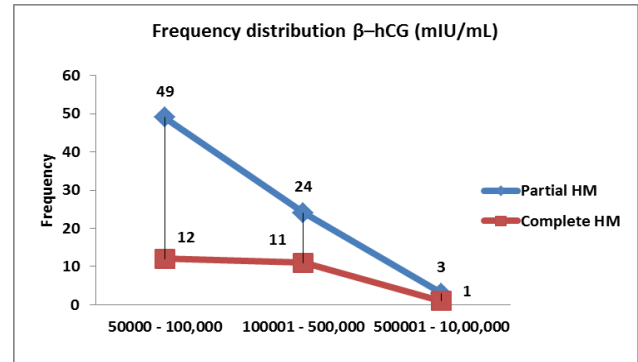
Graph 1: ABO blood group distribution of study sample

Table 4: ABO blood group distribution of study sample

	Partial HM (n=76)	Complete HM (n=24)	P-value
A	53	13	( $P=0.0001$ )
O	20	8	( $P=0.0001$ )
B	1	2	
AB	2	1	
Total	76	24	

Table 5:  $\beta$ -hCG (mIU/mL) levels

	Partial HM	Complete HM	P-value
50000 - 100,000	49	12	( $P=0.0001$ )
100001 - 500,000	24	11	
500001 - 10,00,000	3	1	
Total	76	24	



Graph 2:  $\beta$ -hCG (mIU/mL) levels in partial and complete Hydatidiform mole

## DISCUSSION

Gestational trophoblastic disease (GTD) encompasses spectrum of proliferating trophoblastic cells of benign to invasive levels. Hydatidiform mole is benign proliferating trophoblastic tissue that may be partial or complete. In partial HM, fetal tissue is often present whilst in complete HM, fetal tissue is totally absent. Pregnancy associated trophoblast proliferation may progress to serious malignant choriocarcinoma that is highly fatal.<sup>10</sup> The present study analyzed the association of ABO blood groups with partial and complete HM and found frequent occurrence in blood group A and O. Few cases of HM were observed in B and AB blood groups. Occurrence of GTD varies according to geographical variations; this may be because of case detections, health facilities provision, research methodology, imaging bias, laboratory investigations, etc.<sup>10-12</sup> The present study investigated the clinical presentation, association with ABO blood groups and  $\beta$ -hCG hormonal changes in partial and complete Hydatidiform mole. During the study period we could collect 100 cases; 76 proved partial and 24 proved complete Hydatidiform mole, large number of cases were collected because our tertiary care hospital caters is providing health services to millions populations of Sindh. We did not find any extra uterine GTD – Hydatidiform mole. We found majority of cases were in first trimester as seen in 42 (59.15%) cases and 29 (40.85%) cases were in second trimester that is in association to previous studies.<sup>13,14</sup> Taboo et al<sup>13</sup> and Fatima et al<sup>14</sup> have reported frequent incidence of GTD – Hydatidiform mole in first trimester. In present study, presenting clinical features were pain, bleeding PV, hyperemesis gravidarum, grape like vesicles passage PV, no fetal heart sound, ovarian enlargement and hyperthyroidism, the findings are in keeping with previous studies.<sup>13-17</sup> Finding of grape like masses per vaginam is consistent with a previous study.<sup>10</sup> In the present study most common presentation was bleeding per vagina with 73 (94.80%) cases, followed by amenorrhea with 71 (92.0%) cases, the findings are consistent with previous studies.<sup>12,14,16</sup> In present study, the bleeding per vagina was noted in 94.80% that is consistent with a previous study by Fatima M et al that have reported bleeding PV in 94.20% cases.<sup>15</sup> In the present study, one patient presented

complaining bleeding PV associated with sweating, palpitations and tachycardia, the finding is highly consistent with a previous study from India.<sup>17</sup> Walkington et al<sup>18</sup> reported 2% cases of hyperthyroidism in GTD and Singh et al<sup>19</sup> reported 2.20% hyperthyroidism in their study. In present study, the  $\beta$ -hCG (mIU/mL) levels are shown in table – 5 and graph – 2. The  $\beta$ -hCG ranged from 50,000 to 10, 00,000 mIU/mL, these findings are in keeping with previous studies.<sup>19-22</sup> In present study, partial and complete HM were common in blood group A noted in 53 and 13 respectively followed by blood group O noted in 20 and 8 patients respectively ( $P=0.0001$ ). 1 – 2 cases of partial and complete HM were found in blood group B and AB respectively (table – 4 and graph – 1). The findings are in line with previous studies.<sup>10-17</sup> Parazzini F et al<sup>20</sup> reported GTD – Hydatidiform mole is positively associated with A and O blood groups. Previous studies<sup>10,17,20</sup> stated GTD is prevalent in blood group A and O that is consistent with present study. Similar results are stated in other previous studies.<sup>17,23,24</sup> We conclude, the hydatidiform mole is associated with ABO blood group system and further research is demanding to make national data available for preventable cause of materno – fetal loss.

## CONCLUSION

It is concluded, every pregnancy must be supervised carefully by imaging and laboratory investigations to rule out the gestational trophoblastic disease (GTD) for safe motherhood. Hydatidiform mole was found associated with blood groups A and O frequently. Pregnant women complaining of bleeding PV, hyperemesis gravidarum, grape like vesicles passage PV, no fetal heart sound and ovarian enlargement having blood group A and O should be thoroughly investigated for gestational trophoblastic disease.  $\beta$ -hCG (mIU/mL) is highly specific laboratory investigation that should be advised to pregnant women suspicious of gestational trophoblastic disease. Further nationwide studies are recommended to validity association of ABO blood groups to minimize the maternal health risk.

## REFERENCES

1. Soper, John T. MD Gestational Trophoblastic Disease *Obstetrics & Gynecol* 2021; 137 (2): 355-370 doi: 10.1097/AOG.0000000000004240.
2. Ning F, Hou H, Morse AN, Lash GE. Understanding and management of gestational trophoblastic disease. *F1000Res* 2019; 8:F1000 Faculty Rev-428. doi:10.12688/f1000research.14953.1.
3. Prabhu I K, Rosenbaum A (September 08, 2020) Hydatidiform Mole in a Patient With a Concern for Neoplasia: A Case Report. *Cureus* 12(9): e10319. doi:10.7759/cureus.10319.
4. Kim SJ. "Placental site trophoblastic tumor," *Bailliere's Best Practice and Research 'In Clinical Obstetrics and Gynaecology* 2003; 17 (6): 969–984.
5. Braga A, Growdon WB, Bernstein M, Maesta I, Rudge MV, Goldstein DP, et al. Molar pregnancy in adolescents. *J Reprod Med* 2012; 57 (5–6): 225–230.
6. Elias KM, Shoni M, Berstein M, Goldstein DP, Berkowitz RS. Complete hydatidiform mole in women aged 40 to 49 years. *J Reprod Med* 2012; 57 (5–6): 254–258.
7. Soares PD, Masesta I, Costa OL, Charry RC, Dias A, Rudge MV. Geographical distribution and demographic characteristics of gestational trophoblastic disease. *J Reprod Med* 2010; 55 (7–8): 305–310.
8. Bronte-Stewart B, Botha M, Krut L. ABO blood groups in relation to ischaemic heart disease. *British Med J* 1962;1(5293):1646.
9. Dilixiati N, Sui S, Ge X, Tuerxun D, Huang Y. Relationship between ABO blood groups and gestational hypertensive disorders: A protocol for systematic review and meta-analysis. *Medicine (Baltimore)* 2021; 100(18):e25573. doi:10.1097/MD.00000000000025573.
10. Lurain JR. Gestational trophoblastic disease: epidemiology, pathology, clinical presentation and diagnosis of gestational trophoblastic disease, and management of hydatidiform mole. *Am J Obstet and Gynecol* 2010; 203(6):531-39.
11. Deep JP, Sedhai LB, Napit J, Pariyar J. Gestational trophoblastic disease. *J Chitwan Medical College* 2013;3(4):4-11.
12. Berkowitz RS, Goldstein DP. In: Berck JS. *Gestational trophoblastic neoplasia*. Philadelphia, Lipincott, Williams and Wilkins 2002;1353-74.
13. Taboo ZA. A prospective study of gestational trophoblastic disease in Al-Mosul City. *The Iraqi Post-graduate Med J* 2013;12(2):268-76.
14. Fatima M, Kasi PM, Baloch SN. Incidence, management, and outcome of molar pregnancies at a tertiary care hospital in Quetta, Pakistan. *ISRN Obstet Gynecol* 2011; 2011:925316.
15. Yakasai I, Abubakar I, Eze Y. Gestational trophoblastic disease in a teaching hospital in Northern Nigeria. *Am J Bio Sci*. 2015;3(1):7-10.
16. Chhabra S, Sinha P. Gestational trophoblastic disease- some observations. *J Obstet and Gynecol India* 1988; 38:590-93.
17. Jagtap SV, Aher V, Gadhiya S, Jagtap SS. Gestational Trophoblastic Disease - Clinicopathological Study at Tertiary Care Hospital. *J Clin Diagn Res* 2017; 11(8): EC27-EC30.
18. Walkington L, Webster J, Hancock BW, Everard J, Coleman RE. Hyperthyroidism and human chorionic gonadotrophin production in gestational trophoblastic disease. *Br J Cancer* 2011; 104:1665-69.
19. Singh N, Singh U, Srivastava S. Prospective and retrospective analysis of [21] gestational trophoblastic disease over a period of 5 years. *J South Asian Federation of Obst and Gynec* 2013;5(1):11-14.
20. Parazzini F, La Vecchia, Franceschi S, Pampallona S, Decarli A, Mangili G, et al. ABO blood groups and risk of gestational trophoblastic disease. *Tumour* 1985; 71:123-26.
21. Harriet OS. Gestational trophoblastic disease epidemiology and trends. *Clin Obstet Gynecol* 2003; 46(3):541-56.
22. Muller C, Cole L. The quagmire of hCG and testing HCG in gynecologic oncology. *Gynecol Oncol* 2008; 9:1-12.
23. Kamine U, Gulfem B, Ahmet K, Igor L. Gestational trophoblastic diseases – diagnosis and risk factors: A case series. *Int J Med Rev Case Rep*. 2019; 3(8): 528-532.