

## ORIGINAL ARTICLE

# Outcomes of Intraplaque Verapamil Injection for Treatment of Peyronie's Disease

KHALID HUSSAIN<sup>1</sup>, BILAL AHMED<sup>2</sup>, MARIA TARIQ<sup>3</sup>, AZEEM AHMED<sup>4</sup>, BILAL AKHTAR<sup>5</sup><sup>1</sup>Professor and Head Department of Urology DHQ Teaching Hospital Gujranwala<sup>2,3,4,5</sup>DHQ Teaching Hospital GujranwalaCorrespondence to: Khalid Hussain, Email: [Khaliduro@yahoo.com](mailto:Khaliduro@yahoo.com), Cell: 0321 4428903

## ABSTRACT

**Objective:** To determine the outcomes of intraplaque verapamil injection for treatment of Peyronie's disease.**Aim:** The purpose of this study is to evaluate the outcomes & efficacy of intraplaque verapamil injection in Peyronie's disease management.**Methods:** The quasi experimental study was conducted from July 2018 to July 2019 on a group of 26 subjects suffering from Peyronie's disease. After detailed history, complete physical and genital examination, the diagnosis was confirmed. After informed consent, questionnaires regarding pain and sexual satisfaction of patients were filled. All patients received verapamil injections on weekly basis for a period of 10 weeks. After that, all necessary variables were recorded and data analyzed using SPSS version 16.**Results:** Most of the patients in our study were in the age group of 30-65 years. 26.9 % patients were in the range of 51-55 years old. 53.8% patients got no effect of intralesional injection of verapamil on pain while pain relieved in 38.5% of patients & 7.7% patients experienced an increased in pain intensity after 10 weeks of intralesional injection of verapamil. 61.5% of patients satisfied with their sexual life after 10 week of injections & 30.8% of patients remained unsatisfied with their sexual life while in 7.7% of patients symptoms aggravated. 53.8% of patients experienced no change in size of lesion and curvature of penis, while 30.8% got less than 50% reduction in size of lesion while 15.4% of patients got more than 50% reduction in size after 10 weeks. Practical implication: We can easily find the efficacy of Verapamil injection for management of Peyronie's disease.**Conclusion:** This study concluded the efficacy of Verapamil injection for management of Peyronie's disease causes significant decrease in size of lesion and improvement in sexual activity.**Keywords:** Peyronie's disease, Improvement, Lesions, Significant

## INTRODUCTION

Painful erection, erectile dysfunction, penile induration and curvature of the penile shaft are the main presenting complaints of Peyronie's Disease.<sup>1,2</sup> Certain factors leading to erectile dysfunction including flail penis, severe deformities of penile shaft, impaired blood flow, stress and anxiety has an incidence of 30% in Peyronie's Disease.<sup>3,4</sup> Major contributing factors are penile trauma during sexual intercourse and sudden penile curvature, however etiology is unknown.<sup>5,6</sup> Patients with severe deformity required surgical procedures, but majority of them were managed conservatively.<sup>7</sup> There are many treatment options like drugs including Tamoxifen, para-amino benzoic acid, colchicine and Vitamin E used orally and injectable like collagenase, interferon, verapamil and steroids. No treatment showed satisfactory results including surgical intervention. However, verapamil injection showed promising results in a number of studies. It was used for the first time in 1994 as an intralesional injection for treatment of Peyronie's Disease. Being a calcium antagonist, it affects the fibroblast genesis in extra cellular matrix. Verapamil has a significant role in the metabolising extra cellular matrix by inhibition of collagen product and increasing collagenase activity. Antagonists of calcium channels alter the secretion of interleukins 8 and 6, cytokines and plaque growth factor; and inhibit the inflammatory process and fibrotic tissue formation. Therefore, Verapamil injection (calcium channel blocker) is enough potent to reduce, invert and inhibit the development and formation of plaque of Peyronie's Disease.<sup>7,8</sup> The aim of our study was to evaluate the outcomes and efficacy of intraplaque verapamil injection for Peyronie's disease management.

## SUBJECTS AND METHODS

The quasi experimental study was conducted from July 2018 to July 2019 on a group of 26 subjects suffering from Peyronie's disease. Patients meeting the inclusion criteria (having disease for last 6 months) added in the study. Exclusion criteria of our study included patients having co-morbidities like CKD, CLD, Ischemic

disease and diabetes mellitus and patients undergone multiple interventions for Peyronie's disease. Patients having diffuse fibrotic plaque and acute stage of disease were also excluded in our study. 26 patients following inclusion criteria were enrolled in our clinical trial. After detailed history, complete physical and genital examination, the diagnosis was confirmed. After informed consent, questionnaires regarding pain and sexual satisfaction of patients were filled. Scale was used to measure the lesion size and X-ray determined the extent of fibrous plaque. For measuring the penile curvature after erection, the image of penis was taken and shown to physician by the patient himself. Visual analogue scale was used to determine the patient satisfaction regarding sexual activity on start of treatment and after every week. Then, patients got Verapamil injection 10mg/cm<sup>2</sup> weekly for 10 weeks. We used multiple puncture technique that delivered injection verapamil evenly through the plaque. Eventually, data were analyzed using SPSS version 16.

## RESULTS

Most of the patients in our study were in age group of 30-65 years, 26.9 % patients were in the range of 51-55 years old. 53.8% patients got no effect of intralesional injection of verapamil on pain while pain relieved in 38.5% of patients & 7.7% patients experienced an increased in pain intensity after 10 weeks of intralesional injection of verapamil. 61.5% of patients satisfied with their sexual life after 10 week of injections & 30.8% of patients remained unsatisfied with their sexual life while in 7.7% of patients symptoms aggravated. 53.8% of patients experienced no change in size of lesion and curvature of penis, while 30.8% got less than 50% reduction in size of lesion while 15.4% of patients got more than 50% reduction in size after 10 weeks. Adverse effects observed in patients treated with intralesional verapamil were as follows: dizziness in 02 patients, weakness in 06 patients, nausea in 04 patients, bradycardia in 01 patient and sweating in 05 patients. Results with pie charts and tables are demonstrated below.

Table 1: Descriptive Statistics

	N	Range	Minimum	Maximum	Sum	Mean	Std. Deviation	Variance
	Statistic	Statistic	Statistic	Statistic	Statistic	Statistic	Statistic	Statistic

AgeDistributuion	26	6.00	.00	6.00	98.00	3.7692	.30538	1.55712	2.425
Effect of Intralesional Injection of verapamil on Pain after 10 weeks	26	2.00	.00	2.00	18.00	.6923	.12114	.61769	.382
Sexual Satisfaction of Patients after 10 weeks of Intralesional Verapamil	26	2.00	.00	2.00	12.00	.4615	.12686	.64689	.418
Effect of Intralesional Injection of verapamil on curvature and lesion size after 10 weeks	26	2.00	.00	2.00	16.00	.6154	.14756	.75243	.566
Valid N (listwise)	26								

Table 2: AgeDistributuion

		Frequency	Percent	Valid Percent	Cumulative Percent
Valid	Below 30 Yeas Old	1	3.8	3.8	3.8
	31-35 Yeas Old	1	3.8	3.8	7.7
	36-40 Yeas Old	3	11.5	11.5	19.2
	41-45 Yeas Old	6	23.1	23.1	42.3
	46-50 Yeas Old	5	19.2	19.2	61.5
	51-55 Yeas Old	7	26.9	26.9	88.5
	Above 56 Yeas Old	3	11.5	11.5	100.0
	Total	26	100.0	100.0	

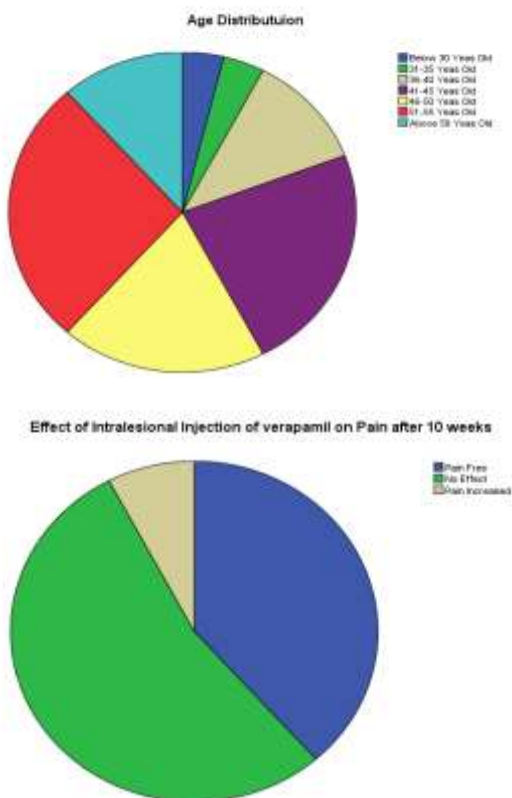


Figure 1:

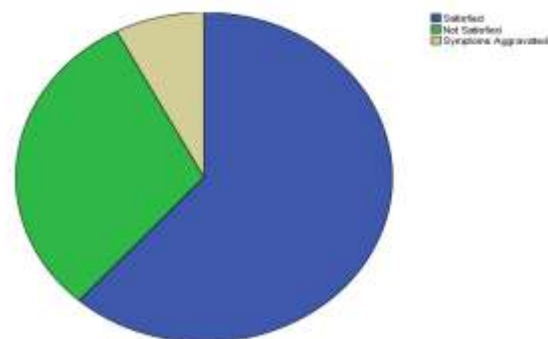
Table 3: Effect of Intralesional Injection of verapamil on Pain after 10 weeks

		Frequency	Percent	Valid Percent	Cumulative Percent
Valid	Pain Free	10	38.5	38.5	38.5
	No Effect	14	53.8	53.8	92.3
	Pain Increased	2	7.7	7.7	100.0
	Total	26	100.0	100.0	

Table 4: Sexual Satisfaction of Patients after 10 weeks of Intralesional Verapamil

		Frequency	Percent	Valid Percent	Cumulative Percent
Valid	Satisfied	16	61.5	61.5	61.5
	Not Satisfied	8	30.8	30.8	92.3
	Symptoms Aggravated	2	7.7	7.7	100.0
	Total	26	100.0	100.0	

Sexual Satisfaction of Patients after 10 weeks of Intralesional Verapamil



Effect of Intralesional Injection of verapamil on curvature and lesion size after 10 weeks

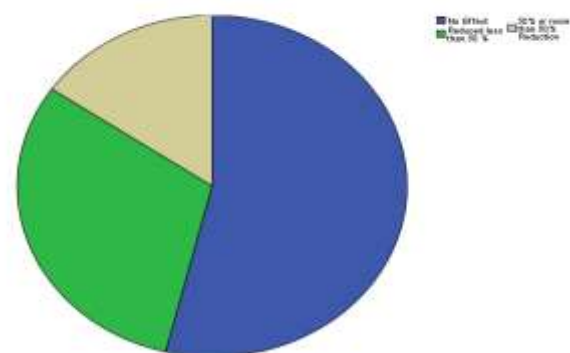


Figure 2:

Table 5: Effect of Intralesional Injection of verapamil on curvature and lesion size after 10 weeks

		Frequency	Percent	Valid Percent	Cumulative Percent
Valid	No Effect	14	53.8	53.8	53.8
	Reduced less than 50 %	8	30.8	30.8	84.6
	50% or more than 50% Reduction	4	15.4	15.4	100.0
	Total	26	100.0	100.0	

Table 6: Adverse events observed in our study

No.	Adverse Event	No. of Patients	Severity	Action Taken	Expected?	Time of onset?
1.	Dizziness	02	Mild	Conservative	Expected	Immediate after Injection
2.	Weakness	06	Mild	Conservative	Expected	Immediate after Injection
3.	Nausea	04	Mild	Conservative	Expected	Immediate after Injection
4.	Bradycardia	01	Mild	Conservative	Expected	Immediate after Injection
5.	Sweating	05	Mild	Conservative	Expected	Immediate after Injection

## DISCUSSION

Patients in our study were mostly in age group of 35-55 years, study done in Minnesota also shown similar results,<sup>9</sup> where with the incidence of 0.4% with the mean age of onset of Peyronie's disease was 53 years. There are number of management options including oral and injectable are available and have been reported for Peyronie's disease, like steroids, vitamin E, intra plaque injection of calcium channel blocker, steroids and interferons. weekly administration and easy to administer are main benefits of injectable therapy. There are several severe adverse effects of use of steroids such as eye problems, hypertension, immunosuppression, dermatological manifestations, and osteoporosis. Skin atrophy at injection site may happens as a result of local instillation of steroids along with above mentioned side effects.<sup>10</sup> Gol Bard and colleagues in 1993 done a study on forty nine patients having Peyronie's disease intraplaque injection of collagenase is more effective as compared to placebo. Interferon has role in formation of collagenase production and inhibition of fibroblast proliferation.<sup>12</sup> but due to cost effectiveness and some adverse effects like hypotension, GI Disorders and flu like symptoms.<sup>13-15</sup> Calcium antagonists proved beneficial in many studies in reduction and development of plaque formation in Peyronie's Disease.<sup>7, 16, 17</sup>

For lesion size of more than 2cm<sup>2</sup> less desirable results and poor response to treatment because of ring like lesion along the penis. Levin et al (1997) in University of Ohio conducted a study on forty six patients, 72 % improvements in sexual satisfaction and reduction of penile curvature by 54% was reported.<sup>16</sup> our findings provide more acceptable results as compared with previous studies. Levin et al published a study on one hundred and fifty six patients with Peyronie's disease and reported that intra plaque injection of verapamil reduced the penile curvature by 60% and improved the sexual satisfaction.<sup>17</sup> Rehman et al (1998) reported 57% decrease in plaque size as compared to control group which was 28% and reduction of penile curvature about 30% was reported. Improvement in sexual activity in patients and findings in our clinical trial is comparable with previous findings. In 2006, Helstrom in Florida University performed a study on fourteen patients, observed that 71% patients significantly improved their sexual activities and 62% patients reported reduction in penile curvature.<sup>19</sup> Difference between outcomes of intralesional injections in our study and previous study is due to size of lesion. In other studies, smaller lesion size was observed as compared to our patients. It may also be due to limited sample size in our study. However, intralesional injection of verapamil have significant role in management of peyronie's disease, need more studies in this aspect.

## CONCLUSION

The conclusion of our study is that intralesional injection of verapamil in lesion of Peyronie's disease causes significant decrease in size of lesion and improvement in sexual activity.

## REFERENCES

- Campbell MF, Walsh PC, Retik AB. Campbell's urology. 8th ed. Philadelphia: Saunders, 2002.
- Peyronie DL. Sur quelques obstacles qui s'opposent à l'éjaculation naturelle de la semence. *Mem Acad R Chir* 1743; 1: 425-34.
- Pryor JP. Peyronie's disease and impotence. *Acta Urol Belg* 1988; 56: 317-21.
- Weidner W, Schroeder-Printzen I, Weiske WH, Vosschenrich R. Sexual dysfunction in Peyronie's disease: an analysis of 222 patients without previous local plaque therapy. *J Urol* 1997; 157: 325-8.
- Furey CA. Peyronie's disease: a treatment by the local injection of meticortelone and hydrocortisone. *J Urol* 1957; 77: 251-66.
- Jarow JP, Lowe FC. Penile trauma: an etiologic factor in Peyronie's disease and erectile dysfunction. *J Urol* 1997; 158: 1388-90.
- Levine LA, Merrick PF, Lee RC. Intralesional verapamil injection for the treatment of Peyronie's disease. *J Urol* 1994; 151: 1522-4.
- Gomella LG. Impotence -- defining the role of minimally invasive therapy. *J Urol* 1996; 155: 147.
- Lindsay MB, Schain DM, Grambsch P, Benson RC, Beard CM, Kurland LT. The incidence of Peyronie's disease in Rochester, Minnesota, 1950 through 1984. *J Urol* 1991; 146: 1007-9.
- Winter CC, Khanna R. Peyronie's disease: results with dermo-jet injection of dexamethasone. *J Urol* 1975; 114: 898-900.
- Gelbard MK, James K, Riach P, Dorey F. Collagenase versus placebo in the treatment of Peyronie's disease: a double-blind study. *J Urol* 1993; 149: 56-8.
- Duncan MR, Berman B, Nseyo UO. Regulation of the proliferation and biosynthetic activities of cultured human Peyronie's disease fibroblasts by interferon-alpha, -beta, and -gamma. *Scand J Urol Nephrol* 1991; 25: 89-94.
- Dang G, Matern R, Bivalacqua TJ, Sikka S, Hellstrom WJ. Intralesional Interferon-alpha-2B injections for the treatment of Peyronie's disease. *South Med J* 2004; 97: 42-6.
- Wegner HE, Andresen R, Knipsel HH, Miller K. Treatment of Peyronie's disease with local interferon-alpha-2b. *Eur Urol* 1995; 28: 236-40.
- Wegner HE, Andresen R, Knipsel HH, Miller K. Local interferon-alpha-2b is not an effective treatment in early-stage Peyronie's disease. *Eur Urol* 1997; 32: 190-3.
- Levine LA. Treatment of Peyronie's disease with intralesional verapamil injection. *J Urol* 1997; 158: 1395-9.
- Levine LA, Goldman KE, Greenfield JM. Experience with intraplaque injection of verapamil for Peyronie's disease. *J Urol* 2002; 168: 621-5.
- Rehman J, Benet A, Melman A. Use of intralesional verapamil to dissolve Peyronie's disease plaque: a long-term single-blind study. *Urol* 1998; 51: 620-6.
- Hellstrom WJ, Kendirci M, Matern R, Cockerham Y, Myers L, Sikka SC, et al. single-blind, multicenter, placebo controlled, parallel study to assess the safety and efficacy of intralesional interferon a-2b for minimally invasive treatment for Peyronie's disease. *J Urol* 2006; 176: 394-8.