

ORIGINAL ARTICLE

Our Experience with Laparoscopic Appendectomy at the Department of Pediatric Surgery LRH Peshawar

MUHAMMAD YOUNAS KHAN¹, SYED ASAD MAROOF², FAYAZ IQBAL³, WARDAH SALEEM⁴, MUHAMMAD SHOAIB⁵, KIFAYAT⁶

¹Assistant Professor pediatric surgery MTI/LRH Peshawar

²Assistant Professor General Surgery Khyber Teaching Hospital Peshawar

³MBBS, Resident surgeon, NICVD, Karachi

⁴MBBS, Resident, surgeon Pediatric Surgery MTI/LRH, Peshawar.

⁵MBBS, Resident, surgeon Pediatric Surgery MTI/LRH, Peshawar

⁶Professor Pediatric Surgery Lady Reading Hospital, Peshawar

Correspondence to: Syed Asad Maroof, Email: maroofasad@yahoo.com

ABSTRACT

Aim and Objective: This study aims to determine the effectiveness of laparoscopic appendectomy for children performed as emergency or emergency surgery at MTI/LRH in Peshawar, Pakistan.

Material & Methods: From January 2020 to December 2022, the Department of Pediatric Surgery, Medical Teaching Institute, Lady Reading Hospital Peshawar studied acute appendicitis in children. This study comprised children with clinically confirmed acute appendicitis as indicated by blood complete, HBs Ag, HCV, ultrasound, and primary assessment. The pediatric surgical unit maintained direct resuscitation of patients' NPO for at least 6 hours, began antibiotics, and performed laparoscopic surgery under general anesthesia. This strategy avoids additional treatment, saves time and money, reduces hospital-acquired infections and other hospital dangers, and allows for excellent local infection control without pus spreading throughout the peritoneal cavity. Laparoscopic surgery makes cholecystectomy a few-day procedure instead of a week. Laparoscopic appendectomy reduces hospital stays for children. Thus, we examined our data to determine whether children may have an emergency or same-day laparoscopic appendectomy (24-hour postoperative stay). We reviewed all three-year-olds who underwent laparoscopic appendectomy for suspected appendicitis.

Results: Acute appendicitis afflicted 79 children, 4/1 male-to-female. 79 2- to 16-year-olds underwent laparoscopic appendectomy surgeries. 5% of children after laparoscopic appendectomy developed perforated appendicitis and needed an open appendectomy. Forty-one (64.5%) had severe appendicitis before surgery. 22 (27.2%) had perforated appendicitis, (5%) had ovarian cyst rupture, and 2.5% had no pathology. Surgery averaged 54 minutes. 14 of 79 primary wound closure patients had their right lower quadrant peritoneal cavity emptied. All 79 patients underwent successful appendectomy operations. Wound infection (6 patients) and stomach pain (4 patients) were the most prevalent sequelae managed conservatively. Four patients required readmission and laparotomy due to intestinal obstruction and other issues. Thirty-two children were released within 24 hours after laparoscopic appendectomy. The control group had no significant morbidity (drug rash, 1; fever, 3).

Practical implication: This study will provide the data on the effectiveness of the laparoscopic appendectomy for the treatment of Appendicitis.

Conclusion: Our study shows that the current laparoscopic appendectomy method for treating adorable appendicitis in children is safe and may be performed as a fast-track or same-day operation with a postoperative stay of fewer than 24 hours in some children who do not have perforated appendicitis.

Keywords: Laparoscopic appendectomy, Pediatric Laparoscopy, fast-track same-day surgery

INTRODUCTION

Fitz.1 coined appendicitis. Morton conducted the first US deliberate appendectomy for a ruptured appendix in 1887¹. McBurney² reported in 1889 that "the seat of maximal pain. has been pretty precisely between an inch and a half and two inches from the anterior spinous process of the ilium on a straight line drawn from the process to the umbilicus" following appendectomy before rupture. McBurney point². Modern surgery and medicines make this ailment seldom fatal. Appendicitis, the most common abdominal surgery, is still contested. In the ninth week, the inferior tip of the cecum becomes the appendix³. The appendix travels to the posteromedial side of the cecum, 2 cm below the ileocecal valve, in late infancy⁴. The appendix tip is pelvic 30% of the time, 65% behind the cecum, and 5% extraperitoneal in the retro cecum or retrocecal position. 6 0.3–33 cm, the appendix averages 8 cm. 5–10 mm appendix diameter⁵. The terminal ileum receives blood from the appendiceal branch of the ileocolic artery 4 in 100,000 have appendiceal duplication. Appendix function unknown. Mammals seldom have primate appendices B cells may increase in rabbits' appendixes⁶.

250,000 US cases cause one million hospital days. 10 Appendicitis incidence varies by place, although it has grown internationally during the last 50 years for unclear reasons. 11 8.6% of males and 6.7% of women will suffer from appendicitis⁷. 12 Rare third-world appendicitis. Open appendectomy is costly. Inflammation hinders appendectomy. We examined the laparoscopic treatment of acute appendicitis in children who tried the curative intervention in sensitive inflammatory faces at admission and follow-up problems. Laparoscopic gastric

fundoplication and cholecystectomy are popular^{8,13}. Gans15 pioneered pediatric laparoscopic surgery in 1973. Semm¹⁷ described laparoscopic appendectomy in 1983. Laparoscopic appendectomy (LA) is more expensive than open appendectomy (OA) and more complex in children due to the cost of disposable equipment, but the overall cost is similar⁹. 18 Shorter postoperative hospital stays and fewer complications save LA money. 19 Same-day or fast-track surgery makes LA the most cost-effective. We investigated if laparoscopic appendectomy can be done in 24 hours¹⁰.

Appendicitis rates vary widely. Appendicitis is rarer in developing nations. Global incidence has declined during the previous several decades. Over 70,000 children in the US are diagnosed with appendicitis each year. 20 Men have a 9% lifetime risk of appendicitis and women 7%. 21 1/3 of appendicitis patients are under 18. Whites and summertime have more appendicitis. Peak incidence is 11–12. 22 Perforated appendicitis may develop in preterm newborns. However, it is rare. Hirschsprung disease neonates may develop perforation. 23 Appendicitis still causes severe morbidity and sometimes mortality, despite better diagnosis and treatment. Very limited data is available about the effectiveness of the laparoscopic appendectomy for the treatment of Appendicitis in our setting. Therefore this study was carried out to determine the effectiveness of laparoscopic appendectomy for children performed as emergency or emergency surgery at MTI/LRH in Peshawar, Pakistan.

METHODS & MATERIAL

In this retrospective assessment, laparoscopic treatment for acute appendicitis in children resulted in early laparoscopy,

appendectomy, and peritoneal lavage or drainage for problematic patients. They performed each occurrence. 1983 saw an "endoscopic" appendectomy.²⁴ Laparoscopic-assisted appendectomy removes the appendix via a tiny abdominal incision. Another option is laparoscopic appendectomy. The scope uses an umbilical, suprapubic, and left lower quadrant trocar—single-incision multiport works. The mesoappendix follows the cecum. Electrocautery, clips, staples, or harmonic scalpels divide the mesoappendix via a base window. Appendix ligation and removal are common. 26 Umbilical trocar endoscopic staplers deliver the appendix. Single-port/incision approaches were tested.

Despite prospective, randomized research, laparoscopic appendectomy has perks and cons. 27 Benefits include shorter hospital stays, reduced surgical pain, wound concerns, better diagnosis, more straightforward obesity surgery, and quicker recovery. 28 Disadvantages include higher equipment and operation expenses, increased intra-abdominal infection, and appendix finding—29 Safe, successful laparoscopic appendectomy. Open surgery benefits vary. Laparoscopic appendectomy's benefits include no further treatment or readmission, time and cost savings, shorter hospital stay, fewer nosocomial infections, definitive treatment in one step, local infection control, and no puss in the peritoneal cavity. They were operating in an inflamed, polluted region with risks of appendectomy, infection, and intestinal laceration. Acute appendicitis in children were diagnosed by clinical examination, blood tests, plain radiography, ultrasonography, CT scan, etc. After resuscitation, kids were kept NPO for 6 hours, antibiotics were started, and laparoscopic appendectomy was performed under general anesthesia in the pediatric surgical unit. They reviewed 79 children who underwent laparoscopic surgery for suspected acute appendicitis between July 1997 and July 2000. Patients with unexplained acute appendicitis had abdominal computed tomography or ultrasonography before surgery. White blood count, urinalysis, beta-human chorionic gonadotropin, fast streptococcal screen, and others may be tested. 30 All patients got one broad-spectrum antibiotic preoperatively to prevent wound infections and had surgery under general anesthesia. After CO₂ pneumoperitoneum, laparoscopic surgery needed a 5-mm or 12-mm umbilicus port. It has a laparoscopic telescope. Laparoscopes directly view abdominal and pelvic canals for various diseases.

Under direct vision, two 5-mm ports were put in the suprapubic area, left lower quadrant, and right iliac fossa, right upper quadrant. Grabbing the appendix's distal end revealed its parts. Cut appendiceal artery. Endoscopic staplers or loops separated the appendix base. An umbilical incision endoscopic bag removed an extensive or friable appendix. The fascia was approximated, and all ports were released under observation to avoid incisional hernias: no skin cuts or drainage. Patients got a 5-day moxycillin+clavulanate carouse at home if surgery revealed localized or severe peritonitis. Patients received five days of intravenous ampicillin, gentamicin, and clindamycin if their appendix ruptured before removal. Oral antibiotics home. Normal saline aggressively lavaged abscesses or peritoneal spoilage. Ketorolac tromethamine and acetaminophen eased postoperative pain. Patients must drink, be afebrile, and not vomit to go home. Patients were evaluated 7–14 days post-discharge.

RESULTS

Laparoscopic appendectomy was performed on 79 children (44 boys and 35 girls) aged 2–16 (mean age, 11 years). In 4 (5%) children, all with perforated appendicitis, the laparoscopic appendectomy was switched to an open appendectomy, related to technical problems in finishing the procedure laparoscopically. At surgery, 51 (64.5%) had acute appendicitis, 22 (27.8%) had perforated, 4 (5%) had burst ovarian cysts, and 2 (2.5%) had no pathology. The median operational time was 54 minutes. All 79 patients had a median 58-hour inpatient stay and 35 hours postoperatively. Complications included wound infection, 2 (2.5%); abdominal abscess, 4 (5%); drug rash, 2; and epi-didymo orchitis,

1. All but one incident (drug rash, 1) occurred in the perforation group. In the 57 (72%) children without perforated appendicitis, the median inpatient stay was 42 hours, and the median postoperative stay was 28 hours. Laparoscopic appendectomy sent 32 (56%) children without perforated appendix home within 24 hours. The non-perforated group had no substantial morbidity (drug rash, 1; fever, 3, no readmissions or reoperations). In 40 of 79 instances, ultrasonography assessment found inflammatory (19), collection (8), and gangrened appendicitis (8). The age range was 2 to 16 years (3). Seventy-nine individuals had primary wound closure. Three instances had right lower quadrant peritoneal cavity drains. The most prevalent antibiotic combination given to our patients was cephadrine + amikacin + metronidazole, and in a few instances, ceftriaxone, ampicillin, and gentamicin were also utilized. 24–48 hours of postoperative antibiotics. Most hospital stays were under 24 hours.

All 79 cases had a safe appendectomy, and postoperative problems were assessed in the ward and as outpatients. Drainage and irrigation treated six wound infections in early complications. Four patients had chronic stomach discomfort during long-term follow-up and were readmitted for laparotomy.

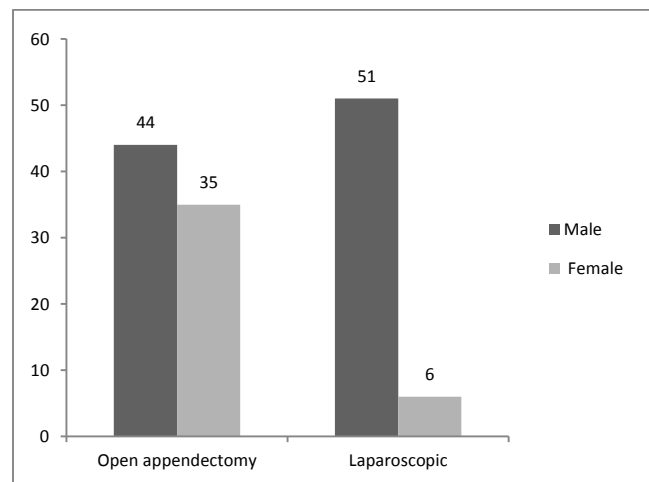


Figure 1: Gender wise distribution of the patients in both the groups

Table 1: The patients' (n=79) demographic information

Variable	Open appendectomy	Laparoscopic
Mean age (years)	2.16±11.02	2.16±1.02
Symptoms		
acute appendicitis,	30 (64.5%)	10 (24%)
burst ovarian cysts	03 (03%)	3 (2%)
wound infection	2 (2.5%)	
abdominal abscess	4 (05%)	
Complicated appendectomy	47 (61%)	32 (39%)

-P-value >0.05

DISCUSSION

Many studies have shown that laparoscopic appendectomy (LA) is at least as good as open appendectomy (OA), with less postoperative pain and shorter hospital stays. Most appendectomies—especially in children—are performed publicly (LOS)¹¹. Laparoscopic appendectomy requires more time and equipment, but it heals quicker and has fewer complications. Operative skill may speed up laparoscopic appendectomy. Non-disposable laparoscopic appendectomy is cheaper. Finally, laparoscopic appendectomy provides a faster recovery period and restores patients to a busy lifestyle sooner, justifying its expense¹². Parents may work again after school. Adult laparoscopic appendectomy reduces postoperative complications and wound infection¹³. Our study included two wound infections and four abscesses, like others¹⁴. The perforated group always struggled.

Laparoscopic appendectomy treats acute and perforated appendicitis¹⁵. Laparoscopy cleans the abdomen after appendectomy to prevent spots. Laparoscopic surgery irrigates the core and identifies all estimated collections¹⁶.

Laparoscopic surgery helps diagnose young female appendicitis sufferers. Obesity and mental illness may complicate appendicitis diagnosis. Laparoscopy may identify stomach pain in probable appendicitis¹⁷. Four of our suspected appendicitis patients had normal appendices intraoperatively, and ruptured ovarian cysts caused their pain. Four female patients. Some found women's diagnoses more uncertain¹⁸. In 4 instances, the appendix was normal but removed following surgery. Laparoscopy has shown that a cosmetically normal appendix may be removed¹⁹. Microscopy may detect early appendicitis. We found microscopic appendicitis in two normal-looking appendices. Joint outpatient laparoscopic surgery²⁰. Children's outpatient appendectomy isn't new. Ramesh and Gallard²¹ advised 24-hour discharge following a surgical appendectomy in 1993. Another research. Velho et al. 43 reported that most children could go home 24 hours following an appendectomy²¹. That study employed a 2 cm gridiron appendectomy incision. In 1999, Brosseuk and Bathe²² recommended early release after outpatient laparoscopic appendectomy for both perforated and uncomplicated appendicitis²². In this study, no children had a laparoscopic appendectomy. Perforated instances had all serious problems suggesting against same-day surgery²³. Our treatment approach for 46 perforated appendix patients includes 72 hours of intravenous antibiotics²⁴. Non-perforatedNonperforated appendicitis children may undergo laparoscopic appendectomy safely and swiftly. Laparoscopic appendectomy is cheaper and more convenient for patients and families²⁵. Our 3-year retrospective review of data led to the study's findings. The child's 24-hour release was unplanned. Non-medical discharge delays excluded some kids. We determined the kid's discharge date rather than their hospital release date. If documentation was unclear, these children were excluded. Uncomplicated appendicitis should be released within 24 hours if the above prerequisites are satisfied. Laparoscopic appendectomy for mild appendicitis may be a fast-track, short-stay surgery for children²⁶.

CONCLUSION

Treatment of diagnosed appendicitis in children with laparoscopic appendectomy is safe and successful. In select children without perforated appendicitis, it may be conducted as fast-track or same-day surgery, with a postoperative stay of fewer than 24 hours in most cases. Most of these patients are mishandled since the peripheral lacks MIS for pediatric surgery. The guidelines are below. The government should promote district-level laparoscopic appendectomy (MIS) and fund workshops by tertiary care professionals at district facilities.

REFERENCES

- Gans SL, Berci C. Peritoneoscopy in infants and children. *J Pediatr Surg*. 2020;
- Semm K. Die endoskopische Appendektomie. *Gynakol prax*. 2018;7:131-40
- Fitz RH. Perforating inflammation of the vermiform appendix, with special reference to its early diagnosis and treatment. *Trans Assoc AM Physicians* (1886); 107-44.
- McClusky DA, Skandalakis JE. *Skandalakis' Surgical Anatomy*. New York: McGraw Hill; 2004
- Henry MC, Collin G, Islam S, Sylvester K, Walker A, Silverman BL, et al. Matched analysis of nonoperative management Vs. Immediate appendectomy for perforated appendicitis. *Journal of pediatric surgery* 2019, 42(1): 19-24.
- Gilchrist BF, Lobe TE, Schropp KP, et al. Is there a role for laparoscopic appendectomy in pediatric surgery? *J Pediatr Surg*. 2019;27:209-14.
- Richards W, Watson D, Lynch G, et al. A review of laparoscopic versus open appendectomy results. *Surg Gynecol Obstet*. 2018;177:473-80
- El Ghoneimi A, Valla JS, Limonene B, et al. Laparoscopic appendectomy in children reported 1379 cases. *J Pediatr Surg*. 2020;29:786-89
- Reiertsen O, Larsen S, Trondsen E, et al. Randomized controlled trial with the sequential laparoscopic versus conventional appendectomy design. *Br J Surg*. 2021;84:842-847
- Jen HC, Shew SB. Laparoscopic versus open appendectomy in children: Outcomes comparison based on a statewide analysis. *J Surg Res* 2020;161:13
- Ponsky TA, Hafi M, Heiss K, et al. Interobserver variation in the assessment of appendiceal perforation. *J Laparoendosc Adv Surg Tech A* 2019;19:S15.
- St Peter SD, Aguayo P, Fraser JD, et al. Initial laparoscopic appendectomy versus initial nonoperative management and interval appendectomy for perforated appendicitis with abscess: A prospective, randomized trial. *J Pediatr Surg* 2020;45:236
- Goh BK, Chui CH, Yap TL, Low Y, Lama TK, Alkoudier G, et al. Is early laparoscopic appendectomy feasible in children with acute appendicitis presenting with an appendiceal mass? A prospective study. *Journal of pediatric surgery* 2021; 40(7): 1134-7.
- Aguayo P, Alemayehu H, Desai AA, Fraser JD, St Peter SD. Initial experience with same-day discharge after laparoscopic appendectomy for non-perforated nonperforated appendicitis. *J Surg Res* 2014;4804(14):245-50.
- Bergholz R, Klein I, Wenke K, Boettcher M, Reinshagen K, Krebs T. The midterm outcome of transumbilical laparoscopic-assisted versus laparoscopic and open appendectomy. *Europ J Pediatric Surg* 2014;28(3):35-9.
- Bergholz R, Krebs T, Klein I, Wenke K, Reinshagen K. Transumbilical laparoscopic-assisted versus three-port laparoscopic and open appendectomy: a case-control study in children. *Surg Laparosc Endosc Percutan Tech* 2014; 24(3):135-9.
- Borges PSGN, Lima MC, Falbo Neto GH. Validação do score de Alvarado
- no diagnóstico de apendicite aguda em crianças e adolescentes no Instituto Materno Infantil de Pernambuco. 2003; 3(4): 439-45.
- Brenner AS. Apendicectomia em pacientes com idade superior a 40 anos: análise dos resultados de 217 casos. *Rev Bras Colo-proctol* 2017; 26(2):128-32.
- Carter JT, Kaplan JA, Nguyen JN, Lin MY, Rogers SJ, Harris HW. A prospective, randomized controlled trial of single-incision laparoscopic vs. conventional 3-port laparoscopic appendectomy for treatment of acute appendicitis. *J Am Coll Surg* 2014; 218(5):950-9.
- Cawich SO, Mohanty SK, Simpson LK, Ramdass MJ, Naraynsingh V. Is laparoscopic appendectomy safe when performed in a low volume setting? *Int J Biomed Sci* 2014; 10(1):31-5.
- Clerveus M, Morandeira-Rivas A, Moreno-Sanz C, Herrero-Bogajo ML, Picazo-Yeste JS, Tadeo-Ruiz G. Systematic review and meta-analysis of randomized controlled trials comparing single-incision versus conventional laparoscopic appendectomy. *World J Surg* 2014; 28:31-9.