

Effects of Artificial Sweeteners Aspartame and Sucralose on the Size of Hepatocytes in Rat Liver

NADIA HAQ¹, SADIA SAQIB², RAAFEA TAFWEEZ³, IRFAN ALI⁴, AHMAD FAWAD SYAMI⁵

¹King Edward Medical University, Lahore

²KEMU Lahore

³Azra Naheed Medical College Lahore

⁴Mayo Hospital Physiotherapy Department, Lahore

⁵Nawaz Sharif Yaki Gate Hospital Surgery Department, Lahore

Corresponding author: Nadia Haq, Email: haqnadiah@gmail.com

ABSTRACT

Background: The use of artificial sweeteners in excess these days to lose weight and to remain fit without knowing its effects on our health, gave me a thought to conduct this study to see whether they are safe or not for liver health.

Objectives: The objectives of this study were to see the effects of Aspartame and Sucralose (Artificial sweeteners) on rat hepatocytes and also to compare their effects to choose relatively safe artificial sweetener for routine use.

Method: 50 adult Wistar albino rats were used in this study. Animals were divided into five groups by random lottery method. Control group I animals were given distilled water by oral gavage. The group II and III animals were given 40mg and 1000mg/kg body weight of Aspartame respectively. Whereas animals of group IV and V were given 5mg and 1000mg/kg body weight of Sucralose respectively. Doses to experimental animals were given by oral gavage once daily for a total duration of eight weeks. At the end of the experiment rats were sacrificed, livers were dissected out and after specimen preservation the tissue was passed through stages of slide preparation and later H and E staining was performed.

Results: Light microscopic examination of liver slides revealed that largest sizes of hepatocytes were observed in high dose groups of Aspartame and Sucralose.

Conclusion: The increase in the size of hepatocytes was observed in high dose groups of Aspartame and Sucralose whereas changes seen in low dose groups were not significant.

Keywords: Artificial sweeteners, Histology of rat liver, Size of hepatocytes.

INTRODUCTION

Sugars are an essential part of food and drinks during processing to improve the taste. Use of energy and vitamin drinks, iced tea and sugar sweetened beverages has risen across the globe.¹ Diabetes Mellitus becomes easily treatable with artificial sweeteners because they are slowly metabolized allowing blood sugar levels to remain stable over time.² Similarly, individuals with reactive hypoglycemia can overcome their hypoglycemia using sugar substitutes.³ Artificial sweeteners help to control dental problems.⁴ Sugar substitutes also increase the flavor of foods and beverages as well as used as an alternative to refined white sugar.

Artificial sweeteners can be nutritive or non-nutritive. Nutritive sweeteners provide about four Calories /gm of food and non-nutritive ones add no energy value to the food. Nonnutritive sweeteners; Acesulfame potassium, Saccharin, Neotame, Aspartame and Sucralose are approved by FDA.⁵

In the past few decades, use of nonnutritive sweeteners has increased dramatically. Approximately 15% of the U.S population is estimated to be using most preferred non-nutritive sweeteners such as Aspartame and Sucralose.⁶

Aspartame is a white crystalline powder 180 times sweeter than sugar. It consists of phenylalanine and aspartic acid which are linked together by methanol. Phenylalanine is an essential amino acid which breaks down to fumarate and acetoacetate during energy metabolism whereas aspartic acid is a non-essential amino acid and acts as a brain neurotransmitter. Methanol breakdown leads to formation of formate and oxygen free radicals in the liver to be excreted out. The liver metabolism fails to handle it when consumed in large amounts leading to a state of oxidative stress.⁷ In comparison the bulk of Sucralose that is ingested is excreted out in the faces whereas only 11-27% of ingested is absorbed.⁸

The microscopic anatomy of rat liver shows that it is composed of parenchymal and non-parenchymal cells. The parenchyma mainly consists of hepatocytes (80%) and non-parenchymal cells include Kupffer cells, Ito cells, endothelial cells and Pit cells.⁹ In histology to see the functional capacity of hepatocytes hepatic acinus is considered as a unit which is a diamond shaped area involving two portal triads and two central veins at its boundary. It is subdivided into periportal (Zone I), transitional (Zone II) and paracentral (Zone III) zones.¹⁰

In the past many studies have been conducted to see

various effects of artificial sweeteners. This study is designed to see the effects of Aspartame and Sucralose on liver, a main center of metabolism in albino rats.

Objectives:

- 1- To see the effects of aspartame and sucralose on size of hepatocytes in rat liver.
- 2- To compare their effects to choose relatively safe artificial sweetener for routine use.

METHODS

Study Design: Randomized control trial

Sampling Technique: Sampling was done by using lottery method

Study Settings: The study was conducted in the Anatomy department (Histology section) of KEMU, Lahore after approval from departmental ethical committee (reference to the letter number 408/RC/KEMU).

Duration of Study: Three months (March 2018 to May 2018)

Sample Size Calculation: This sample size was calculated by using 95% confidence level, 90% power of test along with expected fat aggregation in liver as 100% \pm 20 in control group and in experimental groups as 130% \pm 20.¹¹ For each variation of sweetener and its dose a group of 10 was added and total sample size of 50 animals was calculated.

Wistar adult albino rats irrespective of gender and falling in age group of 2 to 3 months were selected. Average weight of rats was between 170-220gms. Animals were kept in the animal house of University of Veterinary and Animal Sciences (UVAS). In initial 2 weeks of experiment, animals were acclimatized in the new environment by providing a natural light and dark cycle of 24 hours and temperature in the room was maintained between 22-25°C. All animals were provided with chick food available in the market and water was given ad-libitum.

Grouping of animals: Five groups of animals were made by random lottery method including one control group and four experimental groups. Each group was consisting of 10 animals. Groups were labeled on cages as I, II, III, IV and V whereas animals in each group were numbered from 1 to 10 by using color.

Control group (Group I): Each animal of this group was administered 3ml of distilled water with oral gavage.

Low dose group of Aspartame (Group II): There were 10

animals in this group. Low dose for group II animals was taken as 8mg for a rat having average weight of 200gm with reference to the acceptable daily intake of Aspartame in humans which is considered to be 40mg/kg body weight. For preparation of 8mg dose of each rat, 4.5 tablets (81mg) of Aspartame were dissolved in 30ml of distilled water making 3ml of the solution containing 8mg of Aspartame. This dose was given by oral gavage.

High dose group of Aspartame (Group III): 200mg was taken as high dose in this group for a rat with average weight of 200gm with reference to LD50 dose in rats of oral Aspartame as 10,000mg/kg.¹² For this dose preparation 112 tablets (2016mg) of Aspartame were dissolved in 30ml of distilled water making 3ml dose containing 200mg of Aspartame which was delivered by oral gavage.

Low dose group of Sucralose (Group IV): Low dose of Sucralose calculated for an animal in this group having average 200gm weight was 1mg with reference 5mg/kg body weight of Sucralose in humans taken as acceptable daily intake. For this dose preparation, 650mgs (One teaspoon of Sucralose) were dissolved in 650ml of distilled water making 1ml solution containing 1mg of Sucralose and was administered through oral gavage.

High dose group of Sucralose (Group V): High dose calculated for this group was 200mg for a rat with average weight of 200gm with reference to LD50 of oral Sucralose in rats which is >10g/kg body weight.¹³

For this dose preparation 3 teaspoons of Sucralose(2000mg) were dissolved in 30ml of distilled water, making 3ml of dose containing 200mg of Sucralose and was administered through oral gavage.

Dose administration to rats by oral gavage: A pediatric nasogastric tube of number 8 was attached with a 10cc disposable syringe (Figure 4). Syringe was loaded with the calculated dose. With gloved hands animal 1 of group I (control group) was brought out of its cage by holding the tail and later grasped from its back and neck so that it opened its mouth. At that time NG tube was introduced from the side into its mouth deep up to the pharynx and immediately dose was administered by pressing syringe. Animal was also observed for any signs of choking and was put back into its cage. All animals of each group were given the doses in the same way as a single dose daily for 8 weeks.

Procedure of dissection: After 8 weeks, dissection of animals was performed using chloroform as an anesthetic agent. After anesthesia, animal was stretched out on the dissection table. Abdomen was opened using midline incision.

Liver lying in right hypochondrium was dissected out after cutting coronary and falciform ligaments. After performing gross inspection, specimens of liver were preserved in labeled plastic jars containing 10% formalin solution.

Tissue processing: The liver specimens were placed later fixed in separate labelled plastic cases. Processing was performed in automatic processor in the laboratory having model specification of Histotech III USA. In this processor tissue automatically passes through the different stages of tissue preparation such as tissue is dehydrated then fixatives are removed and later paraffin is infiltrated. After tissue processing tissue blocks were prepared and placed in refrigerator to further consolidate. Tissue blocks were sliced by using rotary microtome in the laboratory with model specification of Histoline RM 2258. Every fourth section was selected was spread on labeled glass slide coated with albumin. After removing extra water, slides were dried by a slide warmer and were then sent in an incubator with 60°C temperature for 15 minutes to remove the wax. Staining of slides was performed with Hematoxylin and Eosin stains by following reference protocol¹⁴. After this best slide were selected for light microscopy under different magnifications.

Measurement of size of hepatocytes in μm : Micrometry¹⁵ was performed using light microscope at magnification of 400X. To measure the size of hepatocytes, any 20 cells were measured in transverse, anteroposterior and oblique dimensions. For size of a single hepatocyte, mean of its three dimensions was calculated

and later average of 20 hepatocytes was calculated which finally represented the average size of that particular animal in μm .

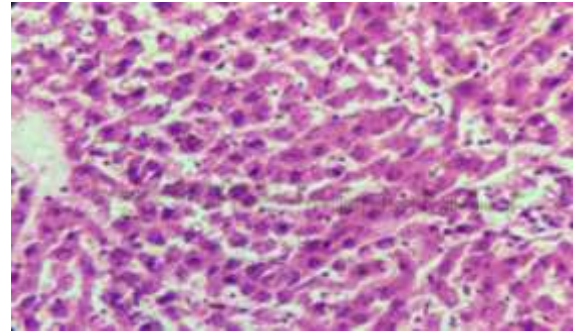


Figure 1a: Measurement of size of hepatocytes by oculometer (visible as graduated scale) in control group (Group I). H&E stain. L/M under 40Xx10X=400X

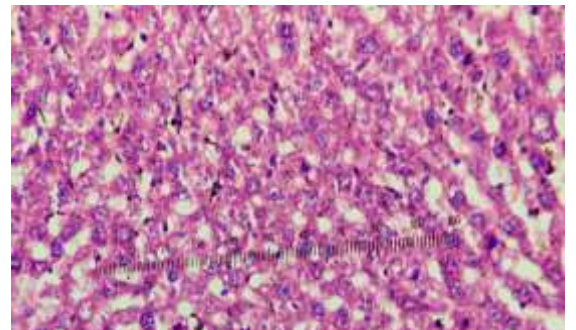


Figure 1c: Measurement of size of hepatocytes by oculometer (visible as graduated scale) in group III. Significantly enlarged hepatocytes are visible. H&E stain. L/M under 40Xx10X=400X.

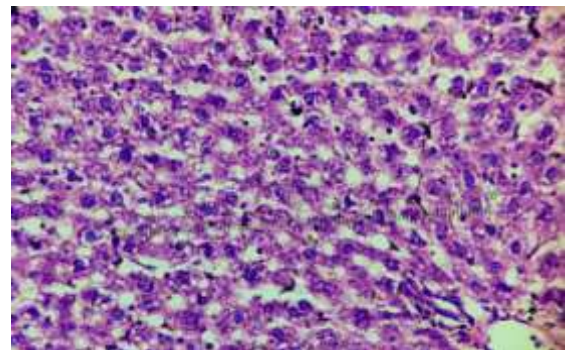


Figure 1b: Measurement of size of hepatocytes by oculometer (visible as graduated scale) in group II. H&E stain. L/M under 40Xx10X=400X

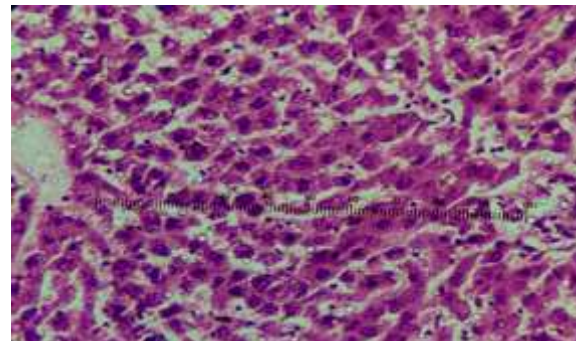


Figure 1d: Measurement of size of hepatocytes by oculometer (visible as graduated scale) in group IV. H&E stain. L/M under 40Xx10X=400X.

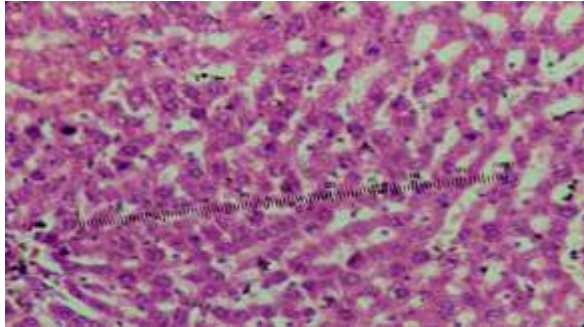


Figure 1e: Measurement of size of hepatocytes by oculometer (visible as graduated scale) in group V. H&E stain. L/M under 40Xx10X=400X.

Key
 Group –I Control group
 Group –II Low dose group of Aspartame
 Group –III High dose group of Aspartame
 Group –IV Low dose group of Sucralose
 Group –V High dose group of Sucralose

Mean size of hepatocytes was observed to be maximally increased in group III (high dose of Aspartame) which was also statistically significant and in group V (high dose of Sucralose) which was statistically insignificant when compared with control group. Significant statistical difference was present between low and high dose groups (group II and III) of Aspartame. A significant statistical difference was present between high dose groups (Group III and V) of Aspartame and Sucralose.

RESULTS

In group I (control group) mean size of hepatocytes was 16.46 ± 1.74 µm which was taken as a standard to compare the size of other groups. In group II (low dose group of Aspartame) mean size of hepatocytes measured was 16.09 ± 0.85µm. It was quite similar to the mean size of hepatocytes in control group with statistically insignificant difference. In group III (high dose group of Aspartame) mean size of hepatocytes measured was 20.86 ± 2µm. This mean size of hepatocytes was significantly increased as compared to all other groups. In group IV (low dose group of Sucralose) size of hepatocytes seemed to be decreased as compared to the other groups. On micrometry mean size of hepatocytes measured was 15.62 ± 1.3 µm (Table 1). This mean size of hepatocytes was significantly decreased as compared to all other groups but it was statistically insignificant (Table 4). In group V (high dose group of Sucralose) mean size of hepatocytes measured was 17.54 ± 2.04µm (Table 1). This mean size of hepatocytes was increased as compared to the control group.

Table 1: Size of hepatocyte of animals in all experimental groups.

Group	Size of hepatocytes (µm)			
	Mean	Standard Deviation	Minimum	Maximum
Group – I	16.46	1.74	13.92	19.2
Group – II	16.09	0.85	14.64	17.76
Group - III	20.86	2	17.28	24
Group - IV	15.62	1.3	13.92	17.76
Group – V	17.54	2.04	16.08	23.04

Key
 Group –I Control group
 Group –II Low dose group of Aspartame
 Group –III High dose group of Aspartame
 Group –IV Low dose group of Sucralose
 Group –V High dose group of Sucralose

Statistical Analysis: Quantitative variable of size of hepatocytes was analyzed using mean ± S. D. For the comparison among groups one way ANOVA test was applied. Tukey’s test was applied for post-hoc analysis.

Less than 0.05 P-value was taken as statistically significant
 Data was analyzed by using SPSS 21.0

Table 2: Pair wise comparison of size of hepatocytes of all experimental groups by using Tukey’s test.

Group(I)	Group(J)	Mean Difference (I-J)	Standard Error	Significance
Group – I	Group – II	0.37	0.74	0.986
	Group – III	-4.40*	0.74	<0.001
	Group – IV	0.84	0.74	0.787
	Group – V	-1.08	0.74	0.589
Group – II	Group – III	-4.77*	0.74	<0.001
	Group – IV	0.46	0.74	0.970
	Group – V	-1.45	0.74	0.296
Group – III	Group – IV	5.24*	0.74	<0.001
	Group – V	3.32*	0.74	<0.001
Group – IV	Group – V	-1.92	0.74	0.087

DISCUSSION

In the control group mean size of hepatocytes measured was 16.46 ± 1.74 µm which was taken as a standard for comparison with other groups. In group II (low dose Aspartame) mean size of hepatocytes was quite similar to the mean size of hepatocytes in control group. In group III (high dose Aspartame) mean size of hepatocytes measured was significantly increased as compared to all other groups. In group IV (low dose Sucralose), the mean size of hepatocytes was significantly decreased as compared to all other groups. In group V (high dose Sucralose), the mean size of hepatocytes was increased as compared to the control group.

The statistically significant increase in the mean size of hepatocytes was only seen in group III (high dose Aspartame) whereas increase seen in group V (high dose Sucralose) was statistically insignificant. Significant statistical difference was also present between two groups of Aspartame. Similarly, significant statistical difference was also seen between high dose groups of Aspartame and Sucralose.

In present study the hepatocytes were labeled to be enlarged when compared with control group. In present study maximum increase in the size of hepatocytes was seen in rats given with high doses of Aspartame (Group III) whereas increase in the size is also observed in rats given high doses of Sucralose (Group V). The reason for this increase in size could be, cellular edema as a result of cellular injury, hypertrophy as a phase of degenerative process or more convincingly due to cellular infiltration, vacuolation and fatty change.¹⁶

Finamor I. et al, observed alterations in oxidative defense status of liver after administration of Aspartame to albino rats.¹⁷ Mohamed El-sayed Alkafafy. et al, gave Aspartame in 250 to 1000mg/kg body weight doses to two experimental groups for eight weeks duration and observed degenerative changes of hepatocytes in the form of cellular swelling and other were necrotic. He observed obvious changes in rats fed with high doses of aspartame.¹⁸

The answer to the question that how the sucralose leads to liver damage was proposed by Jiang et al who suggests that Sucralose intake enhances the growth of gut bacteria that can efficiently get energy from ingested food and turns it to fat that stores in the liver and causes increased risk of liver diseases.¹⁹

After analyzing the results of this study some question is raised as low dose of Aspartame may be safe to use because it did not cause significant increase in the size of hepatocytes. Similarly, even high dose of Sucralose did not cause any significant increase in the size of hepatocytes so is it a safe sweetener to be used? Decrease in the size of hepatocytes is another important fact seen in this study which needs further exploration of facts.

To solve the above-mentioned queries, this study has some shortcomings which should be overcome in the next studies such as exposure of liver to artificial sweeteners for a longer duration of time. So, this study is opening new gateways for the next researchers.

CONCLUSION

The conclusion of this study is that Aspartame and Sucralose are less damaging for liver if taken in low doses but in large doses both are damaging for hepatocytes though Sucralose is a comparatively safe artificial sweetener to be used in large doses.

REFERENCES

- 1 Ciriminna R, Meneguzzo F, Pecoraino M, Pagliaro M. (2019). A bioeconomy perspective for natural sweetener Stevia. *Biofuel Bioprod.* 13(3):445-52.
- 2 Liauchonak I, Qorri B, Dawoud F, Riat Y, Szwczuk MR. (2019). Non-nutritive sweeteners and their implications on the development of metabolic syndrome. *Nutrients.* 11(3):644.
- 3 Joshi A, Rao S, Kadhe G. (2019). Glucagon Like Peptide 1 and Evidence Around Diabetes. *Specific Nutrition. World Nutr. J.* 30. 10(2):64-75.
- 4 Smith MA, Wells MH, Scarbecz M, Vinall CV, Woods MA. (2019). Parents' Preferences and Perceptions of Their Children's Consumption of Sugar and Non-nutritive Sugar Substitutes. *Pediatr Dent.* 41(2):119-28.
- 5 Pepino MY. (2015). Metabolic effects of non-nutritive sweeteners. *PHYSIOL BEHAV.* 152:450-5.
- 6 Anton SD, Martin CK, Han H, Coulon S, Cefalu WT, Geiselman P. (2010). Effects of stevia, Aspartame, and sucrose on food intake, satiety, and postprandial glucose and insulin levels. *Appetite.* 55(1):37-43.
- 7 Hazrati R, Khah MM, Thangavelu L, Marzban S, Sohrabi A, Zamani A. Mesenchymal stromal cells (MSCs) and their exosome in acute liver failure (ALF): a comprehensive review. *Stem Cell Res Ther.* 2022 May 8;13(1):192. doi: 10.1186/s13287-022-02825-z. PMID: 35527304; PMCID: PMC9080215.
- 8 Rother KI, Sylvestry AC, Walter PJ, Garraffo HM, Fields DA. (2018). Pharmacokinetics of Sucralose and Acesulfame-Potassium in Breast Milk Following Ingestion of Diet Soda. *J pediatr gastroenterol and nutr.*66(3):466-70.
- 9 Kang YB, Eo J, Mert S, Yarmush ML, Usta OB. (2018). Metabolic patterning on a chip: towards in vitro liver zonation of primary rat and human hepatocytes. *Sci Rep.* 8(1):8951.
- 10 Kakabadze Z et al. (2019). Decellularized bovine placentome for portacavally-interposed heterotopic liver transplantation in rats. *Mater Sci Eng: C.* 97:293-301.
- 11 Bergheim I, Weber S, Vos M, Krämer S, Volynets V, Kaserouni S. (2008). Antibiotics protect against fructose-induced hepatic lipid accumulation in mice: role of endotoxin. *Int J Hepatol.* 48(6):983-92.
- 12 Iyaswamy A et al. (2018). Oxidative stress evoked damages leading to attenuated memory and inhibition of NMDAR-CaMKII-ERK/CREB signalling on consumption of aspartame in rat model. *J Food Drug Anal.* 26(2):903-16.
- 13 Magnuson BA, Roberts A, Nestmann ER. (2017). Critical review of the current literature on the safety of sucralose. *Food Chemical Toxicol.* 106:324-55.
- 14 Spencer L, Bancroft J, Bancroft J, Gamble M. *Tissue processing. Bancroft's Theory and Practice of Histological Techniques.* 7nd ed. Netherlands, Amsterdam: Elsevier Health Sciences. 2012 1:105-23.
- 15 Quesnel LB. Chapter 1. Microscopy and Micrometry. In: J.R.Norris, D.W.Riborrs, editors. *Methods in microbiology.* The Netherlands. Elsevier.1971;5(Part A): p.1-3.
- 16 Beals N, Model MA, Worden M, Hegmann T, Basu S. (2018). Intermolecular G-Quadruplex Induces Hyaluronic Acid-DNA Superpolymers Causing Cancer Cell Swelling, Blebbing, and Death. *ACS Appl. Mater. Interfaces.* 10(8):6869-78.
- 17 Finamor I et al. (2017). Chronic aspartame intake causes changes in the trans-sulphuration pathway, glutathione depletion and liver damage in mice. *Redox biol.* 11:701-7.
- 18 Alkafafy ME, Ibrahim ZS, Ahmed MM, El-Shazly SA. (2015). Impact of Aspartame and saccharin on the rat liver: Biochemical, molecular, and histological approach. *Int J Immunopath pharmacol.* 28(2):247-55.
- 19 Jiang W et al. (2015). Dysbiosis gut microbiota associated with inflammation and impaired mucosal immune function in intestine of humans with non-alcoholic fatty liver disease. *Sci Rep.* 5(8096):1-7.