

# Impacted Mandibular Third Molars Associated Pathologies

SADIA SAHIBZADA<sup>1</sup>, AJMAL KHAN<sup>2</sup>, TARIQ SARDAR<sup>3</sup>, USAMA AURANGZEB<sup>4</sup>, NAFEESA AFRIDI<sup>4</sup>, INTIKHAB AMANAT<sup>4</sup>

<sup>1</sup>FCPS Maxillofacial Surgery, Dental Surgeon, Govt Hospital Gara Tajik, Peshawar

<sup>2</sup>Assistant Professor Maxillofacial Surgery, Saidu Medical College, Swat

<sup>3</sup>Assistant Professor Oral & Maxillofacial Surgery, KMU- Institute of Dental Sciences, Kohat

<sup>4</sup>House Officer BDS, Sardar Begum Dental College Peshawar

Corresponding author: Ajmal Khan, Email: [ajmal1172@gmail.com](mailto:ajmal1172@gmail.com)

## ABSTRACT

**Purpose:** The purpose of this research was to identify the most common and severe types of pathologic diseases surrounding impacted mandibular third molars using radiographic imaging.

**Cases and procedures:** An analysis of past patients who had impacted mandibular molars extracted at Oral & Maxillofacial Surgery of Cat D Hospital Gara Tajik Peshawar. Impacted mandibular third molar radiographic lesions, patient age and gender were used as the study's outcome measures. Caries, pericoronal radiolucent areas, periapical radiolucent areas, odontomes, and external resorption of the roots of adjacent mandibular second molars were also noted on radiographs of the impacted third molar. Histopathology confirmed the presence of bone marrow in all radiolucent regions.

**Results:** There were 2,832 mandibular third molars that had been impacted and were studied from 1,397 individuals; 49.4 percent of the impacted teeth had associated radiographic abnormalities. Dental cavities were the most prevalent abnormality detected by panoramic radiography. Other examples of this type of radiolucency can be found at the periphery of the cortex and at the tip of the apex. Histological analysis confirmed that chronic periapical inflammation was the primary cause of most periapical radiolucent regions. Histological examination revealed that all radiolucent spots located around the corona were malignant cysts or tumours. Dentigerous cysts were the most common type of cyst, while ameloblastomas were the most common type of tumour.

**Conclusion:** A large proportion of the patients with a third molar impaction in the mandible also had an underlying pathologic condition.

**Keywords:** Mandibular, Radiolucent, Panoramic, Tumor

## INTRODUCTION

One definition of an impacted tooth is one that is unable to erupt normally due to crowding or other factors. The debate over whether to extract or keep impacted third molars has raged in the dental literature for decades. Prophylactic removal of an asymptomatic third molar may not be as straightforward of a decision as removal of a third molar linked with pathologic alterations. There have been arguments both for and against the preventative extraction of impacted third molars, but the dentists' ability to sort through the conflicting evidence has been hampered [1-3]. When weighing the potential dangers and benefits of extracting a patient's third molar, surgeons should put the patient's needs first. Consequently, it is crucial to be aware of the pathologic conditions associated with impacted mandibular third molars. Recent guidelines for the management of mandibular third molars outline clear indications for third molar extraction in cases such as unrestorable caries, absence of treatable pulpal and/or periapical pathology, infection, internal or external resorption of the tooth or adjacent teeth, and follicular disease (such as cysts or tumours) [4]. However, the development of pathologic disorders in the area of an impacted third molar is still speculative. Pathologic changes around asymptomatic impacted third molars have been examined from both the inside and the outside. Therefore, it's important to collect data on the frequency of pathologic problems related to impacted third molars. It is sometimes assumed that people of different races and ethnicities will experience the same pathologic alterations in the area of their impacted mandibular third molars, however this is not always the case. Pathologic abnormalities around impacted mandibular third teeth are thought to be very common in Jordanians, however this has not been definitively shown [5-7]. It was the goal of this research to look at panoramic radiographs of Jordanians with impacted mandibular third teeth to see how often certain pathologic abnormalities were present. Caries in the partially erupted impacted mandibular third molar, as well as caries in the neighbouring mandibular second molar, are present, as are odontomes and external root resorption [8].

## PATIENTS AND METHODS

Patients who were sent to the Oral & Maxillofacial Surgery department of Cat D Hospital Gara Tajik Peshawar for the removal of impacted mandibular molars had their medical records reviewed

for this retrospective study. The presence of orthopantomograms in the medical records of the patients who participated in this study was a prerequisite for their inclusion. All of the mandibular third molars that were impacted in this study were either entirely submerged beneath the bone or partially erupted but still not able to reach the occlusal plane. Non-occlusally-present third mandibular molars were not included in the study. Lesions that could not be confirmed histologically were also ruled out of this research. Patients' ages and sexes, as well as any radiographic lesions related to impacted mandibular third molars, were included as the outcome measures in the analysis. There was evidence of caries in the impacted and partially erupted third molar or the adjacent second molar tooth, as well as pericoronal radiolucent areas around the impacted mandibular third molar, periapical radiolucent areas related to the impacted and partially erupted mandibular third molar, odontomes related to the impacted third molar, and external resorption of the impacted third molar. For each impacted third molar, we recorded the occurrence of any lesion. Histopathology verified all radiolucent areas to be cysts, tumours, or chronic inflammation. Using a regular radiography light box, a single observer watched each x-ray at ten different magnifications. Table 1 summarises the diagnostic criteria for each lesion that were established prior to the start of the investigation. A second observer randomly assessed 30 radiographs with detectable radiographic lesions once a day for 5 days to ensure the examiner's diagnostic repeatability. As far as could be seen, the two witnesses were identical.

## RESULTS

An overwhelming majority of the study's participants were male throughout nearly all age ranges and the study population totalled 1,397 people with 2,832 impacted mandibular third molars. Patients' ages ranged from 13 to 70, with the largest rate of impacted mandibular third molar extraction (37%) occurring in those between the ages of 20 and 25. The sample demographics in terms of age and gender are shown in Figure 1.

Table 1: radiographic criteria for the diagnosis of a fractured third molar in the lower jaw

Diagnosis	Criteria
Radiolucent ring around the	The radiolucent area surrounds the crown of the fully implanted impacted third molar in the mandible.

pericardium	
Odontoma	Radiopaque tumour masses that appear the same density on x-rays as teeth. Forming either a single dense mass or a stack of many denticles. Possessing a radiolucent border that may be located mesially, coronally, distally, or apically to the impacted mandibular third tooth.
Radiolucent region at the periphery	A region of the impacted third molar's root that is entirely radiolucent and attached to the root's apical one-third. It's possible for it to grow all the way to the root's side, but it must stop short of the cemento-enamel junction.
The Absorption of Roots from the Outside	It is evident that the impacted mandibular third tooth has caused damage to the adjacent mandibular second molar's root system.
Caries	Radiographic evidence of caries in either the impacted mandibular third molar or the adjacent mandibular second tooth.

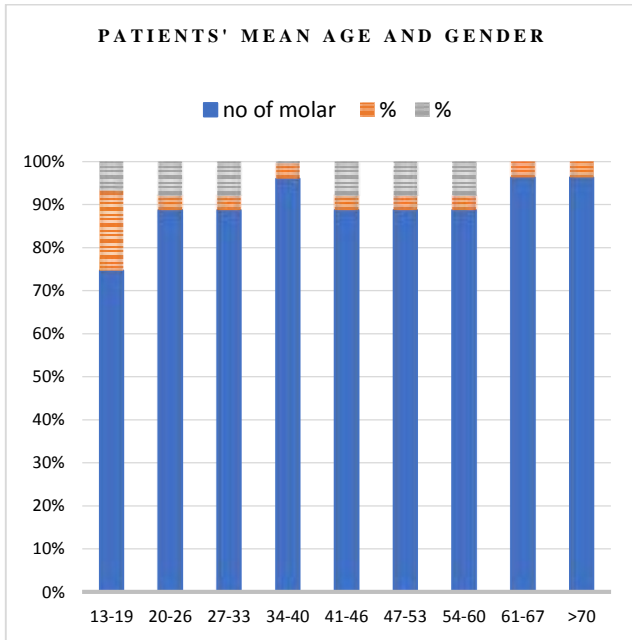


Figure 1: Impacted third mandibular molars: a demographic breakdown by age and gender (N = 2623).

Radiographic examination revealed that 1229 (or 43.3% of the total) of the 2832 teeth checked had lesions. Table 2 provides a summary of the detected radiographic lesions. The majority of lesions observed were caries (20.5% of teeth examined). In contrast to the molar teeth next to it, the third molar itself had a higher incidence of caries (15.6%). (35.9 percent). One-fourteenth of the sample of mandibular impacted third molars had pericoronal radiolucency, while other fifteen percent displayed periapical radiolucency (9.5 percent). Resorption of the root(s) of the neighbouring mandibular second molar was observed in 0.3% of teeth, and 0.2% of teeth were found to be associated with odontomes. Thirty-four percent of the periapical regions were classified as chronic periapical inflammation (granuloma or abscess) and 1.73 percent were classified as radicular cysts in Table 3.

Table 2: Tooth radiography lesions (N = 2632) related to Mandibular third molar impaction.

Pathologic condition	No	Frequency (%) <sup>a</sup>	Frequency (%) <sup>b</sup>
Radiolucency around the periphery	400	100	35.42958
Damage to her third molar caused by cavities in her mandibular apex.	340	12.91793	30.11515
A radiolucent periphery Root caries in the tooth next to it	235	8.928571	20.81488
Root attrition in the neighbouring	200	7.598784	0.673054

second molars			
Odontoma	10	0.379939	0.88574
Sum	8	0.303951	0.708592
There were no abnormalities detected by the radiograph.	1129	42.89514	100
Total	1303	49.50608	0

Table 3 shows that the radiolucent spots found around the coronoid process were consistently either tumours or cysts. Cryptic lesions, or cysts, affected 1.4% of all teeth studied, while malignant growths afflicted 1.9% of teeth. Dentigerous cysts were the most common cyst while ameloblastomas were the most prevalent tumour.

Table 3: Tooth (N = 288), a histopathological study of the radiolucent regions associated with impacted mandibular third molars.

	Type	No	Frequen cy (%) <sup>a</sup>	Frequenc y (%) <sup>b</sup>	Frequenc y (%) <sup>c</sup>
Tumors	Ameloblastoma	8	0.4	2.777778	0.8
	Giant cell granuloma in the centre	7	0.4	2.430556	0.7
	Caner of the squamous cells	4	0.10	1.388889	0.4
	Total	19	0.5	6.597222	1.4
Cyst	Dentigerous	21	0.12	7.291667	1.9
	Keratocyst	7	0.23	2.430556	0.6
	Radicular	5	0.14	1.736111	0.5
	Paradental	4	0.10	1.388889	0.4
	Total	37	1.4	12.84722	3.6
PA inflammation		232	1.11		22.3
		2		80.55556	
Total		288	13.1	100	25.9

## DISCUSSION

It has been noted that it is difficult to select a representative sample of the general population to study impacted third molars. For instance, a random sample of young adults from the general population is needed to estimate the prevalence of pathological conditions related to impacted third molars [9-12]. These samples are very challenging to collect, and it is debatable from an ethical standpoint to take radiographs of such young people. Taking a random sample from the community at large, like dentistry students, is likely to be prejudiced. In order to reduce the possibility of bias, we focused on those who were already known to have third molar impaction in their mandibles. However, we recognise that our study has limitations because it only includes teeth scheduled for surgical removal and had a preoperative panoramic radiograph. Due to the nature of the study, it is exceedingly challenging to avoid this bias. We discovered that at least one radiographically discernible lesion was connected to nearly half of the impacted mandibular third teeth that were examined [13-15]. This result disagrees with several other studies but is generally consistent with other others. Contrary to other studies' conclusions, this one's gender distribution was overwhelmingly male. We discovered that dental caries, which affected 42.5 percent of the teeth under study, was the most prevalent radiographic lesion. The third molar itself was more frequently affected by caries than the tooth next to it. Our findings and others' conclusions are generally in agreement. Since orthopantomograms were used to make the diagnosis, the prevalence of dental caries detected here is probably lower than it actually is. The partially erupted mandibular third molars and adjacent second molars were hypothesised to have a higher prevalence of dental caries because they are harder to reach during routine oral hygiene practises, allowing plaque to build up and food to become lodged, which in turn leads to caries. Root resorption has been associated with the second molar teeth that sit next to impacted third molars. We found that the incidence of root resorption is incredibly low, at only 0.3%. This contradicts the findings of previous studies, who found frequencies of 7.5% and 0.60 %, respectively, which are in accordance with the vast

majority of previous analyses. Different definitions of root resorption might be used to explain the discrepancy in reported frequency. The fact that no differences in follicle size were identified over a 4-year or 12-year timeframe lends credence to the aforementioned notion. Therefore, both radiographic and histologic data were used to define a cyst in the current investigation [16-18]. We discovered that 1.4 percent of impacted mandibular third teeth have cystic development as a result. This is a lower frequency than what was previously reported. However, the frequency of pathologic conditions in our sample of 4.6 percent of teeth was close to the mean likelihood of 1.9 percent of cystic alterations determined from a thorough assessment of the literature. 0.8 percent and 4.6 percent of teeth in earlier radiographically based investigations studying pathologic alterations associated to impacted mandibular third molars exhibited dentigerous cyst development [19,20]. In the course of our examination, we found dentigerous cysts in roughly 0.8% of impacted mandibular third teeth. However, histological studies that looked at the follicular tissues of radiologically healthy teeth found that 34 to 46.5 percent of patients had concealed histologic anomalies that were possibly indicative of the development of dentigerous cysts.

## CONCLUSION

Therefore, it may be said that a dental follicle's radiographic appearance may not be a trustworthy predictor of the lack of illness. A mandibular third molar that is partially erupted and has experienced multiple episodes of pericoronitis has been specifically connected to a paradental cyst. In contrast to popular perception, we discovered a low incidence of this cyst in our study. This cyst is thought to be relatively frequent but underreported. It was discovered that a sizeable portion of the Jordanians' reported impacted mandibular third molars had a comparable pathologic lesion.

## REFERENCES

1. Staderini, E., Patini, R., Guglielmi, F., Camodeca, A., & Gallenzi, P. (2019). How to manage impacted third molars: Germectomy or delayed removal? A systematic literature review. *Medicina*, 55(3), 79.
2. National Institute for Clinical Excellence (NICE): Guidelines for wisdom teeth removals (updated November 2003). Available at: [http://www.nice.org.uk/Embcat.asp?pageoldsite/appraisals/wis/\\_guide.htm&d525](http://www.nice.org.uk/Embcat.asp?pageoldsite/appraisals/wis/_guide.htm&d525). Accessed January 200
3. Sewerin I, von Wowern N: A radiographic four-year follow up study of asymptomatic mandibular third molars. *Int Dent J* 40:24, 1990
4. Ahmad, P., V'ian, T., Chaudhary, F. A., Chaudhary, A., Haseeb, A. A., Yaqoob, M. A., & Asif, J. A. (2021). Pattern of third molar impactions in north-eastern peninsular Malaysia: A 10-year retrospective study. *Nigerian journal of clinical practice*, 24(7), 1028.
5. Altan, A., & Akbulut, N. (2019). Does the angulation of an impacted mandibular third molar affect the prevalence of preoperative pathoses?. *Journal of Dentistry*, 20(1), 48.
6. da Silva, V. P., de Luca Meyer, G., Daroit, N. B., Maraschin, B. J., de Oliveira, M. G., Visioli, F., & Rados, P. V. (2020). Pericoronal follicles revealing unsuspected odontogenic cysts and inflammatory lesions: A retrospective microscopy study. *Indian Journal of Dental Research*, 31(1), 80.
7. Mohammed, M. (2018). A 21-year Retrospective Histopathological Evaluation of Cysts and Tumours Associated with Impacted Teeth (Doctoral dissertation, University of the Witwatersrand, South Africa).
8. Jeevitha, J. Y., Thiagarajan, A., & Sivalingam, B. (2022). Influence and impact of mandibular ramal dimensions on the incidence of lower third molar impaction: A prospective study. *Journal of Pharmacy And Bioallied Sciences*, 14(5), 364.
9. Litonjua, L. S. (1997). Pathologic changes associated with the angulation of impacted mandibular third molars. *The Journal of the Philippine Dental Association*, 49(1), 14-19.
10. Singh, P., Nath, P., Bindra, S., Rao, S. S., & Reddy, K. R. (2018). The predictivity of mandibular third molar position as a risk indicator for pericoronitis: A prospective study. *National journal of maxillofacial surgery*, 9(2), 215.
11. Gupta, P., Naik, S. R., Ashok, L., Khaitan, T., & Shukla, A. K. (2020). Prevalence of periodontitis and caries on the distal aspect of mandibular second molar adjacent to impacted mandibular third molar: A guide for oral health promotion. *Journal of Family Medicine and Primary Care*, 9(5), 2370.
12. Berezowski, B., Phillips, V., & Cousin, G. (2018). The early dentigerous cyst: a previously unrecognised lesion in the third molar region. *Faculty Dental Journal*, 9(3), 100-102.
13. da Silva, V. P., de Luca Meyer, G., Daroit, N. B., Maraschin, B. J., de Oliveira, M. G., Visioli, F., & Rados, P. V. (2020). Pericoronal follicles revealing unsuspected odontogenic cysts and inflammatory lesions: A retrospective microscopy study. *Indian Journal of Dental Research*, 31(1), 80.
14. Hounsoms, J., Pilkington, G., Mahon, J., Boland, A., Beale, S., Kotas, E., ... & Dickson, R. (2020). Prophylactic removal of impacted mandibular third molars: a systematic review and economic evaluation. *Health Technology Assessment (Winchester, England)*, 24(30), 1.
15. Choi, J. (2022). Risk factors for external root resorption of maxillary second molars associated with third molars. *Imaging Science in Dentistry*, 52.
16. Ariizumi, D., Sakamoto, T., Yamamoto, M., & Nishii, Y. (2022). External Root Resorption of Second Molars Due to Impacted Mandibular Third Molars during Orthodontic Retention. *The Bulletin of Tokyo Dental College*, 63(3), 129-138.
17. Mohammad, S., Khan, M., & Ali, K. (2018). Frequency of common pathologies associated with impacted mandibular third molars teeth. *Pakistan Oral & Dental Journal*, 38(2), 169-172.
18. Santosh, A. B. R. (2020). Odontogenic cysts. *Dental Clinics*, 64(1), 105-119.
19. Verma, F. (2020). Paradental cyst: Misdiagnosed or underdiagnosed. *Journal of Dental Research and Review*, 7(3), 138.
20. Pinto, A. S., Costa, A. L., Pinto, M. C., Braz-Silva, P. H., Moraes, M. E., & Lopes, S. L. (2016). Characteristic MRI and cone beam CT findings in a case of paradental cysts arising in the bilateral retromolar regions of the mandible. *Journal of Oral and Maxillofacial Radiology*, 4(3), 83.