

Efficacy of Open Anderson-Hynes Pyeloplasty in Congenital Unilateral Uretero-Pelvic Junction Obstruction in Term of GFR in Children

FAIZ UR RAHMAN¹, SAIF UD DIN², ZIA ULLAH³, MUHAMMAD IBRAHIM SHUJA⁴, AHMAD ALI⁵, JEHANGIR KHAN⁶

¹Associate Professor General Surgery, Gaju Khan Medical College, Swabi

²Urologist, Nawaz Sharif Kidney Center Swat

³Assistant Professor General Surgery, Gaju Khan Medical College, Swabi

⁴Assistant Professor General Surgery, Gaju Khan Medical College, Swabi

⁵District Surgeon, Yar Hussain Hospital, Swabi

⁶Assistant Professor Paediatric Surgery Unit, Gaju Khan Medical College, Swabi

Corresponding author: Jehangir Khan, Email: Jehangirsaidkhani@gmail.com

ABSTRACT

Objective: To determine the efficacy of Open Anderson-Hynes pyeloplasty in unilateral congenital UPJO in terms of GFR, free drainage of urine from the pelvis to the ureter and symptomatic improvement in children aged 5 to 15 years.

Keywords: Pyeloplasty, Anderson-Hynes, Pediatric Pyeloplasty, Uretero-Pelvic Junction Obstruction

INTRODUCTION

Ureteropelvic junction obstruction is an anatomical abnormality that causes physiologically significant resistance to the flow of urine from the renal pelvis to the ureter. ¹The condition is more common in males and on the left side and may present with flank pain and hematuria². UPJ obstruction is diagnosed prenatally by maternal ultrasonography. In younger children it is commonly diagnosed by ultrasonography, intravenous urography and DTPA/MAG3 scan and VCUG to exclude vesico-uretero reflux which is present in up to 10% patients. ³

For the first time in the history Kuster did UPJO repair in 1891, later the dismembered pyeloplasty was described by the British plastic and urologic surgeons J.C Anderson and Wilfred Hynes ⁴. Anderson-Hynes dismembered pyeloplasty is effective in almost every case and improves function in more than 90% cases following the procedure ⁵. The follow up is usually done with post-operative USG, followed by IVU and further elaborated by DTPA/MAG3 after three months of surgery. ⁶

Another technique of flap instead of dismembered one was introduced by Foley in 1936 and was named as YV-plasty. ⁷In 1946, Anderson and Hynes presented the details of their procedure mentioning the dismembering, spatulation as well as resection of the redundant tissue of the renal pelvis. ⁸

Östling folds and incomplete re-canalization are considered the main causes of UPJ obstruction. ⁹

In Obstructed kidneys there is an increases in cyclooxygenase activity and also increased level of thromboxane synthetase is observed. ^{10,11}

In the obstructed kidney, renin-angiotensin activation leads to sclerosis and ACE inhibitors arrest this process. ¹²The obstruction also indirectly induces spasm of the renal vasculature leading to decrease in GFR. ¹³

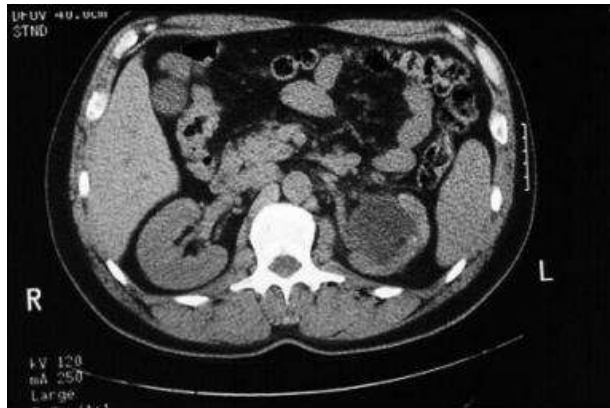


Fig 1: CT scan without contrast demonstrating severe left-sided hydronephrosis secondary to ureteropelvic junction obstruction.

Once the obstruction becomes chronic, there is collagen deposition paving way to renal fibrosis. ¹⁴

As the renal obstruction is hostile to the kidney and spontaneous resolution of hydro nephrosis is not always positive so early intervention is indicated. ^{15,16}

The internal drainage via DJS as recommended for six (6) weeks, but two weeks drainage is not inferior. ¹⁷: In paediatric patients external drainage via a feeding tube is preferred as this can be removed as a day case without anesthesia. ¹⁸

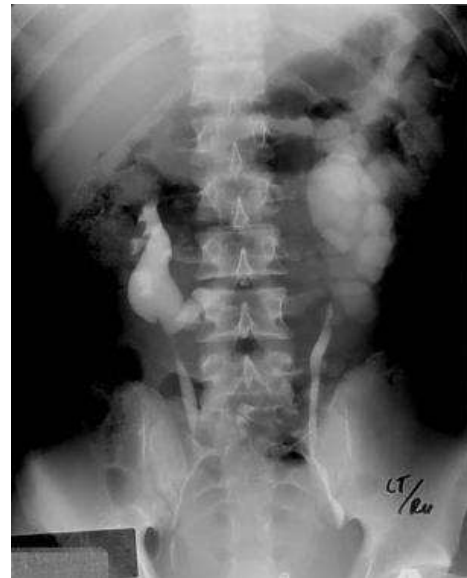

Fig 2: Excretory urogram shows a horseshoe kidney with left hydronephrosis

The association of horse-shoe kidney with UPJ obstruction is well known but other anomalies can also occur in combination. ¹⁹

METHODOLOGY

This descriptive study of 139 patients of paediatric age group was conducted in the department of urology, Institute of Kidney Diseases, Peshawar from 24 July, 2019 to 24 July 2020.

Patients meeting inclusion criteria i.e having primary unilateral UPJO, with split renal function >15% and age 5 to 15 years admitted in Urology Department of Institute of Kidney Diseases, Peshawar for surgery were included in study. The disease and the surgical procedure was explained to parents and written permission was obtained. The detailed history and clinical examination were recorded. Diagnosis of UPJO were made on sonogram, supported by contrast study like IVU/CTU and confirmed by MAG3/DTPA renal scan and further supported and

outlined by retrograde ureteropyelo-graphy. Operations were done through flank incisions , aberrant lower pole vessel identified if any, dismembered pyeloplasty performed using 4/0 polyglycol running or initial two interrupted sutures. In majority DJS put antegradely and also a drain in all cases. Postoperative complications were recorded and efficacy of the procedure noted in term of GFR improvement, free drainage of contrast from the pelvis to the ureter and abolishment of the symptoms. Post operatively DJS was removed after six weeks and follow up ultrasound followed by nuclear scan was done after 2 months to see improvement/arrest of deterioration in renal function and smooth flow of urine without resistant at UPJ.

RESULTS

Out of 139 patients, 60(43.16%) were of age 5-10yrs and 79(56.83%) i.e the majority were 11-15yrs with mean and SDs of 11+_ 2.37. Amongst 139, 89(64.02%) were males and 50(35.97%) were females. The post- operative complications were early and delayed. The early complications were fever in 33 (23.74%)patients, visible hematuria in 6(4.31%) patients, leakage of urine in 7(5.03%) patients. The urine leakage settled in the majority of the patients within 2 to 3 days without intervention. Delayed complications as re-stenosis occurred in 5(3.5%) and required surgical intervention as endo- pyelotomy or redo pyeloplasty. The overall complication rate was 36.69%. The efficacy in terms of GFR improvement OR at least prevention of deterioration of renal function was recorded in 115 (82.73%) patients while 24(17.26%) showed no efficacy. The efficacy of the pyeloplasty was predicted by the duration of the hospital stay. In 115 patients with less than 3days hospital stay 96(69.01%) gained improved renal functions while 19(13.66%) did not. A total of 24 patients stayed for more than 3days, 19(13.66%) patients benefited from the surgery while 05(3.59%) showed no efficacy.

Table 1: Descriptive Statistics (n=139)

Numerical Variables	Mean	SDs
Age	11	2.37
Duration of hospital stay	3	0.84

Table 2: Frequency and Percentages for Age (n=139)

Age Groups	Frequencies	Percentages
5-10 Years	60	43.16%
11-15 Years	79	56.83%
Total	139	100%

Table 3: Frequency and Percentages for Gender (n=139)

Gender Groups	Frequencies	Percentages
Male	89	64.02%
Female	50	35.97%
Total	139	100%

Table 4: Frequency and Percentages for Efficacy (n=139)

Efficacy	Frequencies	Percentages
Yes	115	82.73%
No	24	17.26%
Total	139	100%

Table 5: Stratification of Efficacy with Age (n=139)

Age Groups	Efficacy	Frequencies	Percentages	P Value
5-10 Years	Yes	50	35.97%	0.870
	No	10	07.19%	
11-15 Years	Yes	65	46.76%	
	No	14	10.07%	

Table 6: Stratification of Efficacy with Gender (n=139)

Gender Groups	Efficacy	Frequencies	Percentages	P Value
Male	Yes	72	51.79%	0.445
	No	17	12.23%	
Female	Yes	43	30.93%	
	No	07	5.03%	

Table 7: Stratification of Efficacy with Duration of Hospital Stay (n=139)

Duration of Hospital stay	Efficacy	Frequencies	Percentages	P Value
< 3 Days	Yes	96	69.01%	0.611
	No	19	13.66%	
> 3 Days	Yes	19	13.66%	
	No	05	3.59%	

DISCUSSION

The purpose of this study is to judge the efficacy of open Anderson-Hyne pyleoplasty. The efficacy measured by improvement in GFR or preservation of the renal function and preventing deterioration of function, resulting from no or physiologically insignificant resistance to urine move from renal pelvis into the ureter. This also makes the patient asymptomatic.

The study provided the evidence that open Anderson-Hyne pyeloplasty is the very much reasonable and most successful option to treat UPJO (20).

In dismembered pyeloplasty we remove the diseased abnormal UPJ and restore the continuity of the renal pelvis to the ureter. (21) Though the dismembered pyelo-plasty has its roots back in the history in1891 by Kuster and 1949 by Anderson-Hynes but the outcome is very much comparable to the newer laparoscopic technique. (.22,23).

Majority of our patients (n=79, 56.83%) were in the age group of 11-15 years which in contrast to the age spectrum cited by Mughal and Soomro in their study where the majority (60%) were 1-5 years. (24)

The male patients were more in number (n=89, 64.02%) than female patients (n=50, 35.97%) showing male to female ratio 2:1, which is more like mentioned in the literature .(25)

In our study we noticed some minor complications as fever (n=33, 23.74%), self limiting visible hematuria (n=6, 4.3%), and urine extra- vasation (n=7, 5.03%). In comparison the local study by Rafique Ahmed Sahito and Bshir Ahmed Soomro, fever rate (23.74%) was high in our patients while they recorded in 16.67% patients, while hematuria was 4.31% in ours and 3.33% in their study, much more comparable. We recorded 5.03% leakage of urine as compared to 3.33% by them. The re-stenosis which is the late complication of the procedure after three months was 3.5% in our observations while it was 11.1% in the study conducted by Marcin Polok and Wojciech Apoznanski (26).

The efficiency as determined by improvement in GFR, prevention of further deterioration and symptomatic relief was 82.7% in our set up while reported 95% in literature for pyelo plasty and is considered as the gold standard .(27)

CONCLUSION

Anderson-Hynes pyeloplasty is an effective procedure in terms of renal function improvement or to prevent GFR deterioration at the pre-operative level in comparison to those not operated with gradual reduction in GFR.

REFERENCES

1. Majumder NK, Amin MR, Khastgir R, Rehman M, Akan MAB. Post A-H Pyeloplasty Analysis of renal functionin unilateral hydronephrosis due to congenital pelvi ureteric junctio obstruction. J Paediatr Surg Bangladesh. 2011;2(2):53-55
2. Sahito RA, Soomro BA, Qureshi MA. an experience of open anderson hynes pyeloplasty. J Surg Pak;2013;18(3):135-8.
3. Goel P, Gupta DK. Post operative results following surgery for PUJO in children. J Paediatr Surg Bangladesh ;2010;1(1):53-64.
4. Siddique M, Pansota MS, Saleem MS, Rehman AU. Outcome of pyeloplasty in children. J Ayub Med Coll Abbottabad;2014;26(1):71-5.
5. Shahinoor AM. Outcome of external and internal drainageof urine after Anderson hynes pyeloplasty: a comparative study. J Paediatr Surg Bangladesh. 2011;2(1):25-8.
6. Srinivas KK, Uppin IV, Nerle RB. A prospective randomized controlled trial complains open pyeloplasty and laparoscopic pyeloplasty for ureteropelvicjunction obstruction (UPJO). J Clin Diagnostic Res;2011;5(8):1601-5.

7. Foley FB. A new plastic operation for stricture at the ureteropelvic junction. *J Urol.* 1936. 38:643.
8. Anderson JC, Hynes W. Retrocaval ureter; a case diagnosed pre-operatively and treated successfully by a plastic operation. *Br J Urol.* 1949 Sep. 21(3):209-14. .
9. Ostling J. The genesis of hydronephrosis: Particularly with regard to the changes at the ureteropelvic junction. *Acta Chir Scand.* 1942. 8:72.
10. Morrison AR, Nishikawa K, Needleman P. Thromboxane A2 biosynthesis in the ureter obstructed isolated perfused kidney of the rabbit. *J Pharmacol Exp Ther.* 1978 Apr. 205(1):1-8. .
11. Morrison AR, Nishikawa K, Needleman P. Unmasking of thromboxane A2 synthesis by ureteral obstruction in the rabbit kidney. *Nature.* 1977 May 19. 267(5608):259-60. .
12. Ishidoya S, Morrissey J, McCracken R, Klahr S. Delayed treatment with enalapril halts tubulointerstitial fibrosis in rats with obstructive nephropathy. *Kidney Int.* 1996 Apr. 49(4):1110-9. .
13. Pimentel JL Jr, Sundell CL, Wang S, Kopp JB, Montero A, Martínez-Maldonado M. Role of angiotensin II in the expression and regulation of transforming growth factor-beta in obstructive nephropathy. *Kidney Int.* 1995 Oct. 48(4):1233-46.
14. Furness PD 3rd, Maizels M, Han SW, et al. Elevated bladder urine concentration of transforming growth factor- beta1 correlates with upper urinary tract obstruction in children. *J Urol.* 1999 Sep. 162(3 Pt 2):1033-6.
15. Pettersson BA, Aperia A, Elinder G. Pathophysiological changes in rat kidneys with partial ureteral obstruction since infancy. *Kidney Int.* 1984 Aug. 26(2):122-7.
16. Koff SA, Campbell K. Nonoperative management of unilateral neonatal hydronephrosis. *J Urol.* 1992 Aug. 148(2 Pt 2):525-31.
17. Mandhani A, Kapoor R, Zaman W, Kumar A, Bhandari M, Gambhir S. Is a 2-week duration sufficient for stenting in endopyelotomy?. *J Urol.* 2003 Mar. 169 (3):886-9. .
18. Taveres A, Manaboriboon N, Lorenzo AJ, Farhat WA. Insertion of an internal-external nephroureteral stent during pediatric laparoscopic pyeloplasty: description of the technique. *Urology.* 2008 Jun. 71 (6):1199-202.
19. Blanc T, Koulouris E, Botto N, Paye-Jaouen A, El-Ghoneimi A. Laparoscopic pyeloplasty on horseshoe kidney in children. *J Urol.* 2013 Oct 16.
20. Poulakis V, Witzsch U, Schulthesis D, Rathert P, Becht E. History of uretero-pelvic junction obstruction repair(pyeloplasty). From Tendelenburg (1886) to present.
21. Sutherland RW, Chung SK, Roth DR, Gonzales E. Paediatric pyeloplasty: outcome analysis based on patient age and surgical technique. *Urology* 1997 ;50 :963-6.
22. Schussler WW, Grune MT, Tecuan huey LV, Preminger GM. Laparoscopic dismembered pyeloplasty. *J Urol.* 1993 ; 150: 1795-9.
23. D. Duane B, Jennifer AD, Nancy W, Elspeth M. Single center comparison of laparoscopic pyeloplasty, endopyelotomy and open pyeloplasty. *J Endo Urol.* 2003; 17: 155-60.
24. Mughal SA, Soomro S. pelvi ureteric junction obstruction in children. *J Surg Pakistan.* 2008; 13: 163-6.
25. Grasso M, Cohen JH, Rajamahanty S, Gitlin JS, Johnson GB. Uretero pelvic junction obstruction. Last Updated on 14 feb@013(cited October 2013) available at www.emedicine.com :
26. Polok M, Apoznanski W. Anderson-Hynes pyeloplasty in children-longterm outcome; how long follow up is necessary? *Cent European J Urol* 2017; 70 (4) : 434-38.
27. Sweeny DD, Ost Mc, Schneck FX, Docimo SG. Laparoscopic pyeloplasty for uretero pelvic junction obstruction in children. *J Laparoendoscopic Adv. Surg. Tech A* 2011;261-5.