

Comparison of Outcomes of PHILOS for Proximal Humerus Fracture in Middle Aged Patients Based on Early Surgery vs Late Surgery

MUHAMMAD SALMAN KHALIL UPPAL¹, AFFAN ZIA BAJWA², MIRZA ZEESHAN SIKANDAR³, UMAIR ABU BAKAR SIDDIQ⁴, BILAL KHAN⁵, MUHAMMAD ABU BAKAR⁶

¹Department of Orthopedics, Central Park Medical College, Lahore.

²Department of Orthopedics, Jinnah Hospital Lahore.

^{3,4}Department of Orthopedics, Central Park Medical College, Lahore.

⁵Department of Medicine, Jinnah Hospital Lahore.

MBBS Student, Central Park Medical College, Lahore.

Correspondence to Dr. Mirza Zeeshan Sikandar, Email: m.zee.shan@hotmail.com, Cell: +92-336-8656736

ABSTRACT

Background: Proximal humeral fractures are third most commonly occurring fractures of old age. PHILOS plate gives maximum fracture stabilization in the treatment of proximal humeral fractures of old age.

Aim: To assess the effect of PHILOS in the management of proximal fractures of humerus and its effect on DASH scores.

Methodology: A comparative cross-sectional analytical study was carried out from February to July 2022. Healing and functional outcome was assessed at 24 weeks using quick Disabilities of Arm, Shoulder and Hand score ranging from 0 to 100 where <65 reflects excellent prognosis, 65-79 means good prognosis, 80-89 satisfactory and 90-100 reflects poor prognosis.

Results: A total of 106 patients volunteered in this research, with the mean age of 53.92±5.28 years, among those 92(86.79%) were males & rest 14(13.21%) were females. The patients who reported earlier have excellent prognosis when compared with those who reported after 5 days with p value .007, among those who had good response majority reported before 5 days with p value .06.

Conclusion: Early presentation and prompt management of proximal humeral fractures can have better prognosis and can prevent disability.

MeSh Words: Fracture, PHILOS, proximal humerus, DASH.

INTRODUCTION

Proximal humeral fractures are third most commonly occurring fractures of old age after hip and distal radius fractures¹. Since last decade, incidence of low energy osteoporotic fractures are increasing resulting in greater frequency of humeral fractures². Although, fractures of humeral shaft can be managed by conservative means but lack of compliance, poor healing skin and osteoporotic changes in elderly patients, make them unsuitable for conservative management³. Complex proximal humeral fractures resulting in three to four parts occur in almost every patient over the age of 60 years⁴.

Various operative techniques are in practice, including ORIF with proximal humeral plates, hemi-arthroplasty, percutaneous (i.e. screw osteosynthesis, pinning) and intramedullary nails⁵. While employing the Proximal Humeral Internal Locking System (PHILOS), the plate immobilizes fracture site in compression mode; it works as a stable construct, converting shear stress at the screw-bone interface⁶. Biomechanical studies has suggested potential advantages over other plating techniques, including improved stiffness and stability at the fracture site, particularly in complex comminuted or osteoporotic bone⁷. Fixation of proximal humerus fractures with PHILOS is associated with a reliable functional outcome in two piece and three piece fractures in elderly population⁸.

In our elderly population which is significantly deficient in Calcium and Vitamin D₃ and thus more prone to early onset osteoporosis⁹. In international studies the outcome showed that PHILOS plate gives maximum fracture stabilization in the treatment of proximal humeral fractures of old age. In spite of being one of common orthopedic injuries, satisfactory management of proximal humerus fractures is still an active topic of debate. **PHILOS** is one of the emerging and convenient management of proximal compound fractures of humerus with most satisfactory results in elderly patients but data in local populace is lacking therefore this study is being conducted.

The objective of the study was to assess the effect of PHILOS in the management of proximal fractures of humerus and its effect on DASH scores.

METHODOLOGY

A comparative cross-sectional analytical study was conducted at orthopedics department of Central Park Teaching Hospital in collaboration with orthopedics department of Jinnah Hospital Lahore from February 2022 to July 2022. Random-convenient sampling method was employed and patients age ranging from 45 to 65 years with history of 2 to 4 part fracture of proximal humerus as per Neer (grade 2, 3 & 4) Classification were included in the study after getting prior written informed consent and ethical letter from Institutional Review Board of Central Park Medical College and Teaching Hospital. While the patients with history of multiple injuries, bilateral fractures, glenohumeral joint dislocation and bone tumors were not included in study as per of exclusion criterion. Sample size was calculated by using WHO sample size calculator with confidence interval of 95%, margin of error at 7% and frequency of excellent outcome at 16 percent and then a total of 106 patients were recruited.

A detailed demographic history was collected and surgery was performed under general anesthesia with administration of antibiotics according to protocol and policy by consultant orthopedic surgeon. Access to the proximal humerus was achieved via delto-pectoral approach & same type of PHILOS plate was used in all cases and the reduction was finally affirmed with lateral axillary and antero-posterior (AP) views on the image intensifier. The skin was stitched over suction drains that were cut off after 20 hours and patient was discharged with poly arm sling.

At two weeks of follow up the brace was removed and passive as well as active movements were started, supported by an adjustable & removable brace (splint). At 6 weeks after surgery, the brace was disposed of and strengthening exercises were started. The patients were followed up at 2 weeks, 6 weeks, 12 weeks with x-ray to determine radiological healing and functional outcome was checked and calculated at 24 weeks using Quick Disabilities of Arm, Shoulder and Hand score (**QUICK DASH SCORE**) (10) ranging from 0 (no disability) to 100 (most severe disability); where < 65 reflects excellent prognosis, 65-79 means good prognosis, 80-89 means satisfactory and 90-100 reflects poor prognosis. Patients were categorized as excellent (DASH<65), good (DASH 65-79), satisfactory (DASH 80-89) and poor (DASH 90-100)¹¹. Effect modifiers like age, gender, BMI, duration of

Received on 03-08-2022

Accepted on 17-09-2022

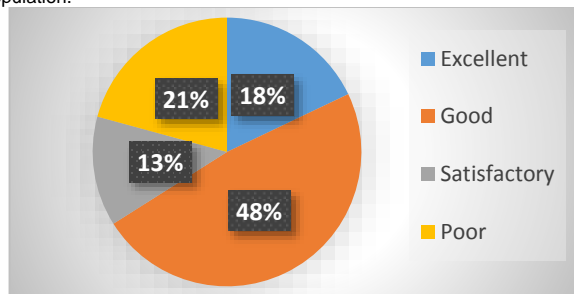
fracture was addressed by stratification of data. All the information was recorded in a structured questionnaire.

Statistical analysis: The data was entered and was duly compared for errors in SPSS version 23. Qualitative variables were assessed and data was presented in frequencies and percentages. Post stratification chi square test was employed to check the prognostic differences of DASH scores based among study groups. A p value ≤ 0.05 was regarded as significant.

RESULTS

A total of 106 patients volunteered in this research, with the mean age of 53.92 ± 5.28 years, among those 92(86.79%) were males & rest 14(13.21%) were females. All the participants (patients) were overweight with the average BMI of 30.70 ± 2.97 kilogram/meter². The average duration of fracture in patients was 4.14 ± 1.70 days. Frequency of various end results of PHILOS plate fixation in proximal fractures of humerus based on DASH scores were recorded as excellent in 19(17.92%), good in 51(48.11%), satisfactory in 14(13.21%) and poor in 22(20.76%).

Figure 1. Explaining the Functional Outcomes of PHILOS in Study Population.



Outcomes of the PHILOS were compared on the basis of period of fracture fewer than 5 days and greater than 5 days. On appliance of chi-square test the prognosis of PHILOS based on DASH score were compared for duration lesser and greater than 5 days as explained in table 1. The patients who reported earlier have excellent prognosis when compared with those who reported after 5 days with p value of .007, among those who had good response majority reported before 5 days with p value of .06. On comparative assessment based on stratification of gender, BMI and age no significant difference in the functional utility of PHILOS was observed.

Table 1: Comparative assessment of fracture duration on outcomes of PHILOS based on DASH Scores.

Outcome of PHILOS	Duration of fracture		P value
	<5 days	>5 days	
Excellent	10	9	0.007
Good	43	8	0.06
Satisfactory	12	2	0.37
Poor	16	6	0.64

DISCUSSION

The current research work was carried out to ascertain the functional effectiveness of PHILOS plate fixation in deranged proximal humeral fractures in our aging population and frequency of various outcomes of proximal humeral interlocking system (PHILOS) plate fixation in proximal fractures of humerus was recorded as excellent in 19(17.92%), good in 51(48.11%), satisfactory in 14(13.21%) and poor in 22(20.76%). The findings of our study are in agreement with a study where the PHILOS plate was placed and used for internal adjustment & fixation of displaced proximal fractures of humerus in more than 25 patients. The results were excellent in 4 patients (16%), good in 11 patients (44%), satisfactory in 4 patients (16%) and poor in 6 patients (24%). After 24 weeks of follow up, an average score of 57.4 was

attained. They concluded that the PHILOS, is linked with good functional outcomes (satisfactory results) in two part and three part fractures in elderly population^{12,13}.

Martinez AA et al. evaluated the effectiveness of fixation with PHILOS plate in proximal fractures of humerus. They recorded that the patients were checked and re-assessed for one (12 months) to one and half (18 months) years with mean of 15 months. All the patients were rehabilitated competently beside in a single patient with a 4-component valgus fracture who couldn't heal due to associated osteomyelitis. There was no associated complications including wound infections, vascular injuries and avascular necrosis leading to loss of fixation. The average scores was 80 (range 40-100). These results are consistent with our study^{14,15}.

Although our study was limited to recording only functional outcomes, we found that the failure rate was low, apparently due to good bone quality and employment of advanced surgical techniques. While preparing and reaching to the head with proximal locking screws, care must be taken not to damage & pierce the anterior humeral artery and the axillary nerve. The position of screws must be assessed and confirmed intraoperatively under the affirmation of image intensifier¹⁶⁻¹⁷. In old patients with poor bone structure and advancing osteoporosis, the head of humerus and shaft must be filled with bony prosthesis or substitutes to manage and prevent screw fixation failure.

CONCLUSION

We conclude that fixation of proximal fractures of humerus with locking proximal humeral plates is linked with suitable good functional outcomes. Early presentation and prompt management of proximal humeral fractures can have better prognosis and can prevent disability. Based on our observations, inadequate implant placement can lead to reduced functional outcome.

Conflict of interest: Nil

REFERENCES

- Antti P, Vesa L, Tapio F. Conservative treatment, plate fixation, or prosthesis for proximal humeral fracture. A prospective randomized study. *BMI Musculoskelet Disord* 2012;713:167.
- Dietmar K, Nicola B, Stephan R. Predicting failure after surgical fixation of proximal humerus fractures. *Journal of trauma* 2011;42:1283-8.
- Mario R, Michael D, Tenzin Let. Minimal invasive long PHILOS-plate osteosynthesis in metadiaphyseal fractures of the proximal humerus. *Journal of injury*. 2010;41:1277-83.
- Gerhard K, Laurent A, Simon L. Similar outcomes for nail versus plate fixation of three part proximal humeral fractures. *Clin Orthop Relat Res* 2014;70:602-9.
- Masoud N, Mohammad N, Mehdi H. Clinical results of using the proximal humeral internal locking system plate for internal fixation of displaced proximal humeral fractures. *Am J Orthop* 2012;41:64-8.
- Brandon S, Crispin C, James H. Outcomes after fixation of proximal humerus (OTA Type II) fractures in the elderly patients using modern techniques. *Geriatr Orthop Surg Rehabil* 2013;4:21-5.
- Robert C, Jaicharan J, Zlatko D. A systematic review of locking plate fixation of proximal humerus fractures. *Injury* 2011;42:408-13.
- Vivek B, Sohal S, Bhoparai S. PHILOS plate fixation in proximal humeral fractures-its functional outcome and complications. *International Journal of Orthopaedics* 2015;2:3
- Shah SIA, Iqbal S, Sikandar MZ, Qazi, UY, Haq I. Serum Vitamin D and Cardiometabolic Markers: A Comparative Study in Adult Men Based on Body Mass Index. *IJUM Medical Journal Malaysia*.2021;20(2):67-74.
- Olsson C, Petersson CJ. Clinical importance of comorbidity in patients with a proximal humerus fracture. *Clin Orthop Relat Res*. 2006;442:93-9.
- Schwartz AV, Nevitt MC, Brown Jr BW, Delsey JL. Increased falling as a risk factor for fracture among older women: the study of osteoporotic fractures. *Am J Epidemiol*. 2005;161:180-5.
- Bukhari SAH. Proximal Humeral Fractures: An Experience With PHILOS Fixation. *Journal of Surgery Pakistan (International)* 2014;19:62-5.
- Robinson CM, Stone OD, Murray IR. Proximal humeral fractures due to blunt trauma producing skin compromise. *J Bone Joint Surg Br*. 2011;93(12):1632-7.
- Warrender WJ, Oppenheimer S, Abboud JA. Nerve monitoring during proximal humeral fracture fixation: what have we learned. *Clin Orthop Relat Res*. 2011;469(9):2631-7.
- Foroohar A, Tosti R, Richmond JM, Gaughan JP, Ilyas AM. Classification and treatment of proximal humerus fractures: inter-observer reliability and agreement across imaging modalities and experience. *J Orthop Surg Res*. 2011;6:38.
- Rangan A, Handoll H, Brealey S, et al. Surgical vs nonsurgical treatment of adults with displaced fractures of the proximal humerus: the PROFHER randomized clinical trial. *JAMA* 2015; 313:1037.
- Handoll HH, Keding A, Corbacho B, et al. Five-year follow-up results of the PROFHER trial comparing operative and non-operative treatment of adults with a displaced fracture of the proximal humerus. *Bone Joint J* 2017; 99-B:383.