

The Success of the Bishop-Koop Surgery in Newborns with Meconium Ileus and Congenital Intestinal Atresia When Compared to Divided Stomas

ASAD IQBAL¹, GAURI SHANKAR PANDIT², MUHAMMAD TAYYAB AZAM³, SAFINA KARIM⁴, HAFIZ MUBASHIR RASOOL⁵, NAHIDA BURKI⁶, RANJANA KUMARI PANDIT⁷, NADEEM AKHTAR⁸

^{1,5}PGR Pediatric Surgery Children Hospital PIMS

³MO General Surgery PIMS

⁴Medical Officer Paediatric Surgery

^{5,6}PGR Pediatric Surgery Children Hospital PIMS

⁷MO Careplus Hospital G-8 Markaz

⁸Professor Pediatric Surgery Children Hospital PIMS

Corresponding author: Gauri Shankar Pandit, Email: gspandit9@gmail.com

ABSTRACT

Objective: The purpose of this study is to compare the Bishop-Koop procedure (BK) to the divided stoma in newborns with meconium ileus (MI) and congenital intestinal atresia.

Study Design: Retrospective study

Place and Duration: Children Hospital PIMS, Dec-2021-Jun 2022

Methods: There were seventy six neonates were presented in this study. Included neonates had meconium ileus (MI) and congenital intestinal atresia (CIA) and admitted to Hospital for surgery. Patients were equally divided in two groups. Group I received divided stoma (DS) among 38 neonates and group II received Bishop-Koop procedure (BK) in 38 cases. Outcomes among both groups were compared in terms of surgery time, complications, and hospital stay. Mean standard deviation was used for data presentation.

Results: There were 42 males (21 in each group) and 34 female (17 in each group) neonates among all cases. Mean age of the neonates in group I was 8.5±4.16 days. Meconium ileus was found in 21(55.3%) in group I and 20 (52.6%) in group II and the rest of the neonates among both groups had congenital intestinal atresia. Mean operative time in group I was higher 180.7±9.34 minutes as compared to group II 110.3±7.26 minutes. We found that hospitalization in group II was lower 3.11±5.40 days as compared to group I 10.2±9.17 days. Frequency of complications in group I was higher found in 8 (21.5%) cases as compared to group II in 4 (10.5%) cases.

Conclusion: In comparison to DS ostomies, we came to the conclusion that the BK approach is a safe, dependable, and acceptable technique for newborn surgery with a low risk of complications and shorter operating time and duration of hospital stay after ostomy closure.

Keywords: Divided Stoma, Bishop-Koop, Meconium ileus, Congenital Intestinal Atresia, Complications

INTRODUCTION

All newborn intestinal disorders, including congenital intestine atresia (CIA), enteritis (NEC), and meconium ileus (MI), require emergency surgery. Different surgical procedures, such as a Bishop-Koop (BK) or Santulli enterostomy (SE), [1-4] a primary anastomosis (PA) to follow colon resection, the formation of such a momentarily diverting stoma (DS), and an anal fissure in continuity, necessitate different intraoperative judgments for different patients. [5,6]

After bowel resection, the PA encourages a single-stage surgery that preserves intestinal autonomy. But the prevalence of anastomotic leaks varies between 1.6% and 31% [1-8] without the establishment of a proximal protective enterostomy.

Removing the dilated ileum and performing a Bishop-Koop ileostomy, a Santulli surgery, or a Mikulicz procedure are surgical options for treating uncomplicated meconium ileus. These are major surgeries connected to a shortening of the gut and a high stoma output. Furthermore, a second procedure is required to close the stoma [9]. Our facility has been using Bishop Koop ileostomies for a long time since they utilise the distal absorptive region and allow distal transit of intestinal material. Normal bowel movements eventually start to occur, and the stoma stops working. It is a complicated operation that includes end-to-side anastomosis and the removal of dilated gut. The need for a second surgery to close the stoma is greater due to the higher incidence of postoperative complications [9].

The Bishop-Koop operation (BK) and the Santulli enterostomy are two procedures that can be used as an alternative to PA and the divided stoma. These procedures allow for appropriate bowel decompression while concurrently preserving intestinal transit (DS). The end of the proximal limb is anastomosed to the side of the distal (BK) limb, and the enterostomy (or "chimney") is pulled out from the distal end of the distal limb after intestinal segment removal. In contrast, the SE mirror image has the enterostomy located closer to the upper

body. [10] Because of the wide range in complication rates and outcomes between surgical procedures, it is important to make a thorough comparison of your options before settling on the one that would have the least impact on your life thereafter.

In the present study, we examined neonates with meconium ileus (MI) and congenital intestinal atresia, and we compared the Bishop Koop method with divided stomas (CIA).

MATERIAL AND METHODS

This Retrospective study was conducted at Children Hospital PIMS and comprised of 76 neonates. After obtaining informed written consent from the parents of neonates, detailed demographics were recorded. The study excluded children older than 6 months of age and newborns with concomitant congenital defects, such as abdominal malformation or Hirschsprung disease. Also eliminated were newborns with congenital disorders that affect several organ systems.

The following information was collected: birth weight, age, gestational age and weight at the time of surgery, rationale for surgical therapy, degree of intestinal diversion, timing of stoma function and closure, and problems directly associated with the ostomy. Patients were divided in two groups.

Regardless of the distance between the stoma's proximal and distal ends, any bowel discontinuity was considered a DS. Separated ostomies were stitched back together and attached to the fascia. Bishop-Koop anastomosis was performed surgically under general anaesthesia. They were performed by one of four highly trained paediatric surgeons. Segment bowel resection or other appropriate surgical procedures to treat the underlying problem was performed after an abdominal examination. A stoma was created in the distal intestine, and it is common practise to reattach the proximal intestine to the stoma from the side. A method of continuous sewing on a single layer was used. To expose the distal bowel extension, an end enterostomy, also called a "chimney," was constructed. There was a lack of routine usage

of postoperative evacuation. Values are displayed as whole numbers, percentages, means and standard deviations, medians and ranges, or other appropriate formats. The statistical analysis was performed in SPSS 24. Data that did not follow a normal distribution were compared using the Mann-Whitney U test, whereas normally distributed data were subjected to the Student t test for statistical significance. The chi-square and F test tests were used to compare the rates of complications between the two groups. The threshold of significance was set at .05.

RESULTS

There were 42 males (21 in each group) and 34 female (17 in each group) neonates among all cases. Mean age of the neonates in group I was 8.5±4.16 days and in group II mean age was 10.8±5.26 days. Mean gestational age in group I was 35.11±2.31 weeks and in group II mean gestational age was 36.1±7.20 weeks. Meconium ileus was found in 21(55.3%) in group I and 20 (52.6%) in group II and the rest of the neonates among both groups had congenital intestinal atresia.(table-1)

Table-1: Baseline characteristics of neonates

Variables	Group I	Group II
Mean age at Surgery (days)	8.5±4.16	10.8±5.26
Mean gestational age (weeks)	35.11±2.31	36.1±7.20
Gender		
Male	21 (55.3%)	21 (55.3%)
Female	17 (44.7%)	17(44.7%)
Type of illness		
MI	21(55.3%)	20 (52.6%)
CIA	17 (44.7%)	18 (47.4%)

Mean operative time in group I was higher 180.7±9.34 minutes as compared to group II 110.3±7.26 minutes. We found that hospitalization in group II was lower 3.11±5.40 days as compared to group I 10.2±9.17 days.(table-2)

Table-2: Comparison of operative time and hospital stay

Variables	Group I	Group II	P Value
Mean operative time (minutes)	180.7±9.34	110.3±7.26	0.002
Hospitalization (days)	10.2±9.17	3.11±5.40	0.004

Table-3: Complications among both groups

Variables	Group I	Group II
Complications		
Yes	8 (21.5%)	4 (10.5%)
No	30 (78.5%)	34 (89.5%)
Type of Complications		
Surgical Site Infection	4 (10.5%)	1 (2.6%)
Anastomotic leak	2 (5.3%)	1 (2.6%)
Skin excoriation	2 (5.3%)	2 (5.3%)

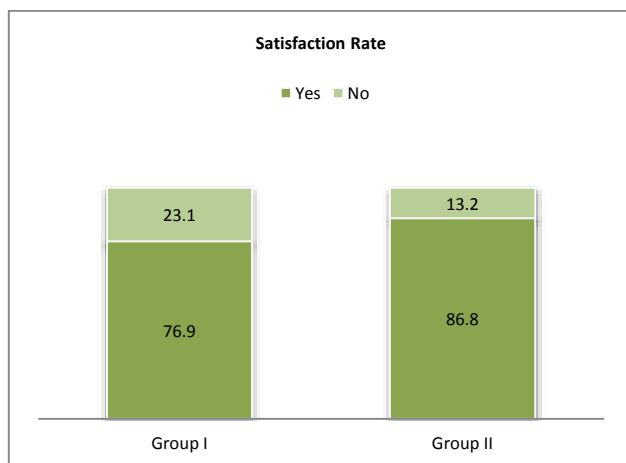


Figure-1: Comparison of satisfaction rate

Frequency of complications in group I was higher found in 8 (21.5%) cases as compared to group II in 4 (10.5%) cases.(table-3)

We found that satisfaction rate among parents of BK group was higher found in 33 (86.8%) cases as compared to DS group in 29 (76.3%).(Figure-1)

DISCUSSION

The current study showed that following BK formation, problems were less common than with DS. The closing of BK was linked to a shorter hospital stay and quicker surgical times. Despite these possible advantages, there are very few data on BK use in newborns. In our study, problems that followed BK development occurred 10.5% of the time. From 0.0% to 19.9% for the development of BK ostomies and from 0.0% to 7.4% for their closure, the range of BK-related problems reported in the literature.[11,12]

The use of Bishop-koop and Santulli surgical techniques, according to Eltayeb et al. [13], improved the survival of newborns with intestinal atresia and reduced postoperative sequelae such intestinal leak, prolonged intestinal motility, septicemia, and disseminated intravascular coagulopathy. Up to 2.6% of individuals experience anastomotic leakage after BK development, according to the literature. [14] Prior research, however, shows that if a PA is performed without the use of a protective ostomy, there is a variable risk of anastomotic complications that can range from 15percentage points to 30% with MI,[15] from 6% to 10percentage points for CIA, as well as from 5% to 12% for NEC. [16] We propose that the diverting ostomy, which acts as a vent and shields the anastomosis, is the reason BK has a lower risk of anastomotic problems than DS.

In the current study, only one patient received conservative care after developing wound infections during ostomy reversal in the BK group. This result is consistent with earlier studies in which wound infections following stoma closure have been reported to occur anywhere from 0.0% to 7.4% of the time. [17] Anastomotic leakage and SSI, on the other hand, happened more frequently and severely in the DS group after ostomy reversal. The distinctions are explained by the absence of the requirement for an anastomosis after BK removal, with the reversal technique requiring just chimney closure.

In current study, mean operative time in DS group was higher 180.7±9.34 minutes as compared to BK group110.3±7.26 minutes. We found that hospitalization BK group was lower 3.11±5.40 days as compared to DS group 10.2±9.17 days. Additionally, the prospective benefits of early ostomy closure are relativized by the special anatomical benefit of BK anastomosis, which retains intestinal continuity and preserves the electrolyte and fluid balance. However, there isn't any agreement on when ostomy reversal should be done. There is actually no noticeable difference in the rate of complications of newborns who enterostomy was reverse within 8 weeks (27-31%) or after eight weeks (19-23%) following its construction, despite the fact that several studies have attempted to find the best timing to closure an enterostomy.[18-20]

CONCLUSION

In comparison to DS ostomies, we came to the conclusion that the BK approach is a safe, dependable, and acceptable technique for newborn surgery with a low risk of complications and shorter operating time and duration of hospital stay after ostomy closure.

REFERENCES

- 1 Karimi A, Gorter RR, Sleeboom C, et al. Issues in the management of simple and complex meconium ileus. *Pediatr Surg Int* 2011;27:963–8
- 2 Hillyer MM, Baxter KJ, Clifton MS, et al. Primary versus secondary anastomosis in intestinal atresia. *J Pediatr Surg* 2018;54:417–22.
- 3 Singh M, Owen A, Gull S, et al. Surgery for intestinal perforation in preterm neonates: anastomosis vs stoma. *J Pediatr Surg* 2006;41:725–9.

- 4 Jawaheer J, Khalil B, Plummer T, et al. Primary resection and anastomosis for complicated meconium ileus: a safe procedure? *Pediatr Surg Int* 2007;23:1091-3.
- 5 Stollman TH, de Blaauw I, Wijnen MH, et al. Decreased mortality but increased morbidity in neonates with jejunoileal atresia; a study of 114 cases over a 34-year period. *J Pediatr Surg* 2009;44:217-21.
- 6 Guelfand M, Santos M, Olivos M, et al. Primary anastomosis in necrotizing enterocolitis: the first option to consider. *Pediatr Surg Int* 2012;28:673-6
- 7 Lockhat A, Kernaleguen G, Dicken BJ, et al. Factors associated with neonatal ostomy complications. *J Pediatr Surg* 2016;51:1135-7.
- 8 Karila K, Anttila A, Iber T, et al. Outcomes of surgery for necrotizing enterocolitis and spontaneous intestinal perforation in Finland during 1986-2014. *J Pediatr Surg* 2018;53:1928-32.
- 9 Zeigler MM. Meconium ileus. In: Coran AG, Adzick NS, Krummel TM, Laberge J, Shamberger RC, Caldamone AA. Editors. *Pediatric Surgery*. 7th edition. Philadelphia: Elsevier; 2012. P.1073-83.
- 10 Bishop HC, Koop CE. Management of meconium ileus; resection, Roux-en-Y anastomosis and ileostomy irrigation with pancreatic enzymes. *Ann Surg* 1957;145:410-4
- 11 Hasan MS, Mitul AR, Karim S, et al. Comparison of t tube ileostomy and bishop koop ileostomy for the management of uncomplicated meconium ileus. *J Neonatal Surg* 2017;6:56.
- 12 Zhang H, Zhong W, Sun J, et al. Application of Bishop-Koop stoma in refractory congenital intestinal atresia. *Zhonghua Wei Chang Wai Ke Za Zhi* 2016;19:1154-9.
- 13 Eltayeb AA. Different surgical techniques in management of small intestinal atresia in high risk neonates. *Ann Pediatr Surg*, 2009. 5(1): p. 31-5.
- 14 Sehgal S, Sandler AD, Alfred Chahine A, et al. Ostomy in continuity: A novel approach for the management of children with complex short bowel syndrome. *J Pediatr Surg* 2018;53:1989-95
- 15 Mentessidou A, Loukou I, Kampourglou G, et al. Long-term intestinal obstruction sequelae and growth in children with cystic fibrosis operated for meconium ileus: expectancies and surprises. *J Pediatr Surg* 2018;53:1504-8
- 16 Yeung F, Tam YH, Wong YS, et al. Early reoperations after primary repair of jejunoileal atresia in newborns. *J Neonat surgery* 2016;5:42
- 17 Burjonrappa S, Crete E, Bouchard S. Comparative outcomes in intestinal atresia: a clinical outcome and pathophysiology analysis. *Pediatr Surg Int* 2011;27:437-42
- 18 Martynov I, Raedecke J, Klima-Frysch J, Kluge W, Schoenberger J. The outcome of Bishop-Koop procedure compared to divided stoma in neonates with meconium ileus, congenital intestinal atresia and necrotizing enterocolitis. *Medicine (Baltimore)*. 2019 Jul;98(27):e16304.
- 19 Sathe M, Houwen R. Meconium ileus in Cystic Fibrosis. *J Cyst Fibros*. 2017. 16 Suppl 2: p. S32-s39.
- 20 Patil V, Vijayakumar A, Ajitha MB, Kumar LS. Comparison between Tube Ileostomy and Loop Ileostomy as a Diversion Procedure. *ISRN Surg*. 2012. 2012: p. 547523