

## Histology Altering Effect of Smoking in Rodents' Trachea

SHAKEELA NAZIR<sup>1</sup>, FATIMA QAISER<sup>2</sup>, ASHIQ HUSSAIN<sup>3</sup>, ASMA KAZI<sup>4</sup>, AISHA AZIZ<sup>5</sup>, RAFAQAT SHAFIQUE<sup>6</sup>

<sup>1,2</sup>Professor of anatomy Rashid Latif medical college Lahore

<sup>3</sup>Associate professor of Anatomy Sahiwal Medical College, Sahiwal

<sup>4</sup>Associate Professor Department Medicine Rashid Latif Medical College Lahore

<sup>5</sup>Assistant Professor Medicine Department Rashid Latif Medical College Lahore

<sup>6</sup>Post Graduate Trainee FCPS Neurology Punjab Institute of Neurosciences LGH Lahore

Correspondence to: Shakeela Nazir

### ABSTRACT

**Aim:** The purpose of this study was to investigate the effects of the cigarette smoke.

**Duration & Place of Study:** Jan 2018 to may 2021 Rashid Latif medical college Lahore

**Material and Method:** Two different groups of male albino rats were exposed to cigarette smoke using a specially developed smoking machine for duration of three months on a daily basis over the course of the experiment. Both populations of rats were made up entirely of albinos.

**Result:** Significant histological abnormalities occurred in the tracheal epithelium of albino rats that were exposed to cigarette smoke for a period of three months. The rats were given the smoke. The multiplication of epithelial cells, the disruption of the cilia, and the formation of inclusion bodies were some of the alterations that occurred as a result of this. In addition to alveoli that had collapsed and blood extravasations, a considerable thickening of the alveolar wall of the lung alveoli was seen.

**Conclusion:** These modifications show that nicotine may generate changes in tissue that are comparable to those induced by chronic irritation of tissue. This may result in a reduction in the efficiency of gaseous exchange in alveoli and may predispose to the development of neoplastic abnormalities.

### INTRODUCTION

Smoking refers to the act of taking in and releasing the vapors that are created by the combustion of plant materials, most notably tobacco. It is inhaled by the use of tobacco products such as cigarettes, cigars, chew, pipes, or water pipes. There are two types of smoke that result from the combustion of tobacco: main stream smoke and side stream smoke. Main stream smoke is the more common of the two types. When a person puffs on a tobacco product, they inhale a certain type of smoke that is referred to as the mainstream. This smoke originates from the product that contains the tobacco. The smoke that is produced by the burning of a cigarette in between puffs is known as the sidestream. It is not uncommon for the sidestream smoke to include larger concentrations of potentially harmful and cancer-causing substances than the mainstream smoke. There are almost 4,000 unique chemical components that can be identified in cigarette smoke, including sixty that are well-established to cause cancer. The gaseous components of mainstream smoke, which account for 92 percent of the total smoke, are comprised of somewhere between 400 and 500 different gases. Carbon monoxide, nitrogen oxide, hydrogen cyanide, formaldehyde, and ozone are some of the gases that fall into this category. In particle matter, which accounts for around 8% of mainstream smoke, tar compounds such as naphthalene, pyrene, and nitrosamine can be discovered. The inhalation of tobacco smoke is a major contributor to the development of a variety of illnesses that do not result in cancer that affect the respiratory system. These illnesses include asthma and chronic obstructive pulmonary disease (COPD), which is an acronym for chronic obstructive pulmonary disease. Children's respiratory health is another area that is negatively affected by secondhand smoke from cigarettes. Cigarette smoking causes a disruption in the immunological homeostasis of the lungs, which in turn lowers the body's resistance to respiratory infections. Research on the respiratory systems of albino rats in order to investigate the histological effects smoke has. They discussed the histological changes that occur in the trachea and the alveoli of the lungs as a result of smoke. These alterations may be traced back to the inhalation of nargile. The goal of this study is to evaluate the effect that smoking cigarettes has on specific tissues that are located within the respiratory system of an albino rat.

**Aims of the work:** The purpose of this study is to evaluate the potential histopathological changes that could take place as a result of long-term exposure of rats to smoke from commercial cigarettes. To do so, a specialized smoking device will be used in the course of the research. In the course of this work, numerous

tissues of the respiratory systems (such as the trachea and the alveoli of the lungs) have been analysed by light microscopy, with a specific focus on changes in the epithelium. This has been done with the intention of better understanding how these changes occur. To investigate, with the aid of light microscopy, the degree to which histopathological changes have reappeared three months after rats have not been subjected to the smoke from mainstream cigarettes.

### MATERIALS AND METHODS

**Experimental design:** Both groups contained sixty male Albino rats that were of the ranged in weight from 100 to 150 g on average. Both of the groups had an equal number of rats in their respective populations. In the first group, which acted as the test subject, cigarette smoke was inhaled, whereas in the second group, which was used as the control subject, smoke was not inhaled untreated. It was determined that exposing the participants to smoking would be an appropriate one dose every day, which is equivalent to one cigarette for each rat, for a total of ninety days. Following this, there will be a nonexposure phase that lasts for a total of three months to smoking as a means of rehabilitating themselves after being subjected to the adverse effects of cigarette smoking. Immediately after the completion of each period, the examination using a histological methodology was carried out. The control animals were placed in the chamber, where they were exposed to the oxygen rich air, and then subjected to the treatment rather than the smoke that comes from cigarettes.

**The digital smoking machine:** Exposure of animals to cigarette smoke has been done using an electronically controlled smoking machine

**The effects of cigarette smoke on histology of the respiratory systems Preparation of tissues for light microscopy:** Following the rats' complete night of rest following their final smoke inhalation, they were put under the influence of ether anesthesia before being put to death. After the tissues of interest (the trachea and the alveoli of the lung) had been carefully dissected out, they were cleaned completely with normal saline (0.9% NaCl), and then they were placed in 10% saline buffered formalin for at least 24 hours. It was necessary to use a volume of the formalin fixative that was 10–20 times more than the volume of the tissue pieces in order to ensure that the tissue pieces were properly fixed. After subjecting the tissues to a progression of progressively higher concentrations of alcohol, which was followed by two different iterations of xylene, they were finally rendered dehydrated. After being soaked in paraffin wax, the tissue was eventually encased in

paraffin wax in its purest form. Sections with a thickness of 5  $\mu$ m were cut using a microtome to produce the sections (Spencer 50). After the slices were finally mounted on glass slides, hematoxylin and eosin were applied to them in the capacity of stains. In order to analyse and photograph the sample sections, a photomicroscope and digital camera with 10.0 Megapixels were utilized.

## RESULTS

In tracheal tissue, control slices revealed typical ciliated pseudostratified columnar epithelium, mucosal, and fibroelastic layers (Fig. 1). The tracheal mucosa of the group that was exposed to cigarette smoke was negatively impacted, as evidenced by the presence of epithelial cellular hyperplasia with ciliary amalgamation, inclusion bodies, and inflammatory cell infiltration (Fig. 2). After the period allotted for recuperation, the tissue displayed some signs of improvement (Fig. 3). Impact on the air sacs within the lungs (alveoli) Photomicrographs of lung alveoli taken from control animals showed that the typical simple epithelium and terminal bronchiole structures were in place and appeared normal. Clearly visible thickening in the alveolar wall tissue, collapsed alveoli, inflammatory cell infiltration, and blood extravasations were observed in the lungs of rats that had been exposed to cigarette smoke. Following the resting time, there was a discernible drop in the exceptionally high number of cells that were replicating themselves.

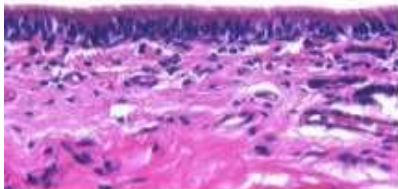


Fig 1: normal tracheal tissue. ciliated pseudostratified columnar epithelium, cilia, basement membrane, basal cell

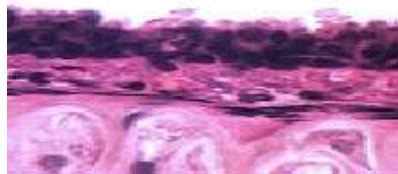

Fig 2: Trachea of cigarette smoke-exposed rat, showing an epithelial cellular hyperplasia and inflammatory cell infiltration

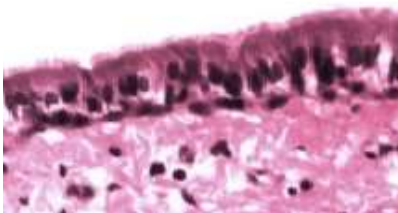


Fig 3: Tracheal mucosa of cigarette smoke exposed rat after the recovery period



Fig 4: Control lung alveoli

## DISCUSSION

In the current investigation, it was determined that cell degeneration was the cause of mucosa disruption, which was frequently detected within the tracheal epithelium. In addition, ciliary amalgamation, which might be considered a component of epithelial disruption, might develop as a consequence of the hyperplasia of mucus-secreting submucosal glands and influence the systems that are responsible for airway clearing. There was evidence of inclusion bodies, which can be described as any small amorphous blackish aggregate of smoke toxicants, predominantly tar components. It is possible that the high quantity of nicotine is to blame for the observed loss of cilia. Nicotine is known to have damaging effects on microtubules and to disrupt the polymerization and depolymerization of these structures. It was hypothesised that acetaldehyde and acrolein contributed to the damage that was done to the cilia. Acetaldehyde was able to suppress the activity of ciliary dynein ATPase and bind to ciliary proteins, both of which are essential to the proper operation of ciliary dynein and tubulin. As a result, ciliary function and beat frequency were both impaired. In cultivated bovine bronchial epithelial cells, it was shown that acrolein causes cilia to behave in an abnormal manner by lowering the frequency of their beats. The effects of cigarette smoke on the trachea tissue of Wistar rats revealed a number of morphological alterations in the epithelium. These changes included desquamation, the loss of cilia, and an increase in goblet cells. In addition to this, there was an activation of serous glands in the submucosa, as well as cell infiltration. These morphological changes were found to have a correlation with the quantity of harmful chemicals that were present in cigarette smoke. During chronic inflammation, the infiltration of inflammatory cells contributes to an acceleration of tissue destruction. This can occur either by the secretion of lytic enzymes or an increased production of oxygen free radicals. In a study conducted in by Gaafar and Al-Mansour, the tracheal mucosa of the rabbit was subjected to the effects of entire cigarette smoke. The epithelium was found to have oedema and disordered stratification, the cilia were found to be in low numbers, and the tunica propria included a large number of vacuoles and amorphous entities. These findings were discovered. In an experimental setting using rats, Mikaili investigated the effects of cigarette smoke on the epithelium and submucosal cells that were injured as a result of exposure to the smoke. Tobacco smoking was found to be the cause of a considerable rise in the incidence of metaplasia.

In the current investigation, the lung alveoli of rats that had been exposed to cigarette smoke exhibited clear signs of thickening in the wall tissue of the alveoli, collapsed alveoli, inflammatory cell infiltration, and blood extravasations. The lung tissue that was impacted had characteristics of hyperplasia of the alveolar cells. In a variety of experimental and clinical conditions, such as pulmonary edema, hyperplasia of the alveolar epithelium has been described.

## CONCLUSION

The act of smoking causes histological alterations in the respiratory airways and the aorta. These changes have an impact on the gaseous exchange and may predispose a person to changes that could lead to cancer. To undo all of these alterations, it is essential to give up cigarette smoking and end one's exposure to secondhand smoke.

## REFERENCES

- Mishra A, Chaturvedi P, Datta S, Sinukumar S, Joshi P, Garg A. Harmful effects of nicotine. *Indian J Med Paediatr Oncol.* 2015;36:24–31. doi: 10.4103/0971-5851.151771. [PMC free article] [PubMed] [CrossRef] [Google Scholar]
- Ratajczak A, Feleszko W, Smith DM, Goniewicz M. How close are we to definitively identifying the respiratory health effects of e-cigarettes? *Expert Rev Respir Med.* 2018;12:549–556. doi: 10.1080/17476348.2018.1483724. [PMC free article] [PubMed] [CrossRef] [Google Scholar]

- 3 Al-Obaidi S, Mathew TC, Dean E. Exercise may offset nicotine-induced injury in lung tissue: A preliminary histological study based on a rat model. *Exp Lung Res.* 2012;38:211–221. doi: 10.3109/01902148.2012.666331. [PubMed] [CrossRef] [Google Scholar]
- 4 Avino P, Scungio M, Stabile L, Cortellessa G, Buonanno G, Manigrasso M. Second-hand aerosol from tobacco and electronic cigarettes: Evaluation of the smoker emission rates and doses and lung cancer risk of passive smokers and vapers. *Sci Total Environ.* 2018;642:137–147. doi: 10.1016/j.scitotenv.2018.06.059. [PubMed] [CrossRef] [Google Scholar]
- 5 Vicary GW, Ritzenthaler JD, Panchabhai TS, Torres-González E, Roman J. Nicotine stimulates collagen type I expression in lung via  $\alpha 7$  nicotinic acetylcholine receptors. *Respir Res.* 2017;18(115) doi: 10.1186/s12931-017-0596-8. [PMC free article] [PubMed] [CrossRef] [Google Scholar]
- 6 Benowitz NL, Hukkanen J, Jacob P III. Nicotine chemistry, metabolism, kinetics and biomarkers. *Handb Exp Pharmacol.* 2009;192:29–60. doi: 10.1007/978-3-540-69248-5\_2. [PMC free article] [PubMed] [CrossRef] [Google Scholar]
- 7 Lerner CA, Sundar IK, Yao H, Gerloff J, Ossip DJ, McIntosh S, Robinson R, Rahman I. Vapours produced by electronic cigarettes and e-juices with flavourings induce toxicity, oxidative stress, and inflammatory response in lung epithelial cells and in mouse lung. *PLoS One.* 2015;10(e0116732) doi: 10.1371/journal.pone.0116732. [PMC free article] [PubMed] [CrossRef] [Google Scholar]
- 8 Wu Q, Jiang D, Minor M, Chu HW. Electronic cigarette liquid increases inflammation and virus infection in primary human airway epithelial cells. *PLoS One.* 2014;9(e108342) doi: 10.1371/journal.pone.0108342. [PMC free article] [PubMed] [CrossRef] [Google Scholar]
- 9 Yong HH, Hitchman SC, Cummings KM, Borland R, Gravely SM, McNeill A, Fong GT. Does the regulatory environment for E-cigarettes influence the effectiveness of E-cigarettes for smoking cessation?: Longitudinal findings from the ITC four country survey. *Nicotine Tob Res.* 2017;19:1268–1276. doi: 10.1093/ntr/ntx056. [PMC free article] [PubMed] [CrossRef] [Google Scholar]
- 10 Mohamed MH, Rahman A, Jamsheer S, Mahmood S. Effectiveness and safety of electronic cigarettes among sole and dual user vapers in Kuantan and Pekan, Malaysia: A six-month observational study. *BMC Public Health.* 2018;18(1028) doi: 10.1186/s12889-018-5951-2. [PMC free article] [PubMed] [CrossRef] [Google Scholar]
- 11 McRobbie H, Bullen C, Hartmann-Boyce J, Hajek P. Electronic cigarettes for smoking cessation and reduction. *Cochrane Database Syst Rev:* Dec 17, 2014 (Epub ahead of print). doi: 10.1002/14651858.CD010216.pub2. [PubMed] [Google Scholar]
- 12 Hartmann-Boyce J, Chepkin SC, Ye W, Bullen C, Lancaster T. Nicotine replacement therapy versus control for smoking cessation. *Cochrane Database Syst Rev.* 2018;5(CD000146) doi: 10.1002/14651858.CD000146.pub5. [PMC free article] [PubMed] [CrossRef] [Google Scholar]
- 13 Wagener TL, Floyd EL, Stepanov I, Driskill LM, Frank SG, Meier E, Leavens EL, Tackett AP, Molina N, Queimado L. Have combustible cigarettes met their match? The nicotine delivery profiles and harmful constituent exposures of second-generation and third-generation electronic cigarette users. *Tob Control.* 2017;26:e23–e28. doi: 10.1136/tobaccocontrol-2016-053041. [PMC free article] [PubMed] [CrossRef] [Google Scholar]
- 14 Verhaegen A, Van Gaal L. Do E-cigarettes induce weight changes and increase cardiometabolic risk? A signal for the future. *Obes Rev.* 2017;18:1136–1146. doi: 10.1111/obr.12568. [PubMed] [CrossRef] [Google Scholar]
- 15 Camenga DR, Kong G, Cavallo DA, Krishnan-Sarin S. Current and former Smokers' use of electronic cigarettes for quitting smoking: An exploratory study of adolescents and young adults. *Nicotine Tob Res.* 2017;19:1531–1535. doi: 10.1093/ntr/ntw248.