

# Determination of Female Gender by Value of Maxillary Sinus Morphology using Digital Radiography

YUNAS KHAN<sup>1</sup>, SADIA SYED<sup>2</sup>, SADIA RAFIQ<sup>3</sup>, MOHAMMAD ASIF SHAHAB<sup>4</sup>, MUNEEBA MUGHAL<sup>5</sup>, SIRAJ AHMAD<sup>6</sup>

<sup>1</sup>Assistant Professor, Department of Forensic Medicine Muhammad College of Medicine, Peshawar

<sup>2</sup>Assistant Professor, Department of Forensic Medicine and Toxicology, Shifa college of Medicine, Shifa Tameer-e-Millat University, Islamabad

<sup>3</sup>PG Scholar, Department of Forensic Medicine, Peshawar Medical College, Peshawar

<sup>4</sup>Assistant Professor, Department of Forensic Medicine, Al-Nafees Medical College, Islamabad

<sup>5</sup>Junior Clinical Fellow, Orthopaedic Department, Luton & Dunstable Hospital, United Kingdom

<sup>6</sup>MBBS 2<sup>nd</sup> Year Student, Agha Khan University, Karachi

Correspondence: Dr. Sadia Syed, E-mail: [sadia\\_syed.scm@stmu.edu.pk](mailto:sadia_syed.scm@stmu.edu.pk) Cell: 0320-5429435

## ABSTRACT

**Aim:** To determine gender through digital radiography from the height and width of maxillary sinus.

**Study Design:** Descriptive study.

**Place and duration of study:** Kuwait Teaching Hospital and Khyber Teaching Hospital Peshawar from 1st January 2020 to 30th June 2020.

**Methodology:** AP view of radiographs of 64 female participants was used and analysis of morphological parameters of maxillary sinus was done by using microdicom software.

**Results:** The mean height and width of right maxillary sinus was 22.39mm and 22.54mm respectively while the mean height and width of left maxillary sinus was 22.39mm and 20.81mm respectively and was found to be statistically highly significant.

**Conclusion:** Determination of female gender can be done with the help of anteroposterior view of digital radiographs from the height and breadth of maxillary sinuses.

**Key words:** Gender determination, Forensic radiography, Female, Sexual dimorphism, Maxillary sinus

## INTRODUCTION

Whenever there is a catastrophe, radiology plays a pivotal role to determine gender that ultimately helps in identification of human bodies that are decomposed, charred or mutilated.<sup>1</sup> Bone sexing is an effective tool since the male and female bones show significant differences in terms of shape and size of anatomical structures. Pelvis is the first while skull is the second best region for sex determination.<sup>2</sup> Stature and gender determination in both the living and dead constitutes the basis of identification of human body.<sup>3</sup>

The paranasal sinuses develop as the out pouching of nasal epithelium into the bones outlining the nasal cavity during the 3<sup>rd</sup>-4<sup>th</sup> month of intrauterine life and opens up in the middle nasal meatus.<sup>4</sup> In cases of incineration, the identification process becomes much more difficult and while the bones becomes deformed, maxillary sinuses still remain intact and could be used as a measure to identify the corpse.<sup>5</sup> In previous studies it has been found that in male population the maxillary sinuses are considerably larger in dimensions than in females that forms an important basis for gender identification.<sup>6</sup>

Since CT scans and MRI are the preferred techniques but in the developing country like Pakistan, digital radiography is a cost effective method to be used to serve the same purpose.<sup>7</sup>

## MATERIALS AND METHODS

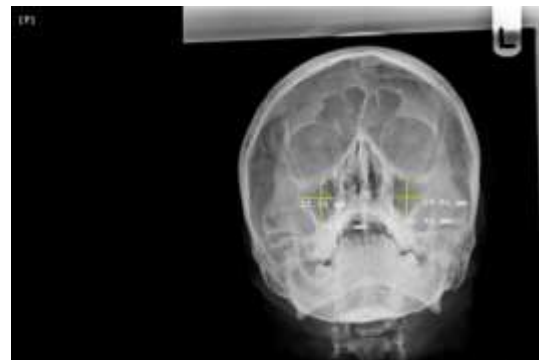This study included x-rays of 64 female participants who visited Khyber Teaching Hospital and Kuwait teaching hospital, Peshawar in ENT department and were advised radiography with anteroposterior view of maxillary sinus. The cases that were included were those with age from 25 to 40 years, with all permanent teeth erupted and those that had X-ray scans with clear image of maxillary sinuses and adequate contrast and density. Those radiographs were excluded that had errors or unclear images, artifacts and those with any pathology or deformed maxillary sinus. After obtaining official permission from Ethical Review Board of Kuwait teaching hospital and Khyber teaching hospital Peshawar, verbal informed consent was taken from the patients who have been visiting the said hospitals for their treatment, and who have done their digital radiography (AP view showing maxillary sinus) for their E.N.T related problems. The

Received on 05-04-2022

Accepted on 15-08-2022

height and width of all the radiographs were measured using microdicom, an image processing programmer. The X-Ray sample with details showing left and right maxillary sinuses was fed into the microdicom and height and breadth of sinus was measured in the mid-line along y-axis and x-axis of radiographs under the supervision of radiologist.

Measurements of dimensions obtained from radiographs were fed in excel spreadsheet and SPSS Version 20 software is used. To analyze differences between males and females gender, T student test is used.



X-Ray Scan showing measurement of maxillary sinuses (height and breadth) in millimeters in females

## RESULTS

The mean height of right maxillary sinus in females was 22.39mm with a p value of 0.001 whereas the mean width of right maxillary sinus was 22.54mm with a p value of 0.002. The mean height of left maxillary sinus in females was 22.78mm with a p value of 0.001 whereas the mean width of left maxillary sinus was 20.81mm with a p value of 0.001 (Tables 1-2, Fig. 1).

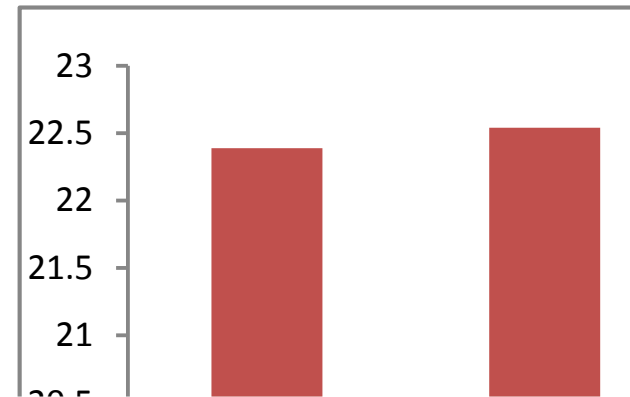
Table 1: Height and width of maxillary sinus (n=64)

Variable	Mean±SD
Age (years)	31.91±4.68
Height right maxillary sinus (mm)	22.39±2.58
Width right maxillary sinus (mm)	22.54±4.18
Height left maxillary sinus (mm)	22.78±4.32
Width left Maxillary sinus (mm)	20.81±3.47

Table 2: Value of Maxillary sinus height and width (n=64)

Variable	Mean±SD	P value
Height right maxillary sinus (mm)	22.39±2.58	0.001
Width right maxillary sinus (mm)	22.54±4.18	0.002
Height left maxillary sinus (mm)	22.78±4.32	0.001
Width left Maxillary sinus (mm)	20.81±3.47	0.001

Fig. 1: Differences in measurements of height and width of maxillary sinus



## DISCUSSION

In mass disasters, stature estimation and gender determination becomes the first step to identify the mutilated, disfigured and incinerated dead bodies.<sup>7,8</sup> A study done among Kirdashian population showed accuracy rate of 71% among the female population to estimate gender. They also found out that maxillary sinus could serve as an important source to determine race and gender<sup>9</sup>.

The results of our study showed that the dimensions of maxillary sinuses in females are less in height and measures 22.39mm and 22.78mm on right and left sides respectively. A study done in Gwalior region using 41 CT scan images of female patients showed a mean height of 24.33 and 24.93mm on right and left sides respectively, that is quite similar to the results of our study.<sup>9</sup> Variations in the maxillary sinus height, width and volume have been reported in different cultures. A study done in Aachen University reported that variation in dentition influences the value of volume and surface of maxillary sinus and the gender determination could be analyzed with increase in pneumatization of maxillary sinus<sup>10</sup>.

A study conducted in Turkey reported significant difference in male and female maxillary sinus while considering various parameters including anteroposterior diameter, transverse diameter and volume of the sinus. The accuracy rate for the female gender was found to be 80%<sup>11</sup>.

A study done in Poland compared the CT scans and found out no sexual dimorphism among the population from birth to 18 years old, though the dimensions and the volume tend to be greater in the males than in females<sup>12</sup>.

In the present study, 128 were used to measure the height and width of maxillary sinuses of 64 female radiographs. The p values for right maxillary height and width are 0.001 and 0.002 respectively and are highly significant statistically. The p values for left maxillary sinuses height and width are 0.001 and 0.001 respectively and again both are highly significant statistically.

In a study, 420 CBCT Scans were done among a Brazilian population ranging in age from 18 years to 40 years and above. It was found out that evident morphological changes occur with the progressive age and females have contrasting difference in morphology and volume as compared to male population. The best discriminating factor was height of maxillary sinus that was lesser in value in females than in males.<sup>13</sup> CBCT has been frequently used to screen the disease and pathological processes.<sup>14</sup>

A study conducted in Iran found out a contrasting difference between height and length of maxillary sinuses though it was

reported that sexual dimorphism does not exist while comparing width of maxillary sinuses<sup>15</sup>.

A study done in Turkey, collected 127 CT Scans and found out 69 percent accuracy to determine gender on basis of height, length and width of maxillary sinus<sup>16</sup>.

In Indonesia, 138 CBCT radiographic images were examined to visualize maxillary sinus size and mandibular canal position in male and female subjects. It was found out that sex determination can be done from height, length, and breadth of the maxillary sinus, as well as the distance from the mandibular canal to the inferior border of the mandible.<sup>17</sup> Maxillary sinus plays an important role to determine gender when other methods of identification are not applicable<sup>18</sup>.

## CONCLUSION

Determination of gender is possible from the height and breadth of maxillary sinuses through anteroposterior view of digital radiographs.

**Conflict of interest:** Nil

## REFERENCES

- Sathawane SR, Sukhadeve AV, Chandak MR, Lanjekar AB, Moon GV. Sex determination by maxillary sinus dimensions using cone-beam computed tomography and discriminate function: an analytical study. *Int J Forensic Odontol* 2020;5(1):19.
- Ramaswamy P, Khaitan T. Frontal sinus index: a new tool for sex determination. *J Forensic Radiol Imaging* 2014;2(2):77-9.
- Sheikh NN, Ashwinirani SR, Suragimath G, Kumar KS. Evaluation of gender based on the size of maxillary sinus and frontal sinus using paranasal sinus view radiographs in Maharashtra population, India. *J Oral Res Review* 2018;10(2):57.
- Wanzeler AM, Alves-Júnior SM, Ayres L, da Costa Prestes MC, Gomes JT, Tuji FM. Sex estimation using paranasal sinus discriminant analysis: a new approach via cone beam computerized tomography volume analysis. *Int J Legal Med* 2019;133(6):1977-84.
- Prabhat M, Rai S, Kaur M, Prabhat K, Bhatnagar P, Panjwani S. Computed tomography based forensic gender determination by measuring the size and volume of the maxillary sinuses. *J Forensic Dent Sci* 2016;8(1):40.
- Bangi BB, Ginjupally U, Nadendla LK, Vadla B. 3D evaluation of maxillary sinus using computed tomography: a sexual dimorphic study. *Int J Dent* 2017;4: 2017.
- Urooge A, Patil BA. Sexual dimorphism of maxillary sinus: a morphometric analysis using cone beam computed tomography. *JCDR* 2017; 11(3):ZC67.
- Ahmed AG, Gataa IS, Fateh SM, Mohammed GN. CT scan images analysis of maxillary sinus dimensions as a forensic tool for sexual and racial detection in a sample of Kurdish population. *Eur Sci J* 2015;11(18).
- Sharma SK, Jehan M, Kumar A. Measurements of maxillary sinus volume and dimensions by computed tomography scan for gender determination. *J Anatomical Soc India* 2014; 63(1):36-42.
- Möhlhenrich SC, Heussen N, Peters F, Steiner T, Hölzle F, Modabber A. Is the maxillary sinus really suitable in sex determination? A three-dimensional analysis of maxillary sinus volume and surface depending on sex and dentition. *J Craniofac Surg* 2015;26(8):e723-6.
- Ekizoglu O, Inci E, Hocaoglu E, Sayin I, Kayhan FT, Can IO. The use of maxillary sinus dimensions in gender determination: a thin-slice multidetector computed tomography assisted morphometric study. *J Craniofac Surg* 2014;25(3):957-60.
- Lorkiewicz-Muszyńska D, Kociemba W, Rewekant A, Sroka A, Jończyk-Potoczna K, Patelska-Banaszewska M, Przysańska A. Development of the maxillary sinus from birth to age 18. Postnatal growth pattern. *Int J Pediatr Otorhinolaryngol* 2015;79(9):1393-400.
- Teixeira LC, Walewski LÂ, de Souza Tolentino E, Iwaki LC, Silva MC. Three-dimensional analysis of the maxillary sinus for determining sex and age in human identification. *Forensic Imaging* 2020;22:200395.
- Vogiatzi T, Kloukos D, Scarfe WC, Bornstein MM. Incidence of anatomical variations and disease of the maxillary sinuses as identified by cone beam computed tomography: a systematic review. *Int J Oral Maxillofac Implants* 2014;29(6):1301-4.
- Paknahad M, Shahidi S, Zarei Z. Sexual dimorphism of maxillary sinus dimensions using cone-beam computed tomography. *J Forensic Sci* 2017;62(2):395-8.
- Teke HY, Duran S, Canturk N, Canturk G. Determination of gender by measuring the size of the maxillary sinuses in computerized tomography scans. *Surg Radiol Anatomy* 2007;29(1):9-13.
- Waluyo RF, Priaminiarti M, Yuniastuti M, Soedarsono N, Susilo BT. Measurements of sex-related differences in maxillary sinus and mandibular canal characteristic using cone beam computed tomography. *Forensic Imaging* 2020;21:200371.
- Uthman AT, Al-Rawi NH, Al-Naaimi AS, Al-Timimi JF. Evaluation of maxillary sinus dimensions in gender determination using helical CT scanning. *J Forensic Sci* 2011; 56(2):403-8.