

Early Lateral Internal Sphincterotomy Versus Conservative Treatment; Our Experience in Treatment of Chronic Anal Fissure in Qazi Hussain Ahmed Medical Complex Nowshera Pakistan

FAZAL GHANI¹, KAMRAN HAKEEM KHAN², KAMRAN AHMED³, MUDASSAR SHAHZAD⁴, SHAHID KHAN⁵, WASEEM YAR KHAN⁶

¹Associate Professor General Surgery Qazi Hussain Ahmed Medical Complex/Nowshera Medical College

²Assistant Professor General Surgery Qazi Hussain Ahmed Medical Complex/Nowshera Medical College

³Associate Professor General Surgery Qazi Hussain Ahmed Medical Complex/Nowshera Medical College

⁴Assistant Professor General Surgery Qazi Hussain Ahmed Medical Complex/Nowshera Medical College

⁵Assistant professor General Surgery Qazi Hussain Ahmed Medical Complex/Nowshera Medical College

⁶Professor General Surgery Qazi Hussain Ahmed Medical Complex/Nowshera Medical College

Corresponding author: Kamran Hakeem Khan, Email: kamranhakeemkhan@gmail.com

ABSTRACT

Background: A chronic anal fissure is a longitudinal tear in the anorectal area beneath the dentate line contributing to chronic pain and emotional stress during defecation. The present study aimed to assess early surgery versus conservative treatment for managing chronic anal fissures.

Methodology: This randomized control trial was carried out on 150 chronic anal fissures patients at the Department of General Surgery, Qazi Hussain Ahmed Medical Complex, Nowshera, Pakistan from March 2020 to September 2021. Patients were divided into two groups; Group-I comprised of patients who were treated conservatively and Group II consisted of patients who underwent surgical intervention. Patients above 15 years of age and fit for surgery were enrolled. A Chi-square test was used for correlating the results using SPSS version 24.

Results: Of the total patients, there were 132 (88%) male and 18 (12%) female patients. The overall mean age of Group-I and Group-II was 38.7± 6.5 years and 39.6±3.67 years. The prevalence of posterior and anterior located fissures were 136 (90.7%) and 14 (9.3%) respectively. About 86 patients underwent closed LIS, out of which 77 were male and 9 were female. The patient's main complaints were anal pain followed by bleeding. The response rate to pain relief treatments was 79% in group-I, I, and I and 97% in group II.

Conclusion: Our study found that lateral internal sphincterotomy remains the gold standard for the treatment of chronic anal fissures. To avoid recurrence and obtain the best pain relief, LIS remains the gold standard for the treatment of chronic anal fissures.

Keywords: Chronic anal fissure, Conservative treatment, surgical intervention.

INTRODUCTION

Anal fissure affects the lower anal canal. It's a longitudinal ulcer in the anoderm that occurs most often in the posterior midline, less often in the anterior, and rarely in the lateral (1, 2). The fissure looks triangular with the tip at the dentate line and the base across the lower anal canal (3, 4). It's one of the most prevalent benign anorectal disorders, and the discomfort and stress it produces may reduce people's quality of life (5). Unknown. The hard stool is considered to increase sphincter pressure (even at rest) (6). Anal fissures are acute (typically gone in a week) or chronic (lasting more than six weeks), with a hypertrophic papilla, sentinel tubercle, and exposed sphincter muscle fibers on the wound floor (7).

Chronic anal fissures heal after 12 weeks and are accompanied by a hypertrophied papilla, sentinel tubercle, and exposed sphincter muscle fibers (8). Physical or chemical pressure-reduction is used to treat anal fissures. Chronic anal fissures are treated surgically. Chronic anal fissures have no standard therapy (9). As the first therapy, the ASCRS suggests stool softeners, a high-fiber diet, and a warm sitz bath (10). This conservative approach doesn't work for many people. Medical therapy has a high recurrence rate. LIS is the gold standard surgical therapy for persistent anal fissures when medicinal and conservative therapies fail (11). Primary chronic anal fissures are a matter of debate among new surgeons and those in rural facilities with limited resources. Simple and effective, Nearly all U.S. hospitals execute four fingers AD and closed LAS. This research aimed to compare the two methods.

METHODOLOGY

This randomized control trial was carried out on 150 chronic anal fissures patients at the Department of General Surgery, Qazi Hussain Ahmed Medical Complex, Nowshera, KPK, Pakistan from March 2020 to September 2021. Patients were divided into two main groups; Group-I comprised of patients who were treated conservatively and Group II consisted of patients who underwent surgical intervention for chronic anal fissures. All the chronic anal

fissures patients above 15 years of age and who were fit for surgery were enrolled. The medical treatment consisted of 8 weeks of topical ointment application (0.2 percent nitroglycerin or 2 percent diltiazem applied every 12 hours) followed by a warm sitz bath. A bivalve anal retractor was inserted into the anal canal to perform a closed lateral anal sphincterotomy. It was opened to stretch the internal sphincter and expose the anal canal's lateral walls. Patients were admitted a day before surgery after providing proper consent. Routine tests such as blood CP, urine RE, and CXR were performed. A general/spinal anesthesia assessment was performed. The procedures were performed under general/spinal anesthesia. The patients were placed in the lithotomy position on the operating table. Before each surgical procedure, the clinical inspection, digital rectal examination, and proctoscopy were repeated.

Inclusion and Exclusion Criteria: All patients over 15 with main chronic anal fissures were included. Symptoms included defecation discomfort, P/R bleeding, and constipation. Sentinel pile, anal papilla, ulcer base fibrosis, and ulcer border indurations were symptoms. All patients under 15, with secondary fissures, fissures lasting less than 6 weeks with no organic changes, and those deemed unfit for general or spinal anesthesia or surgery due to co-morbid factors were excluded from the study.

Statistical Analysis: The Chi-square test was used to compare two discrete variables. When predicted sources were less than 20%, Monte Carlo Simulation Method values were used. Data analysis utilized SPSS 24. The significance threshold was P=0.001.

RESULTS

132 (88%) male and 18 (12%) female patients were treated. Group-I and Group-II mean ages were 38.76.5 and 39.63.67. 136 posterior and 14 anterior fissures were present. 77 men and 9 women had closed lateral anal sphincterotomy. Anal discomfort and bleeding were significant complaints. Group-I responded to pain treatments at 79% and group II at 97%. Figure 1 shows

gender distribution. Figure 2 shows posterior and anterior fissures. Table-I shows participant clinical profiles. Table II shows pain alleviation at weeks 1, 2, 4, and 8. Complications and other side effects are shown in Table III.

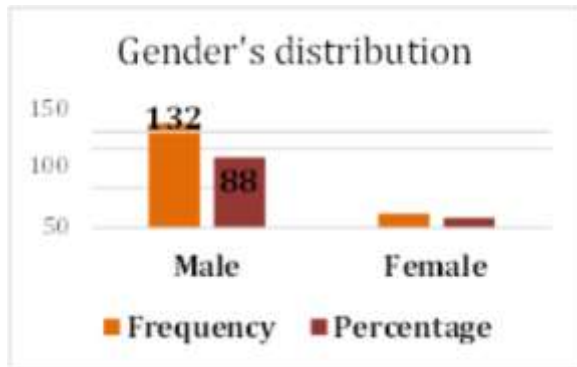


Figure-1: Gender distribution

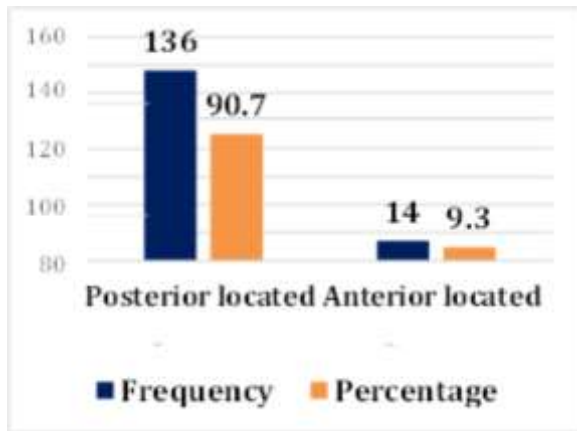


Figure-2: Prevalence of posterior and anterior located fissure

Table-1: Clinical profile of the participants.

Clinical Features	Group-I N=75	Group-II N=75	P-value
Gender	70 (46.7)	61 (40.7)	0.941
Male n (%) Female n (%)	5 (3.3)	14 (9.3)	
Age (Mean ± SD) years	38.7± 6.5	39.6±3.67	0.832
Complaints			
Pain n (%)	70 (46.7)	66 (44)	0.823
Bleeding n (%)	34 (22.7)	52 (34.7)	<0.001
Itching n (%)	14 (9.3)	18 (12.)	<0.001
Constipation n (%)	16 (10.7)	30 (20)	0.472
Perianal discharge n (%)	4 (2.7)	5(3.3)	0.447

Table-2: Pain relief during first, second, fourth, and eighth weeks

Duration (Weeks)	Group-I N=75	Group-II N=75	P-value
First (%)	68 (45.3)	34 (22.7)	<0.001
Second (%)	48 (32)	41 (27.3)	<0.001
Fourth (%)	52 (34.7)	45 (30)	<0.001
Eighth (%)	57 (38)	52 (34.7)	<0.001

Table-3: Complications and other side effects

Complications	Group-I N=75	Group-II N=75
Headache	64 (42.7)	
Nausea	20 (13.3)	
Arrhythmia	18 (12)	
Gas incontinence (Transient)		5 (3.3)
Fluid incontinence		2 (1.3)
Perianal abscess		5 (3.3)

DISCUSSION

Anal canal fissure is frequent (12, 13). Chronicity may be caused

by delay in treatment during the chronic stage of the illness owing to patient ignorance, lack of sufficient medical facilities, poverty, or shyness in discussing the ailment with a doctor. In the chronic stage of the illness, conservative and non-surgical treatments failed (14). Most patients stop conservative treatment when their symptoms resolve, there is a recurrence, or they have adverse effects including headaches and lightheadedness with GTN ointment (15, 16).

This study's results are similar to others worldwide. Closed LIS patients had no discomfort, bleeding, or incontinence after 4 weeks. Each patient's fissure was entirely repaired, with no recurrence. 42.85% of four fingers AD patients experienced incontinence, 14.2% had ulcer persistence, and 4.76% had a recurrence. Chronic anal fissure therapy has changed dramatically in the recent decade (17). Medical therapy is the first choice since it is non-invasive and doesn't harm the anal sphincter (18, 19). The gold standard for anal fissure therapy is sphincterotomy (20). In our research, pain response to drugs (GTN and diltiazem) was comparable to earlier studies (21, 22).

Gagliardi et al. employed 6 weeks of medicinal therapy, but our outcomes were better (23). Completing the therapy course might explain it (P0.05). Surgical and medical groups had different pain responses (P0.05). Due to its safety and in patients who do not agree to surgery, medicinal therapy for pain response may be utilized as the first step in patients' treatment (I=79%, II=97%). These results are consistent with others (24). Medical group fissure healing was slower than surgical.

Our investigation identified similar side effects to prior studies (25, 26). Topical diltiazem caused no side effects. In group I, 3 patients discontinued their medication due to a headache. Newman et al. observed 23% similar GTN side effects. (27) In 3% of group II during the first week of the research, gas and liquid incontinence disappeared without intervention after 4 weeks. It echoed Alvandipour et al (28).

CONCLUSION

According to the results of our study, lateral internal sphincterotomy is still the most effective method for treating chronic anal fissures. Patients who did not have surgery rated surgical therapy as more successful and preferred treatments. In order to prevent recurrence and provide the most effective pain relief, LIS is still the therapy of choice for chronic anal fissures.

Acknowledgements: We appreciated everyone's help. Dr. Iqtidar Ud Din, Medical Director Qazi Hussain Ahmed Medical Complex, Nowshera, was instrumental in the project's success. Families' and friends' support and inspiration are also appreciated.

REFERENCES

1. Stewart DB Sr, Gaertner W, Glasgow S, Migaly J, Feingold D, Steele SR (2017) clinical practice guideline for the management of anal fissures. *Dis Colon Rectum* 60(1):7-14
2. Bhamra AR, Melnitchouk N, Mizell JS, Sherman KL, Zaghiyan K (2020) Evaluation of practice patterns of chemodeneration for anal fissure of the ASCRS young surgeons. *Tech Coloproctol* 24(6):611-612
3. Brady JT, Althans AR, Neupane R, Dosokey EMG, Jabir MA, Reynolds HL, et al. Treatment for anal fissure: Is there a safe option? *Am J Surg* 2017;214:623-8.
4. Andjelkov K, Sforza M, Barisic G, Soldatovic I, Hiranyakas A, Krivokapic Z. Novel method for treatment of chronic anal fissure: Adipose-derived regenerative cells – A pilot study. *Colorectal Dis* 2017;19:570-5.
5. Shrestha SK, Thapa PB, Maharjan DK, Tamang TY. Effectiveness of 0.2% glyceryl trinitrate and 0.5% nifedipine in the treatment of chronic anal fissure. *J Nepal Med Assoc* 2017;56:149-52.
6. Khan MS, Akbar I, Zeb J, Ahmad S, Khan A. Outcome of 0.2% Glyceryl trinitrate cream versus 2% diltiazem cream in the treatment of chronic anal fissure. *J Ayub Med Coll Abbottabad* 2017;29:280-4.
7. Salari M, Salari R, Dadgarmoghadam M, Rezaian MK, Hosseini M. Efficacy of egg yolk and nitroglycerin ointment as treatments for chronic anal fissures: A randomized clinical trial study. *Electron Physician* 2016;8:3035-41.

8. Gaj F, Biviano I, Candeloro L, Andreuccetti J. Anal self-massage in the treatment of chronic anal fissure: A randomized prospective study. *Ann Gastroenterol* 2017;30:438–41.
9. Salih AM. Chronic anal fissures: Open lateral internal sphincterotomy result; a case series study. *Ann Med Surg* 2017;15:56–8.
10. Barbeiro S, Atalaia Martins C, Marcos P, Gonçalves C, Canhoto M, Arroja B, et al. Long term outcomes of Botulinum toxin in the treatment of chronic anal fissure: 5 years of follow up. *United European Gastroenterol J* 2017;5:293–7.
11. Motie MR, Hashemi P. Chronic anal fissure: A comparative study of medical treatment versus surgical sphincterotomy. *Acta Med Iran* 2016;54:437–40.
12. Near G, Topbas M. Lateral internal partial sphincterotomy technique for chronic anal fissure. *Indian J Surg* 2017;79:185–7.
13. Sahebally SM, Walsh SR, Mahmood W, Aherne TM, Joyce MR, Sahebally SM, et al (2018) Anal advancement flap versus lateral internal sphincterotomy for chronic anal fissure- a systematic review and meta-analysis. *Int J Surg* 49:16–21
14. Nelson RL, Manuel D, Gumienny C, et al (2017) A systematic review and meta-analysis of the treatment of anal fissure. *Tech Coloproctol* 21(8):605–625
15. Ebinger SM, Hardt J, Warschkow R, et al (2017) Operative and medical treatment of chronic anal fissures-a review and network meta-analysis of randomized controlled trials. *J Gastroenterol* 52(6):663–676
16. Zeitoun J-D, Blanchard P, Fathallah N, et al (2018) Long-term outcome of a fistulectomy: a prospective single-arm study of 50 operations out of 349 initial patients. *Ann Coloproctol* 34(2):83–87
17. Sobrado Júnior CW, Hora JAB, Sobrado LF et al (2019) Anoplastia com plicoma sentinela para o tratamento de fissura anal crônica. *Rev Col Bras Cir* 46(3):e20192181
18. Hancke E, Suchan K, Völke K (2020) Anocutaneous advancement flap for sphincter-sparing surgical treatment of chronic anal fissures. Analysis of consecutive cases over 12 years. *Coloproctology* 42(3):270–276
19. Patcharatrakul T, Rao SSC (2018) Update on the pathophysiology and management of anorectal disorders. *Gut Liver* 12(4):375–384
20. Gupta V, Rodrigues G, Prabhu R, Ravi C. Open versus closed lateral internal anal sphincterotomy in the management of chronic anal fissures: A prospective randomized study. *Asian J Surg.* 2014;37(4):178-83
21. Dekker L, Zimmerman DDE, Smeenk RM, Schouten R, Han-Geurts IJM (2021) Management of cryptoglandular fistula-in-and among gastrointestinal surgeons in the Netherlands. *Tech Coloproctol* 25(6):709–719
22. Bharucha AE, Lee TH (2016) Anorectal and pelvic pain. *Mayo Clin Proc* 91(10):1471–1486
23. Bocchini R, Chiarioni G, Corazziari E, Pucciani F, Torresan F, Alduini P et al (2019) Pelvic floor rehabilitation for defecation disorders. *Tech Coloproctol* 23(2):101–115
24. Borsuk DJ, Studniarek A, Park JJ, Marecik SJ, Mellgren A, Kochar K (2021) Use of botulinum toxin injections for the treatment of chronic anal fissure: results from an American Society of Colon and Rectal Surgeons Survey. *Am Surg* 1555–9823
25. Bobkiewicz A, Francuzik W, Krokowicz L, Studniarek A, Ledwoński W, Paszkowski J et al (2016) Botulinum toxin injection for treatment of chronic anal fissure: is there any dose-dependent efficiency?. A meta-analysis. *World J Surg* 40(1432–2323 (Electronic)):3064–3072
26. Gardner I.H., Siddharthan R.V., Tsikitis V.L.: Benign anorectal disease: hemorrhoids, fissures, and fistulas. *Ann Gastroenterol.*, 2020; 33(1): 9–18.
27. Newman M., Collie M.: Anal fissure: diagnosis, management, and referral in primary care. *Br J Gen Pract.*, 2019; 69(685): 409–410.
28. Alvandipour M., Ala S., Khalvati M., Yazdanicharati J., Koulaeinejad N.: Topical Minoxidil Versus Topical Diltiazem for Chemical Sphincterotomy of Chronic Anal Fissure: A Prospective, Randomized, Double-Blind, Clinical Trial. *World J Surg.*, 2018; 42(7): 2252–2258