

# Role of Transamin in Reduction of Seroma in Post-Operative Mastectomy

OMER FAROOQ<sup>1</sup>, HAFIZ ALI MUHAMMAD<sup>2</sup>, ARSHIA RASOOL<sup>3</sup>, QAZI MUHAMMAD SIBGHATULLAH<sup>4</sup>, ALEENA HAMEED<sup>5</sup>, KHAULA ASIF<sup>6</sup>

<sup>1</sup>Consultant surgeon, District Headquarters Hospital, Attock

<sup>2</sup>Medical Officer, Own Pvt. Clinic

<sup>3</sup>Post Graduate Resident, Gynae, Victoria Hospital, Bahawalpur

<sup>4</sup>District Medical Officer Rawalpindi, Health & Accidental Insurance (H&AI), State Life

<sup>5</sup>Medical officer, Medicare Hospital, Attock

<sup>6</sup>Medical Officer

Corresponding author: Aleena Hameed, Email: [aleenahameed@gmail.com](mailto:aleenahameed@gmail.com)

## ABSTRACT

**Objective:** The purpose of this study to determine the effectiveness of transamin in reduction of seroma in post-operative mastectomy.

**Study Design:** Retrospective study

**Place and Duration:** District Headquarter Hospital Attock and Medicare Hospital, Attock. September 2021-July 2022.

**Methods:** There were 40 females had breast cancer with age 20-65 years were included. Patients were underwent for mastectomy and admitted to hospital. After obtaining informed written consent detailed demographics of enrolled cases included age, body mass index and socio-economic status was recorded. After surgery patients received injection of tranexamic acid. Outcomes among all patients were assessed in terms of reduction in seroma formation, wound infection, amount of drainage and time of drainage. SPSS 22.0 was used to analyze all data.

**Results:** We found that 7 (20%) patients had age 21-30 years, 12 (30%) cases had age 31-40 years, 17 (42.5%) cases had age 41-50 years and 4 (10%) cases had age 51-65 years. 26 (65%) patients had BMI >25kg/m<sup>2</sup> and 14 (35%) had BMI <25kg/m<sup>2</sup>. There were 22 (55%) patients had poor socio-economic status. Mean amount of drainage was 812.7±99.24 ml and mean time of drainage was 7.5±12.40 days. Frequency of seroma formation was found in 5 (12.5%) cases in which mostly had BMI >25kg/m<sup>2</sup> and had increased age. Wound infection found in 3 (7.5%) cases.

**Conclusion:** We concluded in this study use of tranexamic acid among patients undergoing mastectomy was affective and useful in terms of reduction in seroma formation and lower number of wound infection. Except this duration and volume of drainage was also seen lower in our study.

**Keywords:** Breast Cancer, Mastectomy, Seroma, Tranexamic Acid, Complications

## INTRODUCTION

An artificial amino acid called tranexamic acid prevents the conversion of plasminogen to the enzymatic plasmin. By causing fibrinolysis, or the breakdown of fibrin that has already been generated in blood clots, plasmin causes clot lysis. Although there has been some controversy surrounding the use of TXA after breast surgery, interest in the topic has lately grown. This interest has been diminished by the potential danger of thromboembolic incidents, notably for people with cancer and breast reconstruction requiring micro-vascular anastomoses. Haematoma and seroma production are rare complications that might arise during surgery either with or without surgical intervention [1, 2]. Haematoma is also a danger during cosmetic breast surgery [3].

TXA has been thoroughly examined in a number of medical specialties, including trauma, orthopaedics, gynaecology, and cardiothoracics [4]; it has been demonstrated that when applied topically or intravenously, it can minimise bleeding and the requirement for blood transfusions [5]. Smaller studies have further shown that TXA reduces seromadevelopment [6].

Seroma is brought on by the disruption of the lymphatic channels and the creation of a sizable gap between both the fascia after flap elevation. Seroma fluid has shown several elements that lend credence to this theory. High amounts of IgG, phagocytes, granulocytes, proteinases, proteinase inhibitors, and other cytokines are among these factors. [7] Seroma development lengthens the recuperation period by causing flap necrosis, chronic discomfort, increased infection risk, and delayed wound healing [8].

With the sharp rise in the incidence of breast cancer both globally and locally, there is a tendency toward minimising patient morbidity through meticulous medical intervention to avoid problems like abscess formation; use of pre-operative steroids appears to be practical, affordable, and shows promising outcomes in trials [9].

Low-cost, straightforward, effective, and safe preventive measures should be used to reduce postoperative blood loss. With minimal systemic concentrations, topical use of TXA may result in

a high drug levels on the wound surface[10]. There is still no agreement on the best TXA concentration of the solution administered, the method of application, or the length of contact time for topical use[11]. The majority of papers deal with joint replacement surgery, when TXA is injected as a bolus into the joint to minimise bleeding to a level comparable to intravenous administration[12]. In a modest proof-of-concept, randomised, placebo-controlled research of bilateral reduction mammoplasty, the current authors first presented a unique technique in which the wound surface is just hydrated with mcg tranexamic acid before closure, resulting in a mean 39% reduction in drain volume. Compared to topical boluses, this moistening significantly reduces the amount of time the wound surface is exposed to TXA [13].

This study's goal was to examine the impact of this moistening technique on a bigger population using a new study model. As a typical and regular surgical technique with uniform wounds and low occult blood loss, mastectomy was selected as a good model for bleeding. The impact of external TXA on seroma development was also researched since postoperative seroma following mastectomy is a significant adverse event[14,15].

## MATERIAL AND METHODS

This retrospective study was conducted at District Headquarter Hospital Attock/Medicare Hospital, Attock and comprised of 40 patients. After obtaining informed written consent detailed demographics of enrolled cases included age, body mass index and socio-economic status was recorded. Patients who were pregnant or nursing, who were known to be allergic to TXA, and who had thromboembolic illness or a high risk of thrombosis necessitating additional anticoagulation in conjunction with the surgery were not included.

A sequential list of patients over the age of 20 who were scheduled to have either a simple mastectomy, a mastectomy with strategic node biopsy (SNB), or a mastectomy to axillary lymph removal were compiled. Each patient was administered 20 ml of TXA 25 mg/ml. To make TXA 25 mg/ml, we took 5 ml out of a 20 ml bottle of 0.9% saline and added 5 milliliter TXA 100 mg/ml into

the same container, for a total of TXA 25 mg/ml. During surgery, the size, density, and weight of a breast specimen were recorded. The wound area was found to be elliptical in shape (height/2 width/2 ). Patients were given active vacuum drains with a precise time point to record drain output 24 hours after surgery was completed. All other aspects of the procedure, including preoperative evaluation, surgical execution, postoperative care, and drain removal, were performed in line with standard practice at the attending study centers; consequently, randomization was stratified by study center.

Drain output volume in the first 24 hours after surgery was used as the primary outcome measure of postoperative bleeding. Besides primary outcomes like blood loss and length of time spent draining it, secondary outcomes included the occurrence of early haematoma, postoperative complications, and seroma formation. To clarify, seroma has been defined as fluid retention requiring aspiration after the drain was taken out. We considered seroma that lasted longer than three months to be chronic.SPSS 22.0 was used to analyze all data.

**RESULTS**

There were 26 (65%) patients had BMI >25kg/m<sup>2</sup> and 14 (35%) had BMI <25kg/m<sup>2</sup>. There were 22 (55%) patients had poor socio-economic status. 24 (60%) patients had size of tumor T<sub>1</sub>. Mean lymph node was 15.8±6.28. 80 (61.5%) cases had T<sub>1</sub> tumor size and mean duration of surgery was 67.19±14.63 minutes.(table 1)

Table-1: Baseline characteristics of presented cases

Variables	Frequency (40)	Percentage
BMI		
>25kg/m <sup>2</sup>	26	65
<25kg/m <sup>2</sup>	14	35
Size of Tumor		
T <sub>1</sub>	24	60
T <sub>2</sub>	16	40
Socio-economic status		
Poor	22	55
Middle/upper	18	45
Mean Lymph node	15.8±6.28	
Mean Surgery Time (min)	67.19±14.63	

We found that 7 (20%) patients had age 21-30 years, 12 (30%) cases had age 31-40 years, 17 (42.5%) cases had age 41-50 years and 4 (10%) cases had age 51-65 years. (figure-1)

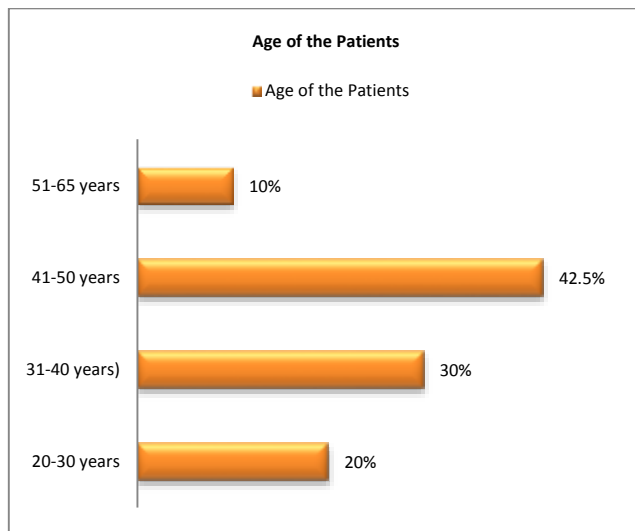


Figure-1: Included patients with age distribution

Mean amount of drainage was 812.7±99.24 ml and mean time of drainage was 7.5±12.40 days.(table 2)

Table-2: Amount and time of drainage among all cases

Variables	Mean	Standard Deviation
Amount of drainage	812.7	99.24
Time of drainage	7.5	12.40

Frequency of seroma formation was found in 5 (12.5%) cases and 35 (87.5%) cases did not have seroma formation.(figure 2)

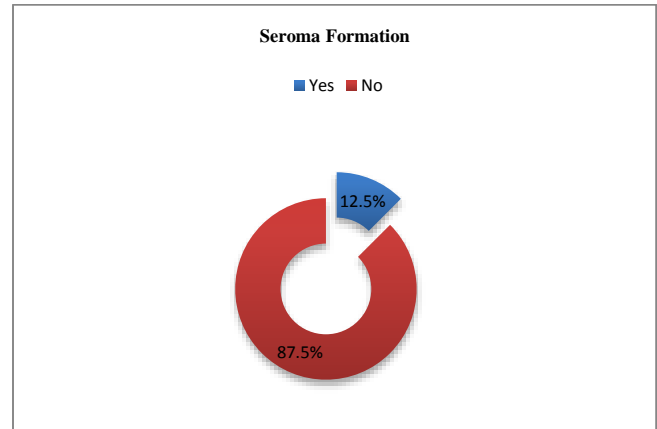


Figure-2: Association of seroma among all cases

Among 5 cases of seroma, 4 (80%) were obese had BMI >25kg/m<sup>2</sup> and 1 (20%) had BMI <25kg/m<sup>2</sup>.(table 3)

Table-3: Association of BMI among seroma cases

Variables	Frequency	Percentage
BMI		
>25kg/m <sup>2</sup>	4	80
<25kg/m <sup>2</sup>	1	20

In all included cases, post-operatively wound infection was found in 3 (7.5%) cases.(table 4)

Table-4: Frequency of complication among all cases

Complications	Frequency (40)	Percentage
Wound Infection		
Yes	3	7.5
No	37	92.5

**DISCUSSION**

Most seromas develop after procedures involving the breast (mastectomy) or arm (axillectomy). Prolonged drainage is problematic because it raises the risk for infections and can greatly postpone adjuvant therapy. Since the exact source of a seroma is a mystery, the multifactorial-cause hypothesis has gained acceptance. Flap fixation techniques, sclerosants, fibrinogen glue and sealants, everolimus, and compression garments have all been tried to eliminate void spaces, but the results have been inconsistent at best. Early drain removal has been linked to less seroma formation, according to a study of drain usage [16].

In current study, 40 cases of breast cancer were included. We found that 7 (20%) patients had age 21-30 years, 12 (30%) cases had age 31-40 years, 17 (42.5%) cases had age 41-50 years and 4 (10%) cases had age 51-65 years. These results were comparable to the previous researches.[17,18]The authors proposed that single dose of tranexamic acid inside the dead space following mastectomy and anterior evacuation is efficient in regulating the amount of post - operative liquid output; consequently, it could permit early sink removal and less abscess forming and wound infection as well as early adjuvant treatment.

Bolus instillations of topical tranexamic acid into restricted spaces like a joint, the pulmonary trunk, or the peritoneum, or the application of soaked gauze to easily accessible wounds, were the

primary routes of administration in prior studies. Just moistening the wound's surface has been described in a few studies [19]. Tranexamic acid prepared by diluting in saline can moisten huge regions, which is useful after massive surgery for weight loss or in patients who have undergone mastectomies [18,19], whereas most pertinent hemostatic agents can only cover a small surface area. In current study 10.8% cases showed seroma formation. Prior one study presented same results to our findings.[20]

Despite the absence of an rise in chronic seroma, wound infection, or wound rupture in the TXA treatment, the rise in abscess volume following TXA in patients who had lymph node clearance suggests the possibility that TXA topical administration may cause a delay in tissue adhesion or lymph vessel healing.[21]

The safety of TXA is called into doubt, however, after the current HALT-IT study [22] discovered an increase in deep thrombotic events embolism with TXA treatment in acute intestinal bleeding among 12,009 individuals, with no advantages to mortality. A prospective propensity matched research [23] showed a higher incidence of venous thrombosis in 21,931 trauma patients, but again, there was no survival benefit. Because the incident is rare, it's possible that this elevated thrombotic risk is only observed in large studies. Less is understood regarding the advantages of TXA in surgical procedures where significant haemorrhage is less frequent. A retrospective cohort research [24] published in 2015 in the magazine of military medicine reported no higher incidence of thromboembolic events, such as flap thrombosis, or other thromboembolic complications.

**CONCLUSION**

We concluded in this study use of tranexamic acid among patients undergoing mastectomy was affective and useful in terms of reduction in seroma formation and lower number of wound infection. Except this duration and volume of drainage was also seen lower in our study.

**REFERENCES**

1 Nwaogu IY, Bommarito K, Olsen MA, et al. Economic impact of bleeding complications after mastectomy. *J Surg Res* 2015;199:77-83

2 Carless PA, Henry DA. Systematic review and meta-analysis of the use of fibrin sealant to prevent seroma formation after breast cancer surgery. *Br J Surg* 2006;93:810-9

3 Gupta V, Yeslev M, Winocour J, et al. Aesthetic Breast Surgery and Concomitant Procedures: Incidence and Risk Factors for Major Complications in 73,608 Cases. *AesthetSurg J* 2017;37:515-27.

4 Bryant-Smith AC, Lethaby A, Farquhar C, et al. Antifibrinolytics for heavy menstrual bleeding. *Cochrane Database Syst Rev* 2018;4:CD000249

5 Teoh WY, Tan TG, Ng KT, et al. Prophylactic Topical Tranexamic Acid Versus Placebo in Surgical Patients: A Systematic Review and Meta-Analysis. *Ann Surg* 2021;273:676-83

6 Oertli D, Laffer U, Haberthuer F, et al. Perioperative and postoperative tranexamic acid reduces the local wound complication rate after surgery for breast cancer. *Br J Surg* 1994;81:856-9

7 Srivastava V, Basu S, Shukla VK. Seroma formation after breast cancer surgery: what we have learned in the last two decades. *J Breast Cancer*. 2012;15(4):373-80

8 Suresh BP, Sachin HG, Naidu M, Gopalkrishna V. A study to evaluate the factors influencing seroma formation after breast cancer surgery at tertiary care centre. *IntSurg J*. 2018;6(1):278-82.

9 Khan MA. Effect of preoperative intravenous steroids on seroma formation after modified radical mastectomy. *J Ayub Med Coll Abbottabad*. 2017;29(2):207-10.

10 Ausen K, Pleym H, Liu J, Hegstad S, Nordgård HB, Pavlovic et al. . Serum concentrations and pharmacokinetics of tranexamic acid after two means of topical administration in massive weight loss skin-reducing surgery. *PlastReconstrSurg* 2019; 143: 1169e–1178e.

11 Nouraei SM. What are the optimal dose of administration and time of drainage for topical tranexamic acid in patients undergoing cardiac surgery? *Korean J ThoracCardiovascSurg* 2017; 50: 477–478.

12 Ker K, Beecher D, Roberts I. Topical application of tranexamic acid for the reduction of bleeding. *Cochrane Database SystRev* 2013; (7)CD010562.

13 Li J, Zhang Z, Chen J. Comparison of efficacy and safety of topical versus intravenous tranexamic acid in total hip arthroplasty: a meta-analysis. *Medicine (Baltimore)* 2016; 95: e4689.

14 Ausen K, Fossmark R, Spigset O, Pleym H. Randomized clinical trial of topical tranexamic acid after reduction mammoplasty. *Br J Surg* 2015; 102: 1348–1353.

15 van Bommel AJ, van de Velde CJ, Schmitz RF, Liefers GJ. Prevention of seroma formation after axillary dissection in breast cancer: a systematic review. *Eur J SurgOncol* 2011; 37: 829–835

16 Hashemi E, Kaviani A, Najafi M, Ebrahimi M, Hooshmand H, Montazeri A. Seroma formation after surgery for breast cancer *World J SurgOncol*. 2004;2:44

17 Weissler JM, Banuelos J, Alsayed A, Tran NV, Martinez-Jorge J, Manrique OJ, Nguyen MDT, Harless CA. Topical Tranexamic Acid Safely Reduces Seroma and Time to Drain Removal Following Implant-Based Breast Reconstruction. *PlastReconstrSurg Glob Open*. 2020 Oct 9;8(9 Suppl):9-10.

18 Oertli D, Laffer U, Haberthuer F, Kreuter U, Harder F. Perioperative and postoperative tranexamic acid reduces the local wound complication rate after surgery for breast cancer. *Br J Surg*. 1994 Jun;81(6):856-9.

19 Tang YM, Chapman TW, Brooks P. Use of tranexamic acid to reduce bleeding in surgery *J PlastReconstrAesthet Surg*. 2012;65:684–686

20 Eldesouky, Mahmoud S.; Abo Ashour, Hady S.; Shahin, Mahmoud A..Effect of topical application of tranexamic acid on reduction of wound drainage and seroma formation after mastectomy. *The Egyptian Journal of Surgery*: Oct–Dec 2019 - Volume 38 - Issue 4 - p 772-775

21 K Ausen, A I Hagen, H S Østbyhaug, S Olafsson, B J Kvalsund, O Spigset, H Pleym, Topical moistening of mastectomy wounds with diluted tranexamic acid to reduce bleeding: randomized clinical trial, *BJS Open*, Volume 4, Issue 2, April 2020, Pages 216–224,

22 HALT-IT Trial Collaborators. Effects of a high-dose 24-h infusion of tranexamic acid on death and thromboembolic events in patients with acute gastrointestinal bleeding (HALT-IT): an international randomised, double-blind, placebo-controlled trial. *Lancet* 2020;395:1927-36

23 Myers SP, Kutcher ME, Rosengart MR, et al. Tranexamic acid administration is associated with an increased risk of posttraumatic venous thromboembolism. *J Trauma Acute Care Surg* 2019;86:20-7

24 Valerio IL, Campbell P, Sabino J, et al. TXA in combat casualty care - does it adversely affect extremity reconstruction and flap thrombosis rates? *Mil Med* 2015;180:24-8.