

# Identification of Gall Stones through Ultrasonography in Asymptomatic Patients

IMRAN KHAN MEMON<sup>1</sup>, BHAGWAN DAS<sup>2</sup>, KAILASH KUMAR DASEJA<sup>3</sup>, INAYATULLAH<sup>4</sup>, MUHAMMAD RASHID RASUL<sup>5</sup>, AKHTAR HUSSAIN PHUL<sup>6</sup>

<sup>1-3</sup>Assistant Professors, Department of Radiology, Chandka Medical College Hospital, Larkana

<sup>4</sup>Assistant Professor, Department of Radiology, Ghulam Muhammad Mahar Medical College, Sukkur

<sup>5</sup>Assistant Professor, Department of Radiology, DG Khan Medical College, Dera Ghazi Khan

<sup>6</sup>Assistant Professor, Department of Radiology, Khairpur Medical College, Khairpur Mir's

Correspondence to: Imran Khan Memon, Email: [drimran1978@hotmail.com](mailto:drimran1978@hotmail.com), Cell: 0333-3541230

## ABSTRACT

**Objective:** To identify gall stones through ultrasonography in asymptomatic patients.

**Study Design:** Prospective study

**Place and Duration of Study:** Department of Radiology, Chandka Medical College Hospital, Larkana from 1<sup>st</sup> January 2021 to 31<sup>st</sup> December 2021.

**Methodology:** Two hundred and fifty patients who were not having symptoms of gallbladder stones and were diagnosed through ultrasonography were enrolled. The examination was recommended post 8 hour fasting period. The stones which were stuck in neck of gallbladder or main gallbladder were also observed and their dimensional measurements were taken. The inflammation of the gallbladder was analyzed through the gallbladder thickness. All the demographic variables and clinical outcomes were documented on a well-structured questionnaire.

**Results:** The mean age of the patients was 39.9±3.4 years with highest number of patients who came for an ultrasound was between 38-42 years. There were more women suffering from asymptomatic gallbladderstones. The ultrasonographic evaluation showed that only 6% patients with symptomatic cholelithiasis had gallbladder wall thickening greater than 3mm. Pericholecystic fluid was also not presented in majority of the patients. Ultrasonography was positively able to identify gall stones in 97% of the asymptomatic cases

**Conclusion:** Ultrasonography gave substantial results in almost 97% of the patients. Radiologists should have expertise in prompt diagnosis and treatment of underlying condition.

**Keywords:** Gall stones, Asymptomatic, Ultrasonography, Mortality, Bile duct

## INTRODUCTION

Gallstones as well as its complications are worldwide significant.<sup>1-3</sup> Only in USA 350,000 cases were reported in year 2014. The worldwide incidence of this disease is reported as 6 to 22% of gall stones. Majority of the cases reported of the gall stones are asymptomatic with complication probability only in 2% of the symptomatic cases.<sup>4-6</sup> Obesity has been related with gall stones formation and thus is a main factor of increasing its frequency over the globe.<sup>7,8</sup> Inflammation as a result of gallbladder is ranked as thirteenth among non-cancer inflammations with gastrointestinal related reasoning. Cholangitis has been reported as much more severe condition and a mortality causer.<sup>9</sup>

Bile which is secreted through biliary duct merges into the larger ducts inside the liver. Further this emerges into hepatic ducts from right and left. This emerges into the main common hepatic-duct.<sup>10</sup> Ultrasound has long been identified as an efficient technique for identifying gallbladder stones in cases showing clinical symptoms of GB stones and required urgent treatment plan.<sup>11-13</sup> Gall stones are presented in 10 to 20% of the developing countries populate. The incidence further escalates with the increasing age and women gender. Eighty percent of the cases reported with GB stones are asymptomatic.

These patients remain asymptomatic in most of the cases throughout their life. In conditions of acute cholecystitis, obstructive-cholangitis or gall stones pancreatitis the risk of complication which can become life threatening is much higher.<sup>14</sup> The present study evaluated the role of ultrasound in identifying gall stones in asymptomatic cases. The results which were observed were highly significant in identifying the variability from the symptomatic cases and thus facilitating in providing better understating and timely diagnosis of asymptomatic cases of gall stones.

## MATERIALS AND METHODS

This prospective study was conducted at Department of Radiology, Chandka Medical College Hospital, Larkana from 1<sup>st</sup> January 2021 to 31<sup>st</sup> December 2021. A total of 250 patients having no symptoms of gallbladder stones and diagnosed through

ultrasonography were enrolled. The examination was recommended post 8 hour fasting period. The sample size was calculated after taking prevalence of asymptomatic cholelithiasis as 80% and of gall stones as 10-20% in developing countries. The sample size generation was dependent upon 95% CI and 80% power of test with 5% margin of error. The gall stones in GB casted shadow effect as observed through USG. The stones which were stuck in neck of GB or the main GB were also observed and their dimensional measurements were taken. The inflammation of the GB was analyzed through the GB thickness. All the demographic variables and clinical outcomes as well as ultrasonographical characteristics including GB wall thickening, peri-cholecystic fluid, GB distension >5cm and Murphy sign were documented. Appearance of gall stones in echogenic-foci was recognized. Data was entered and analyzed through SPSS version 26.

## RESULTS

The mean age of the patients was 39.9±3.4 years with highest number of patients who came for an ultrasound was between 38-42 years. There were more women suffering from asymptomatic GB stones than men with a percentage of 76% vs 24% respectively (Table 1).

Table 1: Distribution of age and gender within asymptomatic patients (n=50)

Variable	No.	%
<b>Age (years)</b>		
27 – 32	35	14.0
33 – 37	40	16.0
38 – 42	75	30.0
43 – 47	60	24.0
> 47	40	16.0
<b>Gender</b>		
Male	60	24.0
Female	190	76.0

The USG evaluation showed that only 6% patients with symptomatic cholelithiasis had GB wall thickening greater than 3mm. Pericholecystic fluid was also not presented in majority of the patients with only 10% having it. There were 40% those

patients having GB distension higher than 5cm with Murphy sign only presented in 32% cases. The GB size was >30 mm up to 110 mm in 30% of the symptomatic patients (Table 2).

Ultrasonography was positively able to identify gall stones in 97% of the asymptomatic cases. However 3% were those where the verification was not completed either due to the patient not following the required standard protocol or due to other confounding variables as obesity or fat deposits (Fig. 1).

Table 2: Frequency of ultrasound findings for GB stones (n=250)

Ultrasonography	No.	%
Clinical Features cholelithiasis		
GB wall thickening> 3 mm	15	6.0
Pericholecystic fluid	25	10.0
GB distension >5cm	100	40.0
Murphy sign	80	32.0
CBD stone appearance	30	12.0

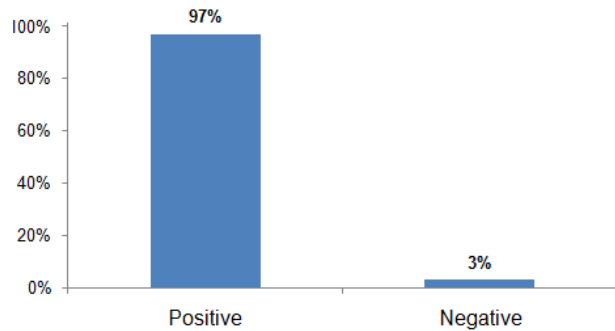


Fig. 1: Ultrasonography based diagnosis of gall stones

**DISCUSSION**

The diagnosis of gall stones is accidental in many cases with lack of symptoms in majority. Despite of this fact the rate of complications in asymptomatic cases can still be high as 20%. As soon as once gall stones symptoms starts presenting in a non-symptomatic patient it is predicted that episodic symptoms will keep on appearing in almost 10-30% of the cases until treated surgically. Incidence of gall stones is quite higher in western world due to various underlying reasons one of which is obesity.<sup>15-17</sup> Various imaging related modalities can be used for the diagnosis of gall stone associated complications and diseases including magnetic resonance imaging (MRI), scintigraphy, computed tomography (CT), and ultrasonography. In present study, ultrasonography was used for the identification of the gall stones.<sup>18-20</sup>

O'Connor and Maher<sup>21</sup> have proved the advantages of ultrasonography as an imaging and diagnostic modality which takes added benefits from others due to non-invasiveness and no requirement of radiation dose for patients. Ultrasound represents acoustic shadowing of gallstones regardless of the composition and type of gallstone. It also proves beneficial in distinguishing gallstones from gallbladder polyps through ultrasonography, medical practitioner able to investigate acute cholecystitis by Murphy's sign which is reliable and prominent predictor of acute cholecystitis.

Role of imaging techniques has greatly improved and several advancements made with the passage of time in order to refrain and diagnose various disease and complication with greater

efficacy. Radiologist should have expertise in its handling and for the prompt diagnosis of underlying condition.

**CONCLUSION**

Ultrasonography gave substantial results in almost 97% of the patients. Radiologists should have expertise in prompt diagnosis and treatment of underlying condition.

**REFERENCES**

1. Peery AF, Crockett SD, Murphy CC, et al. Burden and Cost of Gastrointestinal, Liver, and Pancreatic Diseases in the United States: Update 2018. *Gastroenterology* 2019; 156: 254-72.e11.
2. Bray F, Balcaen T, Baro E, et al. Increased incidence of cholecystectomy related to gallbladder disease in France: Analysis of 807,307 cholecystectomy procedures over a period of seven years. *J Visc Surg* 2019; 156: 209-15.
3. Enochsson L, Sandblom G, Österberg J, et al. Gallriks 10 years: quality registry for gallstone surgery have improved health care. *Lakartidningen* 2015; 112:6.
4. Aerts R, Penninckx F. The burden of gallstone disease in Europe. *Aliment Pharmacol Ther* 2003; 18(Suppl 3): 49-53.
5. Everhart JE, Yeh F, Lee ET, et al. Prevalence of gallbladder disease in American Indian populations: findings from the Strong Heart Study. *Hepatology* 2002; 35: 1507-12.
6. Stinton LM, Shaffer EA. Epidemiology of gallbladder disease: cholelithiasis and cancer. *Gut Liver* 2012; 6: 172-87.
7. Pogorelic Z, Aralica M, Jukic M, et al. Gallbladder disease in children: a 20-year single-center experience. *Indian Pediatr* 2019; 56: 384-6.
8. Noviello C, Papparella A, Romano M, et al. Risk factors of cholelithiasis unrelated to hematological disorders in pediatric patients undergoing cholecystectomy. *Gastroenterol Res* 2018; 11: 346-8.
9. Ahmed M. Acute cholangitis - an update. *World J Gastrointest Pathophysiol* 2018; 9: 1-7.
10. Abou-Khalil JE, Bertens KA. Embryology, anatomy, and imaging of the biliary tree. *Surg Clin North Am* 2019; 99: 163-74.
11. Wang HH, Tiangang L, Portincasa P, et al. New insights into the role of Lith genes in the formation of cholesterol-supersaturated bile. *Liver Res* 2017; 1: 42-53.
12. Itani M, Dubinsky TJ. Physical Chemistry of Bile: Detailed Pathogenesis of Cholelithiasis. *Ultrasound Q* 2017; 33: 229-36.
13. Keplinger KM, Bloomston M. Anatomy and embryology of the biliary tract. *Surg Clin North Am* 2014; 94: 203-17.
14. Farokh R Demehri, Hasan B Alam. Evidence-based management of common gallstone-related emergencies. *J Intensive Care Med* 2016; 31(1): 3-13.
15. Behari A, Kapoor VK. Asymptomatic gallstones (AsGS) - to treat or not to? *Indian J Surg* 2012; 74(1), 4-12.
16. Sakorafas GH, Milingos D, Peros G. Asymptomatic cholelithiasis: is cholecystectomy really needed? A critical reappraisal 15 years after the introduction of laparoscopic cholecystectomy. *Dig Dis Sci* 2007; 52(5):1313-25.
17. Lammert F, Acalovschi M, Ercolani G, van Erpecum KJ, Gurusamy K, van Laarhoven CJ, et al. EASL Clinical Practice Guidelines on the prevention, diagnosis and treatment of gallstones. 2016
18. Everhart JE, Khare M, Hill M, Maurer KR (1999) Prevalence and ethnic differences in gallbladder disease in the United States. *Gastroenterology* 1999; 117(3):632-9.
19. Murphy MC, Gibney B, Gillespie C, Hynes J, Bolster F. (2020). Gallstones top to toe: what the radiologist needs to know. *Insights Imaging* 2020; 11(1): 1-14.
20. Kopf H, Schima W, Meng S. Differenzialdiagnose von Befunden an der Gallenblase: Ultraschall, Computertomographie und magnetresonanztomographie [differential diagnosis of gallbladder abnormalities: ultrasound, computed tomography, and magnetic resonance imaging]. *Radiologe* 2019;59(4):328-37.
21. O'Connor OJ, Maher MM (2011) Imaging of cholecystitis. *AJR Am J Roentgenol* 196:W367-74.