

# Use of Reamed Interlocking Nail in the Management of Closed Tibial Shaft Fractures

SYED ALI HAZIQ BUKHARI<sup>1</sup>, AWAIS GHULAM NABI<sup>2</sup>, MUHAMMAD SAAD<sup>3</sup>

<sup>1</sup>Medical officer in THQ kotmomin district Sargodha ,Punjab medical college

<sup>2</sup>Medical officer THQ hospital sillanwali district Sargodha, Punjab Medical College Faisalabad

<sup>3</sup>Medical Officer ( THQ Hospital Jaranwala), Lahore Medical and Dental College, Lahore.

Corresponding author: Syed Ali Haziq bukhari

## ABSTRACT

**Objective:** Reamed interlocking nails are being tested for their ability to treat closed tibial shaft fractures.

**Study Design:** Observational / Descriptive study

**Place and Duration:** THQ kotmomin district Sargodha ,Punjab medical college. Jan 2021-Oct 2021

**Methods:** For this research, a total of 110 patients of both sexes participated. Cases were enrolled between the ages of 18 and 75. After obtaining written permission, demographic information about enrolled patients was collected. Patients with a reaming interlocking nail on their tibial shaft were brought to the emergency room. Union time and the incidence of complications were evaluated postoperatively. During the course of 12 months, all of the patients' follow-ups were completed. SPSS 23.0 was used to analyze the data.

**Results:** The patients' average age was 30.12±6.33 years, and their BMI was 25.21±6.55 kg/m<sup>2</sup>. Majority cases 70 (63.6%) were male and 40 (36.4%) were female. The most prevalent cause of fracture was a car collision, followed by a fall from a great height. We found majority of the cases had tibial fracture at middle one third 77 (70%). Simple fractures had a mean union time of 11.32±9.54 weeks, whereas segmental fractures had a mean union time of 17.7±8.54 weeks. Union fractures occurred at a rate of 90 (81.8%), and overall satisfaction was 95 (86.4%).

**Conclusion:** In this research, we came to the conclusion that the use of a reamed interlocking nail was the most successful and safest approach of treating closed tibial shaft fracture. In this research, the overall union rate was high, and there was minimal morbidity among the patients.

**Keywords:** Tibial shaft fractures, Interlocking nail, Union

## INTRODUCTION

Tibial shaft fractures, which occur at a rate of around 26 per 100,000 people each year as a result of high-energy trauma, such as car crashes, affect men more often than women. [1] These fractures are more susceptible to infection and nonunion due to a lack of blood flow around the tibial shaft. [2,3]

For closed and open tibial shaft fractures, intramedullary nails are an option. Intramedullary nailing is very susceptible to infection in open tibial shaft fractures of grades 2 and 3. Closed and open grade 1 fractures are often treated with intramedullary nailing. Tibial shaft open fractures in individuals with multiple trauma are better served by delayed fixation than by immediate fixation, both in terms of radiological and clinical results. [4,5]

Union with normal length, normal alignment without rotation, deformity, normal joint mobility, and shortened hospital stay are acceptable therapeutic goals for fractured tibia. At some point in the last 40 years or so, Charnley (1961) noted, "we still haven't come up with a definitive approach for treating fractures of the tibial shaft". Tibial fixation with the intramedullary nail (Lottes, Ender) has a lengthy history. Since tibial fractures are treated differently, it is impossible to treat all of them with a single approach. The treatment of tibial fractures has fluctuated over the last 50 years like a pendulum between non-surgical and surgical options. Plaster casts were used to treat tibial shaft fractures in the past. After then, functional braces were widely utilised. [9] Lambott is credited with the first recorded use of an intramedullary rod in 1907. For closed nailing in the tibia without reaming, a semi-rigid triflange intramedullary nail was introduced in 1974. Comminuted fractures remain a concern, as does the lack of rotational stability and normal length provided by the nail. External fixation was most popular in the 1960s and 1970s. [10] Non-Union, infection, and fixation failure were all increased as a result of the plating. Pintract infection and occasionally bone necrosis occurred as a consequence of external fixation. New techniques have been developed to address these issues. One of these is called "close tibial interlock nailing," and it is designed to reduce exposure and surgical trauma while also promoting rapid healing and restoring function as soon as possible.

Screws at both ends of the interlocking nail secure it to the bone intramedullary. An intramedullary tibial tuberosity interlocking

nail, or tibial interlocking nail, is inserted at the tibial tuberosity and fixed at both ends with screws in a closed tibial interlocking procedure. In the beginning, the close tibial interlock nailing was used without reaming, but this method was abandoned due to nonunion and delayed union. Normal length, angulation correction, and rotation correction can all be controlled with this device.

As an internal splint and load shaving tool, nails fastened together furnish the region with bone graft. Strengthens the area around the fracture, preventing it from being pushed beyond the point at which it could cause it to displace. In order to avoid rehabilitation and minimize stress shaving, clamping clocks can be used to move adjacent joints.

## MATERIAL AND METHODS

This descriptive/observational study was conducted at THQ kotmomin district Sargodha ,Punjab medical college and consists of 110 patients. After obtaining informed consent, we compiled demographic data on each patient, including their age, gender, and height/weight. In this research, patients were omitted if they had open fractures, pathological fractures, or had not provided written permission.

The enrolled patients ranged in age from 18 to 75 years. After being sent to the emergency room with a tibial shaft fracture, patients had surgery to install a reamed interlocking nail. Interlocking intramedullary nails (8-11 mm diameter, 30 to 38 cm long) were utilised for preoperative ceftriaxon (2 gm). For the next two weeks, antibiotics were prescribed. First postoperative day, patients were able to move. Exercises for the knee and ankle have begun. On the first post-operative day, patients were permitted to touch weight bear, half weight bear after six weeks when X-rays showed callus, and full weight bear after the fracture healed. The fourteenth post-operative day saw the removal of the stitches. For the initial visit, patients were checked in for a fortnight, and then every four weeks thereafter. Patients' reunification time and complication rate were tracked after surgery. For a total of 14 months, the patients were monitored, which was the prescribed length of time. The frequency and percentage were used to assess category variables, whereas the standard deviation of a population was used to evaluate descriptive variables. The SPSS 23.0 version was used to examine the data.

**RESULTS**

In current study majority cases 70 (63.6%) were male and 40 (36.4%) were female.(fig 1)

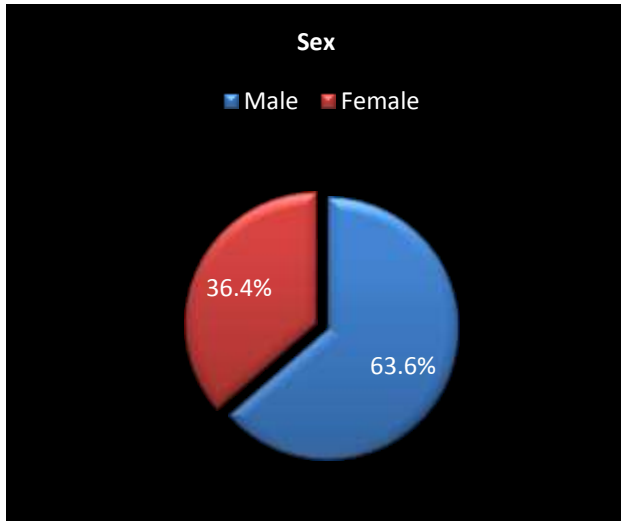


Figure 1: Gender distribution among all cases

The patients' average age was 30.12±6.33 years, and their BMI was 25.21±6.55 kg/m<sup>2</sup>. The most prevalent cause of fracture was a car collision, followed by a fall from a great height. (table 1)

Table 1: The features of instances that have been accepted for enrollment

Variables	Frequency	Percentage
Mean age (years)	30.12±6.33	
Mean BMI (kg/m <sup>2</sup> )	25.21±6.55	
Causes of Fracture		
Road Traffic Accident	75	68.2
Falling	25	22.7
Other Causes	10	9.1

We found majority of the cases had tibial fracture at middle one third 77 (70%). (table 2)

Table 2: Site of tibial shaft fractures

Variables	No.	%age
Middle one third	77	70
Proximal one third	20	18.2
Distal one third	13	11.8
Total	110	100

Simple fractures had a mean union time of 11.32±9.54 weeks, whereas segmental fractures had a mean union time of 17.7±8.54 weeks. (table 3)

Table 3: Union time among all cases

Variables	Mean Standard	Deviation
Mean union time (weeks)		
Simple fractures	11.32	9.54
Segmented fractures	17.7	8.54

Union fractures occurred at a rate of 90 (81.8%), and overall satisfaction was 95 (86.4%). (table 4)

Table 4: Post-operative union rate

Variables	Frequency	%age
Union	90	86.4
Delayed union	12	10.9
Non-union	8	7.3
Satisfaction		
Yes	95	86.4
No	15	13.6

**DISCUSSION**

Options for therapy include plaster cast immobilization, dynamic compression plate (DCP), external fixation (external fixation), and intramedullary interlocking nail (IMI). Even though plaster casts have been the most often used technique of therapy, fracture morphology, kind, and pattern have all restricted their use. Mal-union and a lack of patient compliance are also linked to it.[13] Because of the prolonged immobilization time and extensive soft tissue removal necessary for fixation with dynamic compression plates, infection rates associated with these procedures are unacceptably high. The intramedullary interlocking nail eliminated the mal-union issue, as well as the capacity to manage length, early mobilization, and weight bearing, and excellent patient compliance.[14]

Patients from both genders were included in our research; the mean age was 30.12±6.33 years. In all, 110 patients from both genders participated in our study. The patients' mean body mass index (BMI) was 25.21±6.55 kg/m<sup>2</sup>. The patients ranged in age from 18 to 75 years. Males constituted the vast majority of the patients (63.6 percent). [15] Joshi et al. evaluated 56 Tibial fractures in India, 52 of which were male and 4 of which were female, with the majority of the fractures occurring as a result of road traffic incidents.[16] The presence of a population of tibial fractured consisting of 88.39 percent males and 14.6 percent females was observed in a subsequent research conducted in Karachi, Pakistan, by Ali et al. [17] In our research, 75% of the patients were under the age of 40, which corresponds to the primary earning group in contemporary society. It was consequently critical that they return to work as soon as possible.

In our study, the most prevalent cause of fracture was a road traffic collision, which was identified in 75 cases (68.2%), followed by a fall from a height of 25 cases (22.7%), and the remainder were caused by other causes 10 (9.1%). [15] Simple fractures had a mean union time of 11.32±9.54 weeks, whereas segmental fractures had a mean union time of 17.7±8.54 weeks. Our investigation took 18 weeks on average, whereas In contrast to Vidyadharn et al [18], who examined the effects of clinical radiation from a tibial interlocking nail and found that healing fractures took an average of 20.1 weeks, we found that the average healing period for fractures was 20.1 weeks. It was also mentioned that well-placed intramedullary nails may be used to generate tibial diaphyseal fractures, a rather safe method. When 26 intramedullary fractures were successfully treated in a Turkish research, the findings were good. [19] United Nations General Assembly is five months away. According to the researchers' findings, intra-medullary locking is preferable for treating comminuted fractures because it protects the periosteal circulation and reduces complications. There were no infections or malunions or nonunions or delayed unions in the patients in Court-Brown et al's study, which included 25 healthy individuals. Research done by Larsen et al[20] included 45 participants. Compared to a group of reamed patients, the average time it took for a fracture to heal was 16.7 weeks in an unreamed patient group. P=0.004 indicated that the difference was significant. It was performed by Mohit Bhandari and colleagues (2008) in a randomised, double-blind trial of 1319 patients who had a tibial shaft fracture that had been treated with either intramedullary or unbeatable nailing. The results showed that reamed intramedulla nailing could be beneficial in closed fracture patients. [21]

After treating 35 communicable tibial shaft fractures with interlocking nail and 45 communicable tibial shaft fractures with plating, Haung and colleagues[22] concluded that plating was appropriate for noncommunicable tibial shaft fractures but that interlocking nail should be the implant of choice for communicable tibial shaft fractures. A similar study found that plating of tibial diaphyseal fractures achieved satisfactory results in noncommunicated fractures, but interlocking nail was the best device for communicated shaft fractures because it preserved periosteal blood supply and thus had fewer complications, with a follow-up period of 23 months. [23]

We found majority of the cases had tibial fracture at middle one third 77 (70%). Among these fractures, Union fractures occurred at a rate of 90 (81.8%), and overall satisfaction was 95 (86.4%). Many prior research have shown similar outcomes.[24]. According to Nork et al., they operated on 36 intramedullary nail-locked tibial fractures and found that the average duration to union was 23.5 weeks. The unionisation percentage was 90.6 percent in another survey, and the average duration of the union was 24 weeks. A complete union rate of 97.2 percent was achieved in a study conducted by Shah and colleagues on 36 intramedullary SIGN nail tibial fractures, which took an average of 22 weeks to heal on average. [26] It was discovered that Drosos and colleagues have successfully repaired 157 in-tramedullary nail fractures, with an overall union rate of 97.5 percent and an average union time of 25.8 week for the patients studied. [27]

The evidence presented above demonstrates that intramedullary nailing with closed locking is a safe and effective treatment option for tibial shaft fracture.

## CONCLUSION

In this research, we came to the conclusion that the use of a reamed interlocking nail was the most successful and safest approach of treating closed tibial shaft fracture. In this research, the overall union rate was high, and there was minimal morbidity among the patients.

## REFERENCES

1. Chauhan N, Somashekarappa T, Singh A, Singh G, Rawal A. Interlocking nail in diaphyseal fracture of tibia -A clinical study. *Int J Contemporary Med Res.* 2016;3:1678- 81.
2. Khatod M, Botte MJ, Hoyt DB, Meyer RS, Smith JM, Akeson WH. Outcomes in open tibia fractures: Relationship between delay in treatment and infection. *J Trauma.* 2003;55:949-95
3. Sahni G, Mann HS, Singh R, Bhalla T. Comparative study of interlock nailing versus dynamic compression plating in fractures of tibia-A study of sixty cases. *Indian J Orthop Surg.* 2015;1:197-204.
4. Stanislaw BW, Boguslaw GE. Management of open fractures of tibial shaft in multiple trauma. *Indian J Orthop* 2008; 42:395-400.
5. Faisham WI, Sulaiman AR, Sallehuddin AY, Zuhmi W. Early outcome of reamed interlocking nail for non-union of tibia. *Med J Malaysia* 2006; 61:339-42.
6. Charnley, J.. *The closed treatment of common fractures.* 3rd ed., Edinburgh: 1961;105
7. Sarmiento A.A functional below-the-knee brace for tibial fractures. *J Bone Joint Surg (Am)* 1970; 52 : 295-311.
8. Lottes J.O. Medullary nailing of the tibia with the triflange nail. *Clin Orthop* 1974; 105 : 253-60
9. Janssen KW, Biert J, van Kampen A. Treatment of distal tibial fractures: Plate versus nail: A retrospective outcome analysis of matched pairs of patients. *Int Orthop* 2007; 31 : 709-14.
10. Tornetta P 3rd, Bergman M, Watnik N, Berkowitz G, Steuer J. Treatment of grade III open tibial fractures. A prospective randomized comparison of external fixation and non reamed locked nailing. *J Bone joint Surg* 1994; 75 : 13-9.
11. Niedzwiedzki L. Use of reamed locked intramedullary nailing in the treatment of aseptic diaphyseal tibial non-union. *Ortop Traumatol Rehabil* 2007; 9 : 384-96
12. Court-Brown CM, Will K, Christie J, McQueen MM. Reamed or unreamed nailing for closed tibial fractures. A prospective study in Tscherne C1 fractures. *J Bone Joint Surg [Br]* 1996; 78 : 580-3.
13. Shoab M, Shabir M, Sahibzada AS, Gul R. Outcome of closed reduction and casting in close tibial diaphyseal fractures. *J Med Sci* 2005; 13:154-6.
14. Huang P, Tang PF, Yao Q, Liang YT, Tao S, Zhang Q, et al. A comparative study between intramedullary interlocking nail and plate-screw fixation in the treatment of tibial shaft fractures. *Zhongguo Gu Shang* 2008; 21:261-3
15. Karladani AH, Granhed H, Edshage B, Jerre R, Styf J. Displaced tibial shaft fractures: a prospective randomized study of closed intramedullary nailing versus cast treatment in 53 patients. *Acta Orthop Scand.* 2000;71:160-6.
16. Joshi D, Ahmad A, Krishna L, Lal Y. Unreamed interlocking nailing in open fractures of tibia. *J Orthop Surg (Hong Kong)* 2004; 12:216-21.
17. Ali A, Anjum MP, Humail SM, Qureshi MA. Results of interlocking nails in tibial diaphyseal fractures. *JPOA* 2009; 21:36-44.
18. Vidyadhara S, Sharath KR. Prospective study of the clinicoradiological outcome of interlocked nailing in proximal third tibial shaft fractures. *Injury* 2006; 37 : 536-42.
19. Vaisto O, Toivanen J, Paakkala T, Jarvela T, Kannus P, Jarvinen M. Anterior knee pain after intramedullary nailing of a tibial shaft fracture; An ultrasound study of the patellar tendons of 36 patients. *Orthop Trauma* 2005; 19 : 311-6.
20. Larsen LB, Madsen JE, Høiness PR, Øvre S. Should insertion of intramedullary nails for tibial fractures be with or without reaming? A prospective, randomized study with 3.8 years' follow-up. *J Orthop Trauma.* 2004 Mar;18(3):144-9.
21. Mohit Bhandari. Randomized Trial of Reamed and Unreamed Intramedullary Nailing of Tibial Shaft Fractures. *J Bone Joint Surg Am.* 2008; 90:2567-8.
22. Huang P, Tang PF, Yao Q, Liang YT, Tao S, Zhang Q, et al. A comparative study between intramedullary interlocking nail and platescrew fixation in the treatment of tibial shaft fractures. *Zhongguo Gu Shang.* 2008; 21:261-3
23. Bombaci H, Guneri B, Gorgec M, Kafadar AA. Comparison between locked intramedullary nailing and plate-screw fixation in the treatment of tibial diaphyseal fractures. *Acta Orthop Traumatol Turc* 2004;38:104-9
24. Shah FA, Alam W, Ali MA. Tibial shaft fractures: Interlocking nail versus plating. *J Surg Pakistan.* 2017;22(1):3-7.
25. Nork SE, Schwartz AK, Agel J, Holt SK, Schrick JL, Winquist RA. Intramedullary nailing of distal metaphyseal tibial fractures. *J Bone Joint Surg* 2005; 87:1213-21.
26. Shah RK, Moehring HD, Singh RP, Dhakal A. Surgical Implant generation network (SIGN) intramedullary nailing of open fractures of the tibia. *Int Orthop* 2004; 28:163-6
27. Drosos GI, Bishay M, Karnezis IA, Aleggakis AK. Factors affecting fracture healing after Intramedullary nailing of the tibial diaphysis for closed and grade I open fractures. *J Bone Joint Surg* 2006; 88:227-31.