

Functional Outcomes of Non-operative Treatment in Proximal Humeral Fracture of Adults

MEHTAB ALI SHAHANI¹¹Assistant Professor, KMC Civil Hospital, Khairpur MirsCorrespondence to: Dr. Mehtab Ali Shahani, E-mail: drshahani.dost@gmail.com Cell: 0335-3291084

ABSTRACT

Background: The functional outcomes after non-operative treatment of proximal humeral fractures in adults required detailed understanding for improved health outcomes.

Objective: To identify the functional outcomes of non-operative treatment in proximal humeral fracture of adults.

Study Design: Prospective cohort study

Place and Duration of Study: Department of Orthopaedic, KMC Civil Hospital, Khairpur Mirs from 1st October 2020 to 30th September 2021.

Methodology: Fifty patients with proximal humeral fracture >45 years were treated with non-operative treatment protocol including 1 year follow-up. Patient's radiological imaging was continued till one year and they were given a sling to wear for three week's time. The treatment primary functional outcomes were assessed by Oxford Shoulder Score and EuroQol-5 Dimensions-3 Levels, while secondary functional outcomes were assessed by visual analog scale and university of California Los-Angeles scoring method.

Results: Mean age was 65.6±4.2 years with females as 74% and 26% males. Improvement in OSS was up to 48 points. One-year scores for OSS were mean 33.1 with 95% confidence of interval while it was 0.59 for EQ-5D-3L. Mean VAS pain score was 32.1 with 59.2 as VAS satisfaction score and UCLA activity score as 20.4.

Conclusion: Non-operative treatment for proximal humeral fracture in adults' results in significant changes in shoulder-specific as well as improved health outcomes after one year.

Key words: Proximal humeral fractures, Non-operative, Bone health

INTRODUCTION

The non-operative treatment of proximal humeral fractures (PHF) has widely become an adaptive procedure in situation where adult population is concerned and non-operative treatment with reliability in results need to be attained. The role of surgical procedure in treating PHF still remains controversial leading to non-operative protocols to be adapted for better health outcomes. Studies have shown the used of non-operative treatment for PHF in adults even in severe cases of displaced or multi part fractures.^{1,2}

Various observational researches have shown that non-operative treatment for PHF has provided satisfactory results and improved overall functioning and health outcomes.^{3,4} Despite of this inclination towards non-operative procedure by many researchers, still there is insufficient data to confirm it as a standard protocol. Accept the availability of few research articles on vast cohort studies there is a major lack in knowing detailed results and outcomes of this protocol usage in adult population suffering from PHF.^{5,6}

The present study was aimed for providing detailed information regarding functional outcomes of non-operative technique in treating proximal humeral fractures in adults. The study will benefit in health-related field for understanding the efficiency of non-operative treatment plan in health compromised population.⁷⁻¹⁰

MATERIALS AND METHODS

The study was performed on Department of Orthopaedic, KMC Civil Hospital, Khairpur Mirs from 1st October 2020 to 30th September 2021. Adult patients above age 55 years with isolated non-pathological proximal fractures of humeral bone which are termed according with square method and either involving tuberosity or no tuberosity were included in the study; post their written consent. Patients were scrutinized if they presented with their injury within 2 weeks with no neurovascular evidence of injury. Those having greater or lesser tuberosity and treated through operation were excluded from the study. This study was a 1 year prospective cohort. Clinical and radiological imaging was taken for proper assessment of bone fracture. This imaging was continued on 6th, 12th, 24th week and then at a year time for imaging recovery stages. If there was substantial tuberosity then patients was excluded as aforementioned. This tuberosity was >1cm displacement in three or four parts orientation with complete

separation of humeral head from shaft or severe humeral head angular-deformity with head shaft angle inclining at 160 degree. Patients were given a sling to wear for three week's time. Demographic data and clinical history were documented on proforma. Non union were diagnosed in accordance with fixed available criteria. Outcome measures were accomplished at one year follow-up. Primary outcomes were described through Oxford Shoulder Score (OSS) which is specific to the shoulder. It involves a twelve-item assessment score based on pain in shoulder, its functioning and daily activities. In addition to this a EuroQol-5 Dimensions-3 Levels (EQ-5D-3L) score was also used. It assessed general health in terms of five health assessment domains of self care, mobility, anxiety and pain. It is converted into a scoring method based on time-trade off protocol. The range of OSS is between 0-48 points with highest being best function demonstrator, while the EQ-5D-3L score ranges between 20.543-1 score with higher score representing better health outcomes. Here negative score is considered as "worse than death". The secondary-outcomes measures were made by visual analog scale (VAS) method of assessment involving residual score of pain, health and all over level of satisfaction with outcomes of the treatment in terms of 100 mm scale. University of California Los-Angeles (UCLA) score of activity as 15 at completion of one year was also used. The statistical analysis was performed by the help of SPSS system version 25.0 with using person correlation test, mean and standard deviations as well as chi square for measuring frequencies and percentages. P value <0.001 was taken as significant.

RESULTS

There were fifty patients enrolled within the age of 45-70 years with a mean age of them as 65.6±4.2 years. Most of the registered patients with proximal humeral fracture were females such as 74% in comparison with 26% males. The mode of injury was 90% due to low energy and resulted into a fall in adult patients. Only 8% had previous fracture history related to shoulder bone (Table 1).

Results on hospital admission post injury showed that 88% with tuberosity in 30% of the cases. The fracture related complication which was most prominently noticed was neck fractures in 26% head shaft distraction greater than 1cm in 14% and requirement of operation after one year treatment in only 4%

of the patients. The EQ-5D-3L values as well as OSS values for head shaft translation presented negative scores (Table 2).

The radiographic images presented improvement in OSS upto 48 points after one year follow up in non-operative treatment of PHF. The shoulder movement also improved with time and patients reported 95% satisfaction level with minimal functional-expectations. One similar imaging is presented in Fig 1.

Table 1: Descriptive statistics of the patients

Variable	Values (n=50)	OSS	EQ-5D-3L	P value
Age (years)	65.6±4.2*	-0.25	-0.26	<0.001
Female	37 (74%)	32.5	0.56	<0.001
Male	13 (26%)	34.7	0.65	<0.001
Previous shoulder history	4 (8%)	26.3	0.6	<0.001
Mode of injury by low energy: as fall	45 (90%)	33.1	0.56	<0.001
Mobility	40 (80%)	36.3	0.65	<0.001

One-year scores for OSS were 33.1 with 95% confidence of interval while it was 0.59 for EQ-5D-3L. Considering the secondary

Table 3: Pearson correlation analysis for analyzing primary and secondary outcomes of non-operative treatment of PHF

Out comes	Value at 1 year	OSS	EQ-5D-3L	Pain VAS	Health VAS	Treatment Satisfaction VAS	UCLA activity score at injury	UCLA activity score at 1 year	Change in UCLA activity score
1 year primary outcomes									
OSS*	33.1	1	0.87	-0.8	0.66	0.54	0.49	0.66	0.37
EQ-5D-3L*	0.59	---	1	-0.81	0.71	0.59	0.48	0.62	0.34
1 year Secondary outcomes									
Pain VAS*	32.1	---	---	1	-0.66	-0.61	-0.41	-0.56	-0.3
Health VAS*	68.0	---	---	---	1	0.6	0.46	0.57	0.25
Treatment satisfaction VAS*	59.2	---	---	---	---	1	0.21	0.32	0.27
UCLA activity score*	20.4	---	---	---	---	---	---	1	0.38

*Mean

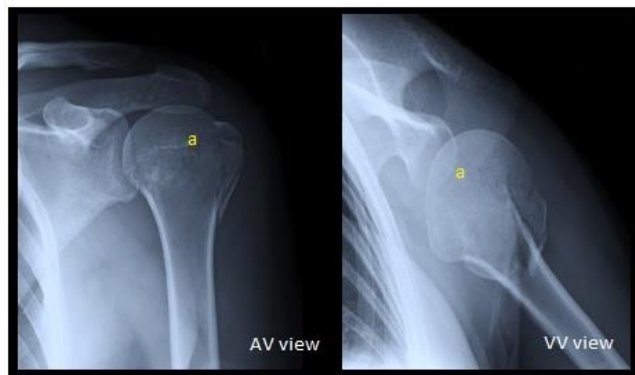


Fig. 1: X-ray imaging showing improvement in PHF post 1 year (humeral head)

DISCUSSION

Non-operative treatment for PHF is known for significant association with the variation in functioning of shoulder as a general perception by health sector during one year.¹¹ In various research articles satisfactory outcomes with this technique has been reported with normal scoring achievement, On the contrary there is still available data on a few patients having poor or average satisfactory outcomes. The strongest predictors of success of the treatment plan in PHF were dependency level, social deprivation-score and disorder history.¹²⁻¹⁴ It accounted for almost 37-43 percent of alterations in all of the multivariate analysis performed. Studies have suggested that prediction values about success of non-operative treatment of PHF can be made at the time of case presentation by examining the injury.¹⁵

The present study has also found that fracture related factors were not as that common as were psychosocial. In cases

outcomes it was noticed that mean outcomes score of treatment was 32.1 while VAS pain score was 32.1 with 59.2 as VAS satisfaction score. The mean one-year VAS health score was 68 and UCLA activity score as 20.4 which was lower than the one before injury (Table 3).

Table 2: Descriptive statistics of hospital admission post-injury

Variable	Values (n=50)	OSS	EQ-5D-3L	P value
Hospital admission post injury	44 (88%)	34.2	0.62	<0.001
Fracture related complications				
Neck fracture	13 (26%)	34.0	0.6	<0.001
Tuberosity	15 (30%)	27.3	0.45	<0.001
Head shaft translation (Mean)	16.7	-0.34	-0.34	<0.001
Head shaft distraction>1cm	7 (14%)	33.6	0.6	0.7
Operative treatment post 1 year complication	2 (4%)	18.2	0.08	<0.001

around 10 percent non union and complication with PHF were reported in present study.¹⁶ Similar has also been reported in another study with 10.2% post one year complication documentation and 58.2% those who reported scoring as worse than death.¹⁷ It is important to note that despite of negative scoring still only a few patients undergo surgical operation after a one-year non-operative treatment protocol for proximal humeral fracture highlighting the efficiency of this procedure.¹⁸

Displaced tuberosity-fractures were another variable which was associated with worse scoring and predicting around one to four percent disparity in primary as well as secondary analysis. In cases where humeral head, osteonecrosis was seen the worst outcomes were predictive.¹⁹ However, such cases were rare to report. Patients having OSS score near 47 points were reported of ceiling effect. This effect was more evidently seen in younger adults than older adults with poorer patient reported outcome measures.²⁰

CONCLUSION

Non-operative treatment for proximal humeral fracture in adults results in significant changes in shoulder-specific as well as health improved outcomes after one year. Psychological factor also plays a major role in providing betterment scores.

REFERENCES

1. Clement ND, McQueen MM, Court-Brown CM. Social deprivation influences the epidemiology and outcome of proximal humeral fractures in adults for a defined urban population of Scotland. *Eur J Orthop Surg Traumatol* 2014; 24(7):1039-46.
2. Jayakumar P, Teunis T, Williams M, Lamb SE, Ring D, Gwilym S. Factors associated with the magnitude of limitations during recovery from a fracture of the proximal humerus: predictors of limitations after proximal humerus fracture. *Bone Joint J* 2019;101-B(6):715-23.

3. Goudie EB, Robinson CM. Prediction of nonunion after nonoperative treatment of a proximal humeral fracture. *J Bone Joint Surg Am* 2021;103(8):668-80.
4. Neer CS 2nd. Displaced proximal humeral fractures: part I. Classification and evaluation. 1970. *Clin Orthop Relat Res* 2006;442:77-82.
5. Majed A, Macleod I, Bull AMJ, Zyto K, Resch H, Hertel R, et al. Proximal humeral fracture classification systems revisited. *J Shoulder Elbow Surg* 2011;20(7):1125-32.
6. Resch H, Tauber M, Neviasser RJ, Neviasser AS, Majed A, Halsey T, Hirzinger C, Al-Yassari G, Zyto K, Moroder P. Classification of proximal humeral fractures based on apathomorphologic analysis. *J Shoulder Elbow Surg* 2016; 25(3):455-62.
7. Marsh JL, Slongo TF, Agel J, Broderick JS, Creevey W, DeCoster TA, et al. Fracture and dislocation classification compendium - 2007: Orthopaedic Trauma Association classification, database and outcomes committee. *J Orthop Trauma* 2007;21(10)(Suppl):S1-133.
8. Court-Brown CM, Garg A, McQueen MM. The translated two-part fracture of the proximal humerus. Epidemiology and outcome in the older patient. *J Bone Joint Surg Br* 2001; 83(6):799-804.
9. Gaebler C, McQueen MM, Court-Brown CM. Minimally displaced proximal humeral fractures: epidemiology and outcome in 507 cases. *Acta Orthop Scand* 2003;74(5):580-5.
10. Hanson B, Neidenbach P, de Boer P, Stengel D. Functional outcomes after nonoperative management of fractures of the proximal humerus. *J Shoulder Elbow Surg* 2009; 18(4):612-21.
11. Dawson J, Fitzpatrick R, Carr A. Questionnaire on the perceptions of patients about shoulder surgery. *J Bone Joint Surg Br* 1996;78(4):593-600.
12. Rangan A, Handoll H, Brealey S, Jefferson L, Keding A, Martin BC, et al. Surgical vs nonsurgical treatment of adults with displaced fractures of the proximal humerus: the PROFHER randomized clinical trial. *JAMA* 2015;313(10):1037-47.
13. Caliskan E, Doğan Ö. PHILoS plate versus nonoperative treatment in 2-, 3-, and 4-part proximal humeral fractures: Comparison with healthy control subjects. *J Orthop Surg (Hong Kong)* 2019;27(3):2309499019875169.
14. Lopiz Y, Alcoba-Diaz B, Gal'an-Oliveros M, Garcia-Fernandez C, Picado AL, Marco F. Reverse shoulder arthroplasty versus nonoperative treatment for 3- or 4-part proximal humeral fractures in elderly patients: a prospective randomized controlled trial. *J Shoulder Elbow Surg* 2019;28(12):2259-71.
15. Kristiansen B, Angermann P, Larsen TK. Functional results following fractures of the proximal humerus. A controlled clinical study comparing two periods of immobilization. *Arch Orthop Trauma Surg* 1989;108(6):339-41.
16. Launonen AP, Sumrein IO, Reito A, Lepola V, Paloneva J, Jonsson KB, et al. Operative versus non-operative treatment for 2-part proximal humerus fracture: a multicenter randomized controlled trial. *PLoS Med* 2019; 16(7):e1002855.
17. Zyto K. Non-operative treatment of comminuted fractures of the proximal humerus in elderly patients. *Injury* 1998;29(5):349-52.
18. Court-Brown CM, Cattermole H, McQueen MM. Impacted valgus fractures (B1.1) of the proximal humerus: the results of non-operative treatment. *J Bone Joint Surg Br* 2002;84(4):504-8.
19. Clement ND, Duckworth AD, McQueen MM, Court-Brown CM. The outcome of proximal humeral fractures in the elderly: predictors of mortality and function. *Bone Joint J* 2014;96-B(7):970-7.
20. Foruria AM, de Gracia MM, Larson DR, Munuera L, Sanchez-Sotelo J. The pattern of the fracture and displacement of the fragments predict the outcome in proximal humeral fractures. *J Bone Joint Surg Br* 2011;93(3):378-86.