

ORIGINAL ARTICLE

Molecular Identification of two Isolates of *Nannizia Fulva* Causing Tinea Capitis in Iraq

SAZAN J. GHARIB^{1,2}, DELVEEN R. IBRAHIM³, SAMIR K .ABDULLAH⁴¹Medical Laboratory Department, Sulaimani Technical Institute, Poly technique University, Kurdistan Region-Iraq²Biology department, Faculty of Science, University of Zakho, Kurdistan Region-Iraq³Department of Biology, College of Science, Duhok University, Kurdistan region Iraq⁴Medical Laboratory Techniques Department, Alnoor University College, Bartella, Nineva, IraqCorrespondence to: Samir K .Abdullah, Email: samir.abdullah@alnoor.edu.iq, Cell: +9647704574841

Abstract

Background: Tinea capitis is a clinical form of superficial fungal infection of the scalp and caused by filamentous fungi known as dermatophytes

Methods and Materials: Hairs and skin scrapings of scalp showing ringworm infection were collected from the affected regions and were subjected to direct microscopic examination and isolation on culture media. Identification of the causal agent was based on molecular analysis of ITS-rDNA region.

Results: The present study reported two cases of dermatophyte infection of tinea capitis (scalp ringworm) caused by *Nannizia fulva*. The causal agent was isolated in two occasions from ringworm lesions on scalp of 8 years old girl and 10 years boy from Zakho refuge camp school

Conclusion: *Nannizia fulva* is recorded for the first time as etiologic agent of tinea capitis in Iraq.

Keywords: *Nannizzia fulva*, *Tinia capitis*, Dermatophytosis, ITS region, Iraq.

INTRODUCTION

Dermatophytes are keratinolytic filamentous fungi that infect the superficial epidermal layer of the skin as well as hairs and nails and caused dermatophytosis¹. Dermatophytosis is a prevalent public health problem in the majority of the countries²⁻⁴. Tinea capitis (TC) is a clinical form of superficial fungal infection of the scalp, eyebrows and eyelashes that is most common in school-aged children⁵⁻⁷. Tinea capitis is often caused by anthropophilic or zoophilic dermatophytes mostly assigned to the genera *Trichophyton* and *Microsporum*⁸⁻¹⁰ and rarely to the geophilic *Nannizzia* species¹¹⁻¹³.

The incidence and distribution of tinea capitis as well as its causative agents differs according to geographic regions^{9,14-15}. In Iraq, tinea capitis infections have appeared as the second most common disease after tinea corporis as encountered by several investigations on dermatophytosis¹⁶⁻¹⁸. During our survey on the incidence of dermatophytosis in Kurdistan region, North Iraq, we encountered two cases of tinea capitis on school children from a refugees camp at Zakho city. Isolation and identification of the causal agent, revealed *Nannizzia fulva* as confirmed by sequencing of ITS region of rDNA.

MATERIALS AND METHODS

Specimens collection: Samples were collected from primary school children at Zakho refuge camp, Kurdistan region of Iraq suspected to have been infected with ringworm during October 2017. Skin scrapings and hair fragments of scalp were collected from the affected lesions after proper sterilization with 70% alcohol (Figure 1 a and b). Sufficient amount of specimens were taken from the edge of the lesion using a number 15 sterile surgical blade and were transported in folded paper envelope to the laboratory for direct microscopic examination and isolation on culture media¹⁹.

Direct microscopic examination: Part of the specimen was observed through direct microscopic examination by mounting in 20% potassium hydroxide (KOH) solution

(Merck, Germany). Then viewed under the light microscope (CX 40 Olympus USA) to look for fungal structures (Arthrospore or hyphae)¹⁹.

Primary isolation and culture on specific media: Second portion of the specimen was inoculated into Sabouraud Dextrose Agar (SDA) (CM41; Oxoid, UK) which supplemented with chloramphenicol (0.05%) (RS78; Oxoid, UK) to suppress any bacterial growth. Mycogel agar (Sigma-Aldrich, St. Louis, MO, USA) were used as well as, the medium was supplemented with both chloramphenicol (0.05%) and cycloheximide (0.05%) to inhibit the growth of environmental saprophytic fungi as appropriate¹⁹. Inoculated plates were incubated at 25°C for at least 3-4 weeks and examined periodically (twice a week) for existence of dermatophyte growth. Primary isolation and diagnosis of each species was based on phenotypic characteristics (Macroscopic and Microscopic feature of the colonies). Diagnosed species of dermatophyte isolates were subcultured in a new agar slant of SDA and maintained for further examination by molecular identification.

Molecular methods: Genomic DNA was extracted and purified by taking a proper amount of sample from a fresh colony (21 day-old, grown on SDA dishes). This performed by grinding in presence of liquid nitrogen for initial breaking up of mycelia. Total DNA isolation of fungi achieved using molecular biology kit; EZ-10 Spin Column Fungal Genomic DNA Mini-preps Kit (BIO BASIC INC., Canada) according to the instruction recommended by the manufacturer. The quantity, quality and the detection of genomic DNA were done by using gel electrophoresis and Nano drop UV spectrophotometer (Thermo Scientific, USA) at 260\280 nm. 6µL of the fungal DNA sample was mixed with 1µL of loading dye and loaded in the agarose gel (1.5%), run at 90 volts for 45 min. Then the gel was examined by gel image desktop to see the DNA bands and visualized under Ultraviolet Trans illumination (Sangabriel, UK)²⁰. Amplification of Internal transcribed spacers (ITS) was performed using primers ITS1 (5'-

TCCGTAGGTGAACCTGCGG-3') and ITS4 (5'-TCCTCCGCTTATTGATATGC-3') according to ²¹. The primers obtained from (MWG-Biotech AG ,Germany). The PCR mixture contained 10µl of ready to use prime Taq DNA polymerase master mix (2X) (Bioneer,Korea), 1-2µl of each primer (10pmol⁻¹), 2-3µl of DNA template (50 ngl⁻¹), and deionized water was added to made up the total volume of the mixture to 25µl. Amplification was performed on a thermocycler (Bioneer,Korea), using the following conditions: An initial denaturation set up at 94°C for 5 min. followed by 35 cycles of denaturation at 94°C for 30 sec. , annealing at 58°C for 1 min. and extension at 72°C for 1 min. ,with a final extension step of 72°C for 10 min.

Gel electrophoresis: The PCR products were visualised by electrophoresing 10µl of amplicons in 1.5% (w/v) agarose gel in TBE buffer (90mM Tris,90mM boric acid ,2mM EDTA ,pH 8.3) , stained with ethidium bromide and supplied to the power at 75 volts for 60 min. The gel visualized under computerized UV trans-illuminator and photographed. A 100bp DNA Marker was used as a reference to determine the fragments size.

Sequencing, phylogenetic tree construction and identification of isolated fungi: The ITS region on rDNA gene was amplified using ITS 1 and ITS 4 primers which resulted in PCR product size ranked between (444 and 555) bp for *Nannizzia fulva* . The PCR productus were sequenced by Macrogen company, South Korea. Sequence a alignment and checking of the obtained query sequences was conducted using BioEdit sequence alignment Editor 7.0.5.3 (<http://www.mbio.nesu.edu/Bio.edit/bioedit.html>).

For final identification,the obtained consensus of query sequences was compared with ITS DNA database (<https://blast.ncbi.nlm.nih.gov/Blast.cgi>.BLAST search (basic local alignment search tool) on the BLAST homepage,NCBI,Bethesda,USA to define the identity of the fungal strain and to find regions of local similarity between the sequences. The sequences of the current study were deposited in GenBank and accession numbers were recieved(MK112625 and MK112626). Sequencing of different amplicons were aligned using ClustalW MEGA7 software was used to determine genetic distance between the studied fungal isolates ,and a phylogenetic tree was reconstructed by the neighbor-joining method and the alignment were used to phylogened analysis using MEGA software version X.

RESULTS

Primary isolation and culture: Direct microscopic examination from the two scalp samples was positive showing hyaline hyphae typical for dermatophytes. Based on culture examination, isolates from the two samples were purified showing pinkish-buf fast growing colony at 25°C on SDA (Fig.2).

Sequencing and phylogenetic analysis: The ITS region on rDNA was amplified by using universal primers ITS1 and ITS4 which yielded in PCR product size ranged approximately between 444 and 555bp in *N. fulva* . Phylogenetic analyses of the ITS region of this study were compared with the dataset of different countries isolates originated from different sources .

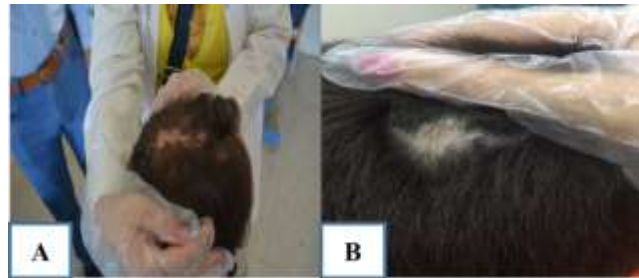

Fig 1: (A) Symptoms of ringworm of scalp on 8-years old girl. (B) on 10-years old boy



Fig 2: *Nannizzia fulva* culture showing pinkish-buff in colour

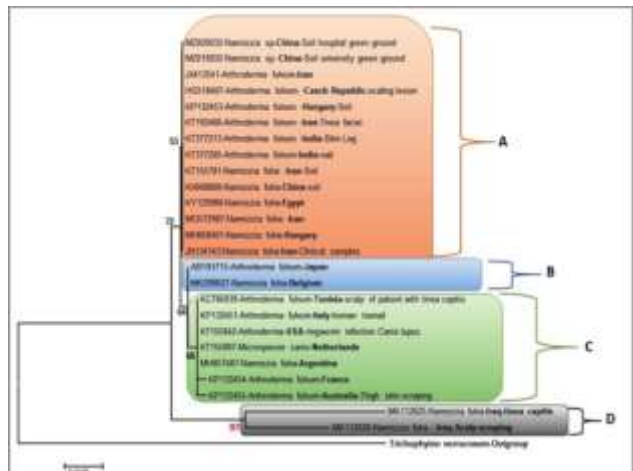


Figure 3: The represented phylogenetic tree of 25 ITS sequences using the Neighbor-Joining method . The percentage of replicate trees in which the associated taxa clustered together in the bootstrap test (1000 replicates) are shown next to the branches. The evolutionary distances were computed using the Jukes-Cantor method by MEGA 7.

Table 1: The sequence similarity of this study strains with other countries and Isolated sources .

No .	Accession No.	Location (country)	Isolation source	Identity
1.	MK112625	Iraq (This Study)	scalp scraping (tinea capitis)	100%
2.	MK112626	Iraq (This Study)	Scalp scraping	95
3.	MH858401	Hungary		96
4.	MG572987	Iran		96
5.	KY129988	Egypt		96
6.	KX668868	China	soil	96
7.	KT155781	Iran	soil	96
8.	KT377205	India	nail	96
9.	KT377213	India	Skin of leg	96
10.	KT192466	Iran	Tinea faciei	96
11.	KP132453	Hungary	soil	96
12.	HG518407	Prague, Czech Republic	scaling lesion	96
13.	JX413541	Iran		96
14.	MZ020032	China	Soil, hospital green ground	96
15.	MZ019932	China	Soil, university green ground	96
16.	JN134143	Iran	Clinical samples	95
17.	KP132454	France	Clinical and veterinary samples	95
18.	KP132455	Australia	Thigh skin scraping	95
19.	KC784939	Tunisia	scalp of patient with tinea capitis	95
20.	KP132451	Italy	human toe nail	95
21.	KT155842	USA	ringworm infection; Canis lupus	95
22.	KT155887	Netherlands	Homo sapiens	95
23.	MH857487	Argentina		95
24.	AB193715	Japan		95
25.	MK298627	Belgium		95
26.	MK156725	outgroup		87

The isolates of these study are forming their own cluster in a group named by Clad D as type species *Nannizzia fulva* (MK112625 and MK112626), with the bootstrap support (97%) (Figure3). The sister cluster to this is Clade C which grouped different strains together including *Arthroderma fulvum* from following (Tunisia-scalp, Italy-human toenail, USA-ringworm infection *Canis lupus*, France and Australia-Thigh skin scraping), in addition to the *Microsporum canis*-Netherlands with the bootstrap support (66%). Clad A comprised only *Nannizzia fulva* – From different countries and different sources as show in (Figure 3 and Table1) with lower bootstrap (53%). The bootstrap -supported node (72%) is the basal to the Clad A, B and C. All branches between clades had a low bootstrap support values but no less than 50%, except for Clade D which high 97%. *Trichophyton verrucosum* used as an outgroup.

The identity matrices of the ITS sequences of this study compared with different geographical areas ITS sequences and are summarised in (Table1). Twenty four pairwise comparisons for ITS sequences were applied, BLAST search tool was used, to the sequence homology between the study isolates and others. Based on this *Nannizzia fulva* (MK112625, Iraq strain) showed that the

obtained sequences shares 96% homology to *Nannizzia fulva* strains from: Hungary (MH858401 and KP132453), Iran (MG572987, KT192466, KT155781, JX413541 and JN134143), Egypt (KY129988), China (KX668868, MZ020032 and MZ019932), India (KT377205 and KT377205), Prague, Czech Republic (HG518407) (Table 1). While, the same sequence gives the similarity of (95%) with following; Iraqi isolate (MK_112626), Netherland (KT155887), Iranian (KT155887), France (KP132454), Australia (KP132455), Tunisia (KC784939), Italy (KP132451), USA (KT155842), Argentina (MH857487), Japan (AB193715) and Belgium (MK298627) (Table 1).

DISCUSSION

Dermatophytes are very common infection of human and animals with wide spectrum of clinical manifestations ^{2,22} . Dermatophyte identification based on phenotypic and physiological methods is time-consuming and mostly has led to misdiagnosis due to the high degree of phenotypic similarities among relative species . Therefore, accurate identification of dermatophyte at the species level is essential due to therapeutic and epidemiological importance ²³⁻²⁵ . In current study, the two cases were found in patients aged ≤ 10 years, and this was in accordance with the results obtained by several studies ^{6-7,26-28} . Nevertheless, TC was recorded as the second most prevalent type of dermatophytosis in Iraq as revealed by several studies ¹⁶⁻¹⁸ .

The etiology and incidence of TC differs in various parts of the world ^{3,8,29} . Previous studies on diagnosis of tinea capitis in Iraq were mostly based on clinical features and phenotypic characteristics of the isolated causal pathogen. Our diagnosis of the two isolates was confirmed by the molecular analysis of ITS region of fungal ribosomal DNA. Studies on the etiology and incidence of TC in Iraq revealed different results. However, species of genus *Trichophyton* such as *T.violaceum*, *T.mentogrophytes*, *T.verrucosum* and *T.tonsurans* were the mostly reported as responsible for infections of the scalp ³⁰⁻³⁵ and to less extent *T.audouinii* ^{34,36} . *Nannizzia fulva* formerly (*Microsporum fulvum*) is a geophilic dermatophyte of worldwide distribution, rarely encountered as etiologic agent of tinea infection in humans and animals ³⁷ . The reason for the scanty of tinea reports on *N.fulva* (=M.fulvum) as etiologic agent of infections is probably due to misdiagnosis of *M.fulvum* with *M.gypseum* that mostly based on conventional methods. In recent investigation, molecular approach was employed to confirm the identification of the *M. fulvum* strains isolated from Iranian patient with tinea corporis and identified formerly as *M.gypseum* by culture and classical methods ³⁸ . In previous studies in Iraq , *N. fulva* was not recorded as etiologic agent of tinea capitis in our country.

CONCLUSION

Nannizzia fulva is newly recorded as causal agent of tinea capitis in Iraq. It seems that there is an epidemiological change regarding the etiological agents of tinea capitis in our region and currently *N. fulva* may represents important causal agent of TC particularly in Kurdistan Region, Iraq. Sequences of ITS rDNA as a general phylogenetic marker

succeeded to distinguish *N.fulva* from closely related species.

REFERENCES

- 1 Gupta AK and Tu LQ. Dermatophytes: Diagnosis and treatment. *Journal of the American Academy of Dermatology* 2006; 54(6):1050-1055. doi.org/10.1016/j.jaad.2006-01-016
- 2 Walsh TJ and Groll AH . Emerging fungal pathogens: evolving challenges to immunocompromised patients for the twenty-first century. *Transpl Infect Dis.* 1999;1:247–261.
- 3 Zhan P , Liu W . The changing face of dermatophytic infections worldwide. *Mycopathologia* 2017;182:77-86.
- 4 AL-Khikani FHO. Dermatophytosis a worldwide contiguous fungal infection: Growing challenge and few solutions. *Biomed.Biotechnol.Res.J.* 2021;4:117-122.
- 5 Degreef H . Clinical forms of Dermatophytosis (Ringworm Infection). *Mycopathologia* 2008;166:257-265.DOI 10.1007/s11046-008-9101-8
- 6 Ahmed AS, Ahmed MAI, Abdelrahma NAM , Adam NKA , Abdel-Aziz DS and Ahmed NBM. Prevalence of tinea capitis among school age children in eastern Sudan. *J.Bacteriol.Mycol Open Access* 2021;9(2):94-97.
- 7 Kassem R, Shemesh Y, Nitzan O, Azrad M and Peretz A . Tinea capitis in an immigrant pediatric community; a clinical signs-based treatment approach. *BMC Pediatrics.* 2021;21:363. Doi.org/10.1186/s12887-021-02813-x
- 8 Hay RJ. Tinea capitis: current status. *Mycopathologia* 2017; 182:87-93. DOI 10.1007/s11046-016-0058-8
- 9 Leung AKC, Hon KL, Leong KF, Barankin B and Lam JM. Tinea capitis :An updated review . *Recent Patents on Inflammation & Allergy Discovery.* 2020;14:58-68.
- 10 Yang Z., Chen W., Wan W., Song Y., Li R. Tinea capitis by *Microsporum canis* in an elderly female with extensive dermatophytes infection. *Mycopathologia* 2021;186:299-305 https://doi.org/10.1007/s11046-020-00519-9
- 11 Faway EC, Lambert de Rouvroit and Poumay Y . In vitro models of dermatophyte infection to investigate epidermal barrier alterations. *Exp Dermatol.* 2018;27:915–922. https://doi.org/10.1111/exd.13726
- 12 Cruciani D, Papini M, Broccatelli S, Agnetti F, Spina S, Natalini Y and Crotti S . Presumptive Zoonotic Kerion by *Nannizzia gypsea*: Case Report. *Front. Vet. Sci.* 2021; 8:718766. doi: 10.3389/fvets.2021.718766
- 13 Gomez-Moyanoa E, Gasca-Santianb M, Andamoyo-Castaneda Land Martinez-Pilara . Tinea capitis caused by *Nannizza gypsea* after playing by a river. *Revista Iberoamericana de Micologia.* 2021;DOI:10.1016/j.riam.2020.12.003
- 14 Sidat MM., Correia D and Buene TP. Tinea capitis among children at one suburban primary school in the city of Maputo, Mozambique. *Rev Soc Bras Med Trop* 2007; 40:473–475.
- 15 Pérez-González M., Torres-Rodríguez JM , Martínez-Roig A, Segura S, Grieria, G and Triviño L, et al. Prevalence of tinea pedis, tinea unguium of toenails and tinea capitis in school children from Barcelona. *Revista Iberoamericana de Micologia.* 2009;26:228–232.
- 16 Al-Kayalli KKB, Razzoqi M and Hussan WH. The rate of superficial infections among patients with different skin diseases in Diyala. *Iraqi J Comm.Med* 2011;24(3),264-266.
- 17 Najem MH, Al-Salih M.H and Hamim SS .Study of dermatophytosis prevalence in Al-Nassiriyah city. *Iraq. World J Pharm Sci* 2016 ; 4(4): 166-172.
- 18 Kadhim OH. The incidence of dermatophytosis in Babylon Province, Iraq. *Med.J.Babylon* 2018; 15:234-237.
- 19 Kane J and Summerbell RC . 'Dermatological mycology: examination of skin, nails, and hair', in: *Laboratory handbook of dermatophytes. A clinical guide and laboratory manual of dermatophytes and other filamentous fungi from skin, hair and nails.* Ed .J .Kane J., RC. Summerbell, L.Sigler. Star Publishing Company, Belmont. 1977. pp33–44.
- 20 Corley, R.B. A guide to methods in the biomedical sciences. Springer-science Inc. New York 2005.
- 21 White T J, Bruns T, Lee S and Taylor J . Amplification and direct sequencing of fungal ribosomal RNA genes for phylogenetics. In: *PCR Protocols*, eds. MA Innis, D. H. Gelfand, J. J. Sninsky, T. White . Academic Press, San Diego, 1990. pp. 315–322.
- 22 Ghannoum MN, Isham R, Hajjeh, et al. Tinea capitis in Cleveland: survey of elementary school students. *J Am Acad Dermatol* 2003; 48:189–193.
- 23 Graser Y, Scott J and Summerbell RC. The New Species Concept in Dermatophytes-A Polyphasic Approach. *Mycopathologia* 2008;166(5- 6):239-256.
- 24 Rezaei-Matehkolaei K. , Makimura M, Shidfar F, Zaini M, Eshraghian N and Jalalizand et al. Use of single-enzyme PCR-restriction digestion barcode targeting the internal transcribed spacers (ITS rDNA) to identify dermatophyte species . *Iran J Public Health* 2012;41: 82-94.
- 25 de Hoog GS, Dukik K, Monod MA, Packeu D, Stubbe M, Hendrickx, et al. Toward a novel multilocus phylogenetic taxonomy for the dermatophytes . *Mycopathologia* 2017 ;182 : 5-31.
- 26 Nweze EI and Okafor JI. Prevalence of dermatophytic fungal infections in children: a recent study in Anambra state, Nigeria. *Mycopathologia* 2005;160: 239–243.
- 27 Al-Samarai AGM. Tinea capitis among Iraqi Children: Public Health Implication. *Journal of Clinical and Diagnostic Research* 2007;1(6):476-482.
- 28 Aktas E, Kavakuzu A and Yigit N. Tinea Capitis the most common Dermatophytes. *Stanbul, Turkey. Mycoses* 2009;22(2): 115-118.
- 29 Ginter- Hanselmayer G, Weger W, Ilkit M and Smolle J . Epidemiology of tinea capitis in Europe: current state and changing patterns. *Mycoses* 2007;50(S2):6-13.
- 30 Akrawi, F and Rassam KH. Species of fungi which cause ringworm of the scalp in Iraq with a study of the action of griseofulvin on the in vitro. *Journal of the Faculty of Medicine, Baghdad* 1962;4 (1):23-5.
- 31 Rahim, GF A. Survey of fungi causing tinea capitis in Iraq . *British Journal of Dermatology* 1966;78 (4) : 213-8.
- 32 Shaikh Gumar, AW and Guirges SY. Survey of etiologic agents of fungal infections of the skin. *Journal of the Faculty of Medicine, Baghdad* 1978;20:19-29.
- 33 Al-Mosawi T., AL-Affas NH and Al-Ramahyi, AK. The incidence of scalp fungal infection among primary pupil in Bassra city. *Iraqi J Comm.Med* 1993;6 (1) : 31-6.
- 34 Al-Duboon AH, Muhsin TM and Al-Rubaiy KK . Tinea capitis in Basrah, Iraq. *Mycoses* 1999;42(4):331-333.
- 35 Fathi H.I, Al-Samarai AG. Prevalence of tinea capitis among schoolchildren in Iraq. *East Mediterr Health J* 2000;6:128–137.
- 36 Junaid A.J and Rassam KH .1974. Species of fungi causing dermatomycosis in Iraq. *Iraqi medical Journal.* 22:38-40.
- 37 Kidd S, Halliday C, Alexiou H and Ellis D .2016. *Descriptions of Medical Fungi.* 3rd edit. Newstyle Printing, Australia.
- 38 Nouripour-Sisakht S, Rezaei-Matehkolaei A, Abastabar MMJ, Najafzadeh K, Satoh B and Ahmadi, et.al. . *Microsporum fulvum*, an ignored pathogenic dermatophyte: a new clinical isolation from Iran. *Mycopathologia* 2013;176:157-160.