DOI: https://doi.org/10.53350/pjmhs22161543

CASE REPORT

Living an Active Life with the Help of Physical Therapy Intervention after Being Diagnosed with Oligodendroglioma: a Case Report

NABEEHA ASIF[1], SIDRA SOHAIL[2]
[1]*Senior Lecturer, Jinnah College of Rehabilitation Sciences, Karachi*
[2]*Lecturer, Jinnah College of Rehabilitation Sciences, Karachi*
Corresponding author: Nabeeha Asif, Email: Nabeehaasif1973@gmail.com, Cell: 0301 5186067

ABSTRACT
Oligodendroglioma is a tumor found in the central nervous system, known for its impact on the patient's overall well-being. This case study is an exceptional case in which the patient has been able to maintain a well-balanced active life after being diagnosed with oligodendroglioma, with the help of physical therapy interventions. The patient was diagnosed with Grade II Oligodendroglioma in 2016 after reporting symptoms including frequent headaches, problems with balance and movement, extreme weakness, even inability to stand. The symptoms eventually led to epileptic seizures which resulted in paresis and numbness in the left side of her body. The tumor was partially removed with the help of surgery, and the remaining tumor was treated with the help of chemotherapy, radiation, and medications. However, physical therapy played a vital part in helping to minimize the impact of heavy doses of medication and to stay active and not lose strength in the left side of her body. The aim of this case study was to publish the impact of physical therapy interventions in leading an active lifestyle after being diagnosed with Oligodendroglioma. This unique case will contribute to all the fields of science that are studying the brain and understanding how it works, cancers especially brain tumors or Oligodendroglioma, and physical therapy. It will also pave the way for further research.
Keywords: Oligodendroglioma, physical therapy, paresis, case report.

INTRODUCTION
Oligodendroglioma is a rare kind of brain cancer that is developed by the cell populations that give rise to oligodendrocytes [1]. They are most commonly found in the frontal lobe and often involve cortical gray matter. This form of cancer accounts for about 4.9% of the malignant adult brain cancers and has an incidence rate of 1 to 2 cases per million each year [2]. It has a slightly greater number of cases in males than females with a ratio reported of 1.1 to 2 [3]. WHO has further stratified Oligodendroglioma on the basis of its histological appearance into Grade II and Grade III [4]. The grade II Oligodendroglioma neoplasms are slow-growing tumors that have a favorable treatment as compared to the other gliomas. Furthermore, the grade III anaplastic oligodendroglioma is a more malignant form of the tumor that is less likely to be treated [5]. However, due to their rarity, they are often classified as the same.

In the majority of brain tumor populations, the current treatment options are not curative. This means that there is no cure for a brain tumor, and it can only be controlled with the help of medications or medical procedures other than surgery. The medical teams primarily focus on prolonging the survival of the patient along with maintaining or improving their quality of life. Since brain tumors are likely to grow back even after being surgically removed or are sometimes only partially removed to avoid severing parts of the brain, the patient is required to make lifestyle changes, frequent check-ups, and perhaps continue taking the medicines in order to stay healthy. This is especially crucial for patients with brain tumors such as Oligodendroglioma that have longer expected survival. The maintenance of the quality of life is a multidimensional construct that covers most life domains including psychological, physical, and social as well as the symptoms that are induced by the tumor and its treatment.

Patient information: The patient is a 48-year-old female belonging to an Islamic ethnicity. According to the latest follow-up, her weight was 52 kgs and height of 5 feet 7 inches.

Primary concerns and symptoms of the patient: The primary concern of the patient was the continuous growing headaches and pains in the left side of her body. She felt that the left side of her body was numb which would cause hindrance in movement and balance as well. After five years, the feeling of fainting, severe cramps in the stomach made it hard to stand and swelling around the face and eyes developed which compelled the patient to consult a doctor.

Medical, family, and psychosocial history including relevant genetic information: The patient has had no history of diabetes or blood pressure until the diagnosis. However, there were two cases of liver sclerosis and one case of brain tumor (not specified) in the maternal family of the patient.

Relevant past interventions and their outcomes: The patient started having symptoms eleven years ago when she started having frequent headaches. She was six years later diagnosed with Oligodendroglioma (Grade II). However, the episodes of headaches were fewer in the early years and would disappear when the patient took painkillers which included Panadol, Neborol Forte, Brufen, Nepadoc. As time passed by, the frequency of the headaches got more severe and frequent, and the painkiller tablets did not give her relief anymore. Eventually, a physician suggested the patient start the use of pain killer injections namely Dicloran and Voren, once a day for the relief of headaches.

Clinical Findings: As the symptoms started to get worse, the patient decided to get her CT scan done, from which a membranous spot was detected in the left side of the frontal lobe. An MRI was conducted to further investigate the findings from the CT Scan and Oligodendroglioma was diagnosed. The tumor was diagnosed with 1p_ 19Q gene deletion This rare form of tumor is known to develop due to

chromosome abnormality. Due to its rarity, the treatment options were limited and the surgical removal of the tumor may have resulted in many side effects. The location of the tumor was the main cause of concern for the surgeon as it was located deep in the primary motor cortex of the frontal lobe. The patient was made aware that removing the tumor may result in the left side of the body being completely paralyzed or difficulties in coordination and speaking.

Timeline

DATE	EVENT
Month / 2010	● The patient started to experience frequent headaches that eventually grew in intensity. ● For some time she used over the counter medication such as Panadol, Nuberol Forte, Brufen, and Nepadoc to treat the pain. ● When the pain became unbearable she was prescribed Dicloran and Voren injections, once a day.
CT - 11th March 2016 MRI - 17th March 2016	● The patient visited the doctor who referred her for a CT Scan and MRI. ● CT scan detected a membranous spot on the left side of the frontal lobe which later turned out to be a tumor  ● MRI was conducted. The tumor was located deep in the motor cortex of the frontal lobe. ● The patient was diagnosed with Grade II Oligodendroglioma. ● The tumor was diagnosed with 1p_ 19Q gene deletion.
27th July 2016	● A biopsy was performed to further investigate the nature of the tumor. Its results revealed that only 20 percent of the tumor can be removed surgically and the remaining 80 percent of it would have to be treated with radiation and chemotherapy to reduce the risks of the surgery. 
17th October 2016	● The surgery was performed and the patient was advised to start radiation therapy and chemotherapy after recovering from the surgery.
25th October 2016	● The patient began I.M.R.T intensity-modulated radiation therapy of 90 Gy and chemotherapy through tablets, Temozolomide (120 mg) which lasted for 33 days.
25th December 2016 to 25th May 2017	● After a month's break, chemotherapy was resumed and lasted for 6 months, and was administered 5 times a month. Monthly checkups were also performed to track the patient's health.
17th June 2017	● After 7 months, an MRI was conducted which revealed that the tumor was still present. The patient was advised to

	continue the chemotherapy sessions to shrink the tumor. However, she refused to continue it and was asked to sign a consent form for the same. ● The patient was prescribed multiple medicines of high dosages to keep her health stable. 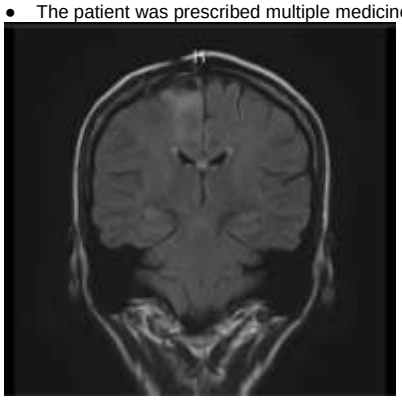
Onward 2018	● Due to the high dosage of medicines, the patient started to experience extreme lethargy and weakness along with vomiting. ● She also started to experience frequent headaches accompanied by epileptic seizures. She was prescribed 500 mg Lerace thrice a day for her epileptic seizures. ● The patient missed some doses which led to an epileptic seizure that caused paresis and numbness in the left side of her body. ● There was also a tingling sensation on the left side of the whole body including the face and neck. She was prescribed 50 mg of Zeegab thrice a day for pain and numbness due to paralysis. ● The patient feels as someone is cutting her extremities with axe. ● With time the dose increases up to 150 mg, thrice a day. ● The medicines resulted in her feeling more lethargic, sleepy, and restless.
July 2018	● The patient decided to reduce the dosage of some medication and began to introduce physical therapy interventions in her daily routine. ● She slowly tapered off her medications to an amount that allowed her to stay active and perform daily tasks while reducing the side effects of the same. ● The only medication whose dosage has not been changed is the 500 mg Lerace which needs to be taken in the prescribed quantity and frequency.
Onward 2019	● The patient began to make lifestyle changes with the help of physical therapy interventions. She started by taking physical therapy where she was advised to start with basic static stretches to not strain her muscles. These stretches were designed to help her regain the lost strength and elasticity of the muscles including hamstrings, rectus femoris, quadriceps, pectoralis majors, neck extensors, and spine extensors. ● The exercises were such that it was not necessary for the patient to acquire equipment and could be done by the patient without any external support.
Onward 2019	● With time, the patient began to sleep in a position that would stretch her muscles and reduce muscle soreness. ● However, she still experiences pain on the left side of the body, especially her left hand. She uses compression bandages for the pain along with the medication.
Onward 2020	● The patient also began balance training exercises at home with the help of objects easily accessible to the client. She would use the kitchen counter and dining table as support to shift weight on the affected side of the body. ● In addition, the patient also alternated between sitting and standing motions to make sure that she is not putting excessive pressure on her body. This has increased her ability to maintain balance.
Onward 2021	● These exercises were accompanied by breathing exercises to increase the strength of respiratory muscles and heart muscles. ● The patient eventually increased the frequency and intensity of the exercises. ● She also introduced pilates and different yoga positions to strengthen her core muscles. She believes that the cat position is one of the most effective positions.
Up to 2021	● The physical therapy helped her gain her muscle strength back ● She currently takes 500 mg Lerace twice a day and Zeegap 150 mg once a day to maintain her health. ● She is working full time and also drives herself to work along with regular exercises.

Diagnostic Assessment: The CT Scan and the MRI were the primary sources of diagnosis. It was only after the patient agreed to get the tumor surgically removed, a biopsy of the tumor was conducted which revealed that only 20% of the tumor was safe to remove. The remaining 80% was embedded deep in the brain and its removal would have severe consequences to the patient's health. The patient was made aware of the risks and limitations of the surgery.

Therapeutic Interventions: After the surgery, radiation, and chemotherapy were recommended for the remaining part of the tumor. The duration of the radiation was 33 days, which was an I.M.R.T intensity-modulated radiation therapy of 90 Gy followed by chemotherapy done through

Temozolomide (120 mg) orally daily for 33 days as well initially. After a month's gap chemotherapy was resumed and was done for the next six months. The dosage prescribed for chemotherapy was five times a month.

The patient had regular checkups which included checking her height and weight. These check-ups were done after a month before initiation of the 5 days of chemotherapy. After about seven months another MRI was done which revealed that the tumor was still there, due to which the patient was advised to continue chemotherapy sessions in order to reduce the tumor. However, she refused to do so and written consent was signed for the same. The patient was prescribed a lot of medicines by the doctor to keep her health stable. However, due to the high dosage of medicines, she often felt sleepless and lethargic. She also experienced frequent vomiting and weakness. The headache episodes also started to reoccur after some time.

Furthermore, the patient started having frequent epileptic seizures. In order to control the onset of epileptic seizures, the patient was prescribed to take 500 mg of Lerace. The patient missed some doses which led to an epileptic seizure that caused paresis and numbness in the left side of her body. Moreover, 150 mg of Zeegab was prescribed for the pain in the body. These medicines along with a few others made the patient lethargic, sleepy, and restless.

Due to the impact of the medication, the patient began to sleep more than usual and was extremely tired and lethargic in an awakened state. She was not able to perform basic tasks and had difficulty in coping with the pace of life. She soon realized that it is the medicines that make her feel this way and hence she decided to reduce the dosage of medication while incorporating some kind of physical activity in her daily routine. She started by slowly reducing the medication and coupled it with some basic exercises. She slowly tapered off her medicines to an amount that helped to keep her health stable and reduced the adverse effects of the medication as well. However, she is consistently taking 500 mg Lerace for epileptic seizures and has not reduced its quantity.

The patient began to make lifestyle changes such as using the stairs instead of the lift and doing basic chores by herself to stay active and to regain the lost stamina. Moreover, she also started to go for walks in the park to make sure that she is leading an active lifestyle. Since she had just been through an extensive surgery and was still recovering from it physically, she decided to take physical therapy sessions where she was told that it is best for her to not engage in exercises that might strain her body. Keeping the patient's physical health in mind, the physiotherapy plan was designed to not just reduce the pain in the body but also to strengthen the muscles that were not in use due to lack of activity. Furthermore, the exercises were such that could be done at home and did not require the use of exercise equipment.

The patient used a combination of exercises to keep herself active and to deal with the physiological impact of the tumor. She began with static stretches of extremely low intensity to gain back the lost elasticity of the muscles including hamstrings, rectus femoris, quadriceps, pectoralis majors, neck extensors, and spine extensors. However, she made sure that she is not stretching the muscles beyond their present capacity which was very little due to the impact of chemotherapy and the radiation. The stretches also helped in reducing the muscle soreness, and the pain in it. She continued to increase the intensity of the stretches and would also sometimes sleep in a position that would stretch her muscles.

The patient still experiences pain on the left side of the body, especially her left arm, which is an axe cutting feeling. She uses compression bandages to reduce the pain and prefers to sleep with compression socks and bandages to keep the pain away. However, the usage of the bandages is not confined to bedtime only. She also uses it while performing her daily chores depending on the severity of the pain.

Another exercise that helped the patient was balance training. Since the loss of balance is one of the main effects of Oligodendroglioma, and due to the paralysis of her left side of the body, balance training helped in reducing the severity of this symptom. The patient performed this exercise at her home at the kitchen counter or the dining table by slowly shifting the weight to the left side of the body. This increased her ability to maintain the balance. The patient performed sets of this exercise and alternated between sitting and standing motions to make sure that she is not putting excessive pressure on her body.

The breathing exercises were accompanied by these exercises to make sure that adequate oxygen was being provided to the muscles and to increase the strength of respiratory muscles and heart muscles. Deep Breathing along with other exercises also helped the patient increase the strength of the core muscles. The patient continued to increase the frequency and intensity of her exercise and also introduced Pilates in her routine eventually. She began to use different yoga positions to help her stretch. The Cat Position is one of the positions that greatly helped her strengthen her core muscles and more importantly her spine. Apart from using physical therapy interventions, the patient also goes to work every day and drives to and from work in her own car.

Follow-up and Outcomes: The patient continues to visit the doctor for checkups to make sure that her health is stable and to stay ahead of any complications if any. The doctors are really impressed with the way she has been dealing with her condition: the epileptic seizures are in control, there is no muscular atrophy and she continues to lead a normal life. They believe that else her adherence to physical therapy interventions and medications it is her will and positivity that pushes her to maintain her health. Since the patient works full time and is not only very active in participating in household activities but also doing her job and driving her car. It is very likely for the patient to sometimes overwork herself. However, she has been managing such situations by reducing the workload at home and work when deemed necessary.

DISCUSSION

Oligodendroglioma is a rare form of brain tumor. The tumor of the patient was diagnosed with 1p_ 19Q gene deletion, therefore, its treatment comes with a limited number of options. More than the treatment, the aftercare is tricky. Surgery combined with chemotherapy and radiation

therapy is bound to cause an individual to move slowly on the path to recovery. However, with the right balance of medication and physical therapy interventions, it is possible to lead a healthy and active lifestyle.

Due to the rarity of this condition, the literature available relevant to Pakistan is very less. Thereby making this case report a valuable addition to the knowledge of Oligodendroglioma and its treatment options. However, there are a few limitations associated with this case report. A detailed medical, genetic, psychosocial, and family history is not provided which may have helped create an insight. Nevertheless, the patient's medical records and detailed history of all medical procedures and interventions have helped this case report in being thorough and insightful for future researchers, doctors, and patients.

The follow-up sessions and the patient's perspective depict that a few medications, physical therapy, and an active lifestyle change helped her gain her strength back from the left side of her body after the paresis. The patient started off with some basic stretching exercises to overcome the numbness on the left side which was a hurdle for her in the beginning as she could not move but later did pilates, yoga and also works as well as drives herself to places.

CONCLUSION

The patient has Oligodendroglioma (Grade- II), due to which she started having epileptic seizures. However, the strong will and dedication of the patient along with medication and physical therapy interventions helped her gain her muscle strength back after paresis caused by seizures. Physical therapy slowly and gradually improved her physical and mental health by providing her with a better standard of living.

Patient Perspective: The patient should share their perspective on the treatment(s) they received.

Although it is so horrible when someone comes to know that he or she has a brain tumor, especially in middle age when their kids need them so much. Everything is going on so properly and suddenly everything changes. In brain tumors, although surgery and chemotherapy have a major role the medication of tumor is so painful to bear, really one wishes to die. But I am an example to cope with these side effects of tumor treatment with the help of physical therapy intervention. It works, you feel so relax and pain-free. When you can perform your tasks on your own it decreases half of your depression. With the time as I am doing exercises regularly, it makes me so good, even now no one can imagine that I have a brain tumor. Being active in tumors is extremely hard but we have to do it, otherwise, one will go into depression and cannot cope with this horrible disease. I still have a tumor but instead of chemotherapy suggested by the doctor, I prefer the physical therapy of proper regime

REFERENCES

1. El-Hateer, H., Souhami, L., Roberge, D., Del Maestro, R., Leblanc, R., Eldebawy, E., Muanza, T., Melançon, D., Kavan, P. and Guiot, M.C., 2009. Low-grade oligodendroglioma: an indolent but incurable disease?. Journal of neurosurgery, 111(2), pp.265-271.
2. Ostrom, Q.T., Gittleman, H., Fulop, J., Liu, M., Blanda, R., Kromer, C., Wolinsky, Y., Kruchko, C. and Barnholtz-Sloan, J.S., 2015. CBTRUS statistical report: primary brain and central nervous system tumors diagnosed in the United States in 2008-2012. Neuro-oncology, 17(suppl_4), pp.iv1-iv62.
3. Ohgaki H, Kleihues P. Population-based studies on incidence, survival rates, and genetic alterations in astrocytic and oligodendroglial gliomas. J Neuropathol Exp Neurol. 2005 Jun;64(6):479-89.
4. Louis, D. N. (2007). Ohgaki h, Wiestler OD, Cavenee WK, burger PC, Jouvet A, scheithauer bW and Kleihues P: The 2007 WhO classification of tumours of the central nervous system. Acta Neuropathol, 114(2), 97-109.
5. Anderson MD, Gilbert MR. Treatment recommendations for anaplastic oligodendrogliomas that are codeleted. Oncology (Williston Park). 2013 Apr;27(4):315-20, 322.