

ORIGINAL ARTICLE

Subinguinal Cremasteric Disruption and Venous Ligation for Varicocele Repair

SYED TAHIR MOHAMMAD SHAH¹, MOHAMMAD FAROOQ², NADIA AKBAR³, MAJID BAHIR MUGHAL⁴

¹Pak Red Crescent Medical and Dental College Dina Nath, Lahore, Pakistan.

²Assistant Professor Hitec-IMS Taxila, Pakistan.

³Tehsil Headquarter Hospital Pattoki, Pakistan.

⁴University Hospital Hairmyres, East Kilbride, Glasgow, United Kingdom.

Correspondence to: Dr. Syed Tahir Mohammad Shah, E-mail: stmshah@hotmail.com

ABSTRACT

Aim: To evaluate the outcome of subinguinal cremasteric disruption and venous ligation for the treatment of varicocele with regard to improvement in semen parameters, recurrence hydrocele formation and testicular atrophy.

Methods: The clinical study was carried out from July 2016 to June 2019. Fifty-nine patients were included in the study. Varicocele repair was done as a day case surgery under local anesthesia using cremasteric disruption and venous ligation technique. The treatment outcomes studied were improvement in semen parameters and complications like recurrence, hydrocele formation and testicular atrophy.

Results: Seventy-four varicocelectomies were done in fifty-nine patients. Semen parameters improved in those nineteen patients who had abnormal semen parameters before surgery and nine out of these nineteen (47.36%) got their semen count normal after varicocele repair. There were five recurrences (6.75%). No hydrocele formation or testicular atrophy occurred during one year of follow up.

Conclusion: Day case varicocelectomy by subinguinal cremasteric disruption and venous ligation is a simple, economical choice with minimal morbidity and comparable outcomes.

Keywords: Varicocele, Subinguinal cremasteric disruption and venous ligation, complication.

INTRODUCTION

Varicocele is an abnormal tortuous dilatation of the spermatic veins that drain from testes¹. The incidence of varicocele is 15% of all men worldwide². Varicocele is found in 25-40% of infertile men^{3,4}. Varicocele patients can be asymptomatic or they can present scrotal pain, scrotal swelling and infertility. Clinically varicocele is of three grades⁵.

Grade 1: Dysfunctional veins not visible but palpable during Valsalva maneuver.

Grade 2: Veins not visible but can be palpated without Valsalva maneuver.

Grade 3: Clearly visible tortuous dilated veins on inspection. Subclinical varicoceles need imaging modalities for diagnosis.

Varicocele has been postulated as a factor responsible for seminal abnormalities. These seminal abnormalities contribute up to fifty percent of male partner infertility. Varicocele correction leads to improvement of seminal abnormalities^{4,9,10}.

Etiology of varicocele is not fully understood but there are different theories for development of varicocele. Absence of valves in testicular veins is believed to be a significant factor for the development of varicocele⁶. Another theory is compression of left renal vein between aorta and superior mesenteric artery, known as "Nutcracker Phenomenon"⁷. While these theories suggest a cause above the deep inguinal ring, none explains the clinical evidence of absence of venous tortuosity above the deep inguinal ring. According to another theory it is not a retrograde flow in the spermatic vein but a venous stasis

Received on 27-12-2020

Accepted on 15-04-2021

induced by a tight cremasteric compartment around the spermatic cord, which leads to dilatation of spermatic veins⁸.

There are different methods for the management of varicocele including radiological percutaneous occlusion, open inguinal, open retroperitoneal, laparoscopic and microsurgical approaches.

Subinguinal Cremasteric disruption and venous ligation is based on theory of tight cremasteric compartment⁸. We are sharing our experience with the technique of cremasteric disruption and venous ligation for the treatment of varicocele and its outcome measures regarding improvement in seminal analysis and complications of the procedure.

PATIENTS AND METHODS

The patients who presented with scrotal pain, scrotal swelling or infertility and found to have clinically palpable varicocele are those who were deferred from military and police recruitment centers were examined in out-patient department. Pre-operative work up including seminal analysis of all patients and scrotal ultrasonography to confirm physical findings and to rule out any associated scrotal abnormality were completed in outpatient department. In case of bilateral disease one side was operated first and the other side after three months.

Protocol design: This prospective clinical study period was 3 years from July 2016 to June 2019. This study was carried out at a peripheral Public Hospital, Punjab, Pakistan.

The inclusion criteria were patients with infertility, scrotal pain and scrotal swelling with clinically palpable varicocele and those who were deferred from military and

police recruitment centers for varicocele surgery. Patients with subclinical and recurrent varicocele were not included. Sixty-seven patients with clinically palpable varicoceles were included in this study and operated by a single surgeon. The patients were followed up at 3, 6 and 12 months. Semen analysis was repeated in those patients who had abnormal semen parameters preoperatively, at third and sixth month followup.

Ethical considerations: All the patients were consented and briefed other treatment options. The study design was approved by hospital administration. As no Institutional Review Boards existed.

Surgical Technique: All procedures were performed by the same surgeon, as day case surgeries under local anesthesia. After marking the site of surgery, skin preparation and draping, skin and subcutaneous tissue over the superficial inguinal ring and pubic tubercle was infiltrated with three milliliters of 1% xylocaine solution. A small transverse incision 2-2.5cm size was made over superficial inguinal ring. The subcutaneous tissue was separated and retracted to expose spermatic cord which is held in a sling (Figure 1).

Figure 1: Courtesymaleinfertilityindia.com

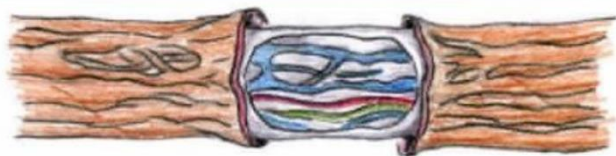

Figure 2: Courtesymaleinfertilityindia.com

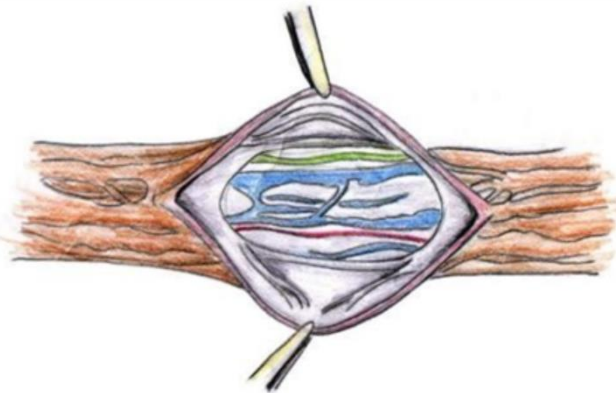
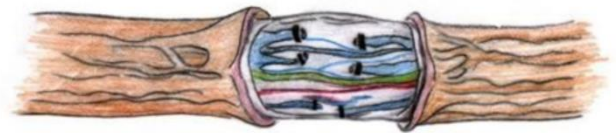


Figure 3: Courtesy maleinfertilityindia.com



Another one milliliter of anesthetic was infiltrated under the cremasteric fascia of the exposed spermatic cord. Visible cremasteric vein was ligated and cut. Cremasteric fascia and muscle were cut all around the exposed part of the spermatic cord (Figure no. 2).

Testicular artery and vas deference were identified and protected while all grossly dilated veins (more than 2-3 mm size) were ligated and transected (Figure no. 3). The procedure was not assisted with loops or operating

microscope. After ensuring hemostasis and removing sling subcutaneous tissue and skin were stitched with 4/0 vicryl. The patients were discharged from the recovery room two hours after surgery.

RESULTS

Eight patients were lost in follow up so they were excluded from the study. In remaining fifty-nine patients, forty-three (72.88%) were left sided, fifteen (25-42%) were having bilateral varicocele while only one (1.69%) had pure right sided varicocele (Table1).

Table 1: Side of varicocele (Total 59)

Side	Percentage
Left	43 (72.88%)
Bilateral	15 (25.3%)
Right	1 (1.69%)

Table 2: Clinical Presentation (Total59)

Presentation	Percentage
*Asymptomatic	29 (49.15%)
Pain	8 (13.56%)
Swelling in Scrotum	10 (16.95%)
Infertility	12 (20.34%)

*Detected during military and police recruitment.

Table 3: Grades of varicocele (Total 59)

Grade	Percentage
1	5 (8.48%)
2	24 (40.68%)
3	30 (50.84%)

Table 4: Semen parameters before and after varicocelectomy (19 patients)

Semen Parameters	Before Surgery	6 months after surgery
Mean Total Sperm count/ ejaculate	31.89±20.53 x10 ⁶ Range (0 to 60 x10 ⁶)	59.31±33.7 x10 ⁶ Range (10 x 10 ⁶ to 96 x10 ⁶)
Mean Motile sperm count/ejaculate	7.21±7.52 x 10 ⁶ Range (0-21 x 10 ⁶)	34.15±28.46 x10 ⁶ Range (2 x 10 ⁶ to 67 x 10 ⁶)

Table 5: Semen parameters before and after varicocelectomy (9 patients who became normal)

Semen Parameters	Before Surgery	6 months after surgery
Mean Total Sperm count/ejaculate	43± 14.2 x 10 ⁶ Range (12x 10 ⁶ to 60x10 ⁶)	91.88± 2.7 x10 ⁶ Range (85 x 10 ⁶ to 96 x 10 ⁶)
Mean Motile sperm count/ejaculate	11.88± 5.6 x 10 ⁶ Range (4 x 10 ⁶ to 17 x 10 ⁶)	63.55± 3.68 x10 ⁶ Range (55 x 10 ⁶ to 67 x 10 ⁶)

Table 6: Complications (Total 74)

Complication	Percentage
Minor Wound Infection	2 (2.70%)
Testicular Pain	1 (1.35%)
Hydrocele	0 (0%)
Testicular Atrophy	0 (0%)
Recurrence	5 (6.75%)

Thirty patients were referred from infertility clinic to evaluate for male factor infertility. Twelve of these found to have varicocele. Other modes of presentation were scrotal

pain (8/59), scrotal swelling (10/59) and asymptomatic patients detected during military and police recruitment and deferred for varicocele surgery (29/59) (Table 2).

Age of patients ranged from 19 years to 48 years with mean age 28.27 ± 7.13 years. Thirty patients had grade 3, twenty-four patients had grade 2 and five patients had grade 1 varicocele (Table 3).

Seventy-four varicocelectomies were done in Fifty-nine patients. Skin to skin time for procedure range from 24 to 55 minutes (mean time 36.5 ± 6.97). All seventy-four varicocelectomies were done by the same surgeon.

19 patients out of 59 had one or more semen abnormality according to WHO criterion. Most of these 19 improved their semen parameters after surgery but 9 out of these 19 (47.36%) got their semen parameters improved to normal values after surgery (Table 4 and 5).

Two patients had minor wound infection, one had prolonged left testicular pain (more than two weeks) and five (6.75%) had recurrence of varicocele in one year follow up. No testicular atrophy or hydrocele seen (Table 6).

Table 7: comparison of the common methods used for the treatment of varicoceles

Parameters	Percutaneous radiological occlusion	Laparoscopic	Open retroperitoneal/high ligation	Open inguinal ligation	Microsurgical sub inguinal
Unperformable rate	8-30%	0-11%	Low		Low
Recurrent/ Persistence rate	3-11%	3-15%	9-45%	2-5%	0-2%
Risk of arterial/ lymphatic injury	Low	Moderate	High		Very low
Overall complication rate	9-30%	8-12%	5-30%	7-13%	<5%
Hydrocele	NA	2.8(2-3.3) %	8(6-10) %	7%	0.4(0.3-1.6) %
Procedure time(min/side)	30-60	20-80	20-46	40- 60	25-62
Comments	Radiation Exposure Local anesthesia High unperformable rate for right side. Cost depends on methods used.	High Cost General anesthesia required Hospital stay over one day required in most cases Other significant complications reported Include scrotal subcutaneous emphysema (6%). Genitofemoral nerve injury, inferior epigastric artery injury	Regional or general anesthesia required. High risk of arterial and lymphatic injury. High recurrence / persistence rate due to missed venous returns.	Regional or general anesthesia required. High risk of arterial and lymphatic injury. Wound infection, genital femoral and ilioinguinal injury, testicular atrophy and epididymo-orchitis	Local, regional or general anesthesia Lowest complication and recurrence rate.

DISCUSSION

Varicocele is found upto 15% of all men population. Varicocele is considered an important factor in male partner infertility, so we did seminal analysis of all varicocele patients before surgery and after surgery. Semen analysis repeated at third and sixth month follow up for those who had abnormal semen parameters preoperatively^{4,10,12}.

There are different methods for the management of varicocele including radiological percutaneous occlusion, open inguinal, open retroperitoneal, laparoscopic and microsurgical approaches. Radiological percutaneous occlusion is a minimally invasive method of treating varicocele¹¹.

Subinguinal cremasteric disruption and venous ligation techniques for varicocelectomy is performed under local anesthesia as a day case procedure. It avoids risks of general anesthesia as required for laparoscopic and retroperitoneal approaches. It is based on the concept that the tight cremasteric compartment encircling the spermatic cord leads to venous stasis and tortuosity of the veins. Complete disruption of cremasteric muscle and fascia leads to release of venous stasis and desired results. As only abnormally dilated veins more than 2-3mm size are ligated and transected so no need of loops or operating microscope⁸. Our mean operating time from skin to skin was 36.5 ± 6.97 minutes (range 24-55 minutes) which is higher than other studies⁸. So, we did not operate both sides in one sitting in bilateral cases. It is due to our low

surgical volume for the procedure but it improved with time as shown in our results.

We followed up the patients up to one year for any complications especially recurrence. Semen analysis was done at three and six months follow up as maximum improvement of the seminal abnormalities occur up to six months¹². In our study nineteen patient out of fifty-nine (32.2%) had one or more semen abnormalities before surgery. Of these nineteen, nine patients (47.34%) seminal analysis improved. Their mean motile sperm count per ejaculate improved from $11.88 \pm$

5.6×10^6 (Range 4×10^6 to 17×10^6) to become within normal limits, $63.55 \pm 3.68 \times 10^6$ (Range 55×10^6 to 67×10^6). These results are not different from other studies¹².

Common complications of varicocelectomy with different approaches are recurrence, hydrocele formation and testicular artery injury and testicular atrophy¹¹. Following table 7 gives comparison of the common methods used for the treatment of varicoceles¹⁴.

Recurrence rate without microsurgical technique reaches up to 20% and hydrocele formation up to 13%¹¹. In our study there were 5 out of 74 recurrences (6.75%), no hydrocele formation and testicular atrophy. As in this approach only abnormally dilated veins are transected and no major dissection of spermatic cord is required. So, risk of injury to testicular artery and damage to lymphatics is minimized. Therefore, risk of testicular atrophy and hydrocele formation is less. Since meticulous venous dissection and ligation is not carried out in our approach, a

high recurrence rate may be assumed but there were only 5 out of 74 (6.75%) palpable recurrences up to one year follow up, which is comparable to other treatment options. Retroperitoneal and high ligation techniques have recurrence is more than 8%^{13,14}.

In a large study comprising of 408 varicocelectomies by subinguinal cremasteric disruption and venous ligation showed similar outcomes, the mean operating time was 15 minutes (range 10-25 minutes). 7% cases had local discomfort, there was no palpable recurrence and testicular atrophy and there was one case of hydrocele⁸.

The subinguinal cremasteric disruption and venous ligation for varicocele repair is cost effective, safe procedure with less morbidity as compared to other treatment options. Percutaneous radiological occlusion has issues of high cost, radiation exposure, expertise, high unperformable rate. Laparoscopic procedures are costly, need general anesthesia, risk of injury to intraperitoneal structures and require overnight hospital stay. Open retroperitoneal high ligation requires regional or general anesthesia, high risk of testicular artery injury, high recurrence and more than 8% hydrocele formation. Open inguinal approach needs regional or general anesthesia, opening of inguinal canal leading to weakness of inguinal canal, risk of injury to genitofemoral and ilioinguinal nerves and testicular atrophy. Microsurgical subinguinal approach is becoming popular due to its least complications and recurrence rate but it needs operating microscope and expertise¹⁴.

The varicocelectomy by subinguinal cremasteric disruption and venous ligation is a simple and economical procedure which does not involve any dissection of muscle layers as in open high ligation and inguinal canal approaches. It does not involve sophisticated gadgets like laparoscopes, operating microscopes or radiological equipment and it is easily performed under local anesthesia.

CONCLUSIONS

Varicocele occurs up to 15% of male population, it is an important factor in male partner infertility. Mostly asymptomatic but can present with scrotal pain and swelling and male infertility. Though there are several approaches for varicocelectomy

but subinguinal cremasteric disruption and venous ligation is a simple day case procedure with minimal morbidity and complications with comparable outcomes.

REFERENCES

1. Practice Committee of the American Society for Reproductive Medicine; Society for Male Reproduction and Urology. Report on varicocele and infertility a committee opinion. *Fertil Steril*. 2014; 102(6):1556-1560.
2. Pastuszak A-W, Wang R. Varicocele and testicular function. *Asian J Androl*. 2015; 17(4):659-697.
3. Redmon JB, Carey P, Pryor Jh. Varicocele – The most common cause of male factor infertility? *Hum Reprod Update*. 2002; 8(1):53-8.
4. World Health Organization. The influence of varicocele on parameters of infertility in a large group of men presenting to infertility clinics. *Fertil Steril*. 1992; 57:1289-1293.
5. Dubin L, Amelar RD. Varicocele and results of varicocelectomy in selected subfertile men with varicocele. *Fertil Steril*. 197; 21(8):606-609.
6. Sofikitis N, Dritsas K, Miyagawa I, Koukselinis A. Anatomical characteristics of left testicular venous system in man. *Arch Androl*. 1993; 30(2):79-85.
7. deSehepper A. "Nutcracker" phenomenon of the left kidney. *J Belg eRadiol*. 1972; 55(5): 507-511.
8. Shah Parag A. Varicocelectomy by subinguinal Cremasteric disruption and venous ligation. *J Obstet Gynecol Ind*. 2004; 54(1): 47-50.
9. Schmidt L, Munster K, Helm P. Infertility and seeking of infertility treatment in a representative population. *Br J Obstet Gynecol*. 1995; 102:978-84.
10. CS Kwon, JH Lee. Is semen analysis necessary for varicocele patients in their early 20s? *World J Men Health*. 2014; 32(1):50-55.
11. Ryan c. Owen, Benjamin J, et al. A review of varicocele repair for pain. *Transl Androl Urol*. 2017; 6(1):20-29.
12. Al Bakri A, Lo K, Grober E, Cassidy D, Cardoso JP, Jarvi K. Time for improvement in semen parameters after varicocelectomy. *J Urol*. 2012; 187(1):227-31.
13. Magdar I, Weissenberg R, Lunerfeld B, et al. Controlled trial of high spermatic vein ligation for varicocele in infertile men. *Fertil Steril*. 1995; 63:120-4.
14. P Chan. Management options of varicoceles. *Indian J Urol*. 2011; 27(1):65–73.