

An Insight into Detection of Laryngeal Tumor in Iraq

DURAID H. ABIDALKADEM¹, QAYSJAAFARKHALAF², HUSSIJASSIM MOHSEN³

¹Lecturer in University of Diyala, College of Medicine, Iraq

²Lecturer. Department. Otolaryngology, Diyala University - College of Medicine, Iraq.

³Associate professor. Otolaryngology - ALKINDY College of Medicine, Iraq

Correspondence to Dr. Duraid H. Abidalkaem

ABSTRACT

Laryngeal carcinoma is a vital oncological subject. The management depends on creating effective evaluation and examination measurements. In this literature, 84 patients complaining of laryngeal carcinoma were evaluated in the department of otolaryngology – Baquba Teaching hospital in Iraq. A proper history, physical examination, full oto-rhin-laryngological assessment and radiological evaluation using CT scan and MRI has been done for all involved patients. Furthermore, biopsy has been taken and sent for histopathological examination. Statistical interpretation and analysis were done for the obtained data. In this literature, gender prevalence, most common presenting symptoms and most involved sites of laryngeal carcinoma have been estimated. It is concluded that laryngeal carcinoma is still have an imperative clinical and socioeconomic problem. All patients with laryngeal carcinoma should get a wide-ranging assessment and therapeutic plan in various clinical departments. Further studies are mandatory for better understanding and accurate management of this disease.

Keywords: Squamous Cell Carcinoma, Laryngeal Tumor, odynophagia.

INTRODUCTION

To evaluate patients with laryngeal carcinoma its essential to understand the functional anatomy of the laryngeal framework (Burdett, 2011). Depending on embryological development, the larynx is subdivided into three parts, which are glottic, supraglottic and subglottic area. (Inamoto, 2015). The framework of the skeleton of the larynx is made up of numerous cartilages which are: thyroid, epiglottis, cricoid, arytenoid and sesamoid cartilage, and one bone which is hyoid bone. The laryngeal cartilage and hyoid bone are threaded together in series and suspended from the base of the skull and mandible (Monnier, 2011). The main laryngeal spaces are the pre-epiglottic space and the para-glottic space. Both spaces are essential pathways for metastasis of carcinoma within the larynx (Friedrich, 1997). The pre-epiglottic space is mainly composed of fatty tissue, loose elastic and collagen fibers. The para-glottic space composed of fatty and loose connective tissue, in addition to blood vessels oriented cranio-caudally. The lack of a horizontal anatomical portion at the level of glottis may help the spread of transglottic tumor (Chu, 2008).

The commonest type of laryngeal carcinoma is (squamous cell carcinoma). Which is related primarily to cigarette smoking. The role of alcohol drinking is less significant than other predisposing factors in cancer of other sites in head and neck (Walther, 1995) (Gourin, 2009). Laryngeal cancer incidence in seriously industrialized towns is 2 to 3 times higher than in rural inhabitants. The ratio of laryngeal carcinoma in men to women is about 10:1 (Chu, 2008). Other non-squamous cancer in the laryngeal region is about 5 to 10% and the predisposing etiology is mostly not related to tobacco and alcohol (Vaezi, 2003).

Hoarseness of voice is considered to be the most common clinical symptoms in laryngeal squamous cell tumor. Squamous cell carcinoma can be detected by endoscopy at early stage. In other hand, Neither MRI nor CT scan can detect squamous cell carcinoma at the superficial regions (Raitiola, 1999). Tumor of the larynx is

divided according to the site of origin. Supra-glottic carcinoma is usually originated from laryngeal part of the epiglottis and exhibit typical pattern of metastasis (Chu, 2008). Glottic tumor is typically originated from the anterior part of the true vocal folds (Raitiola, 1999). Endoscopic examination can detect a small glottis mass which may be difficult to detect by CT scan or MRI. The trans-glottic carcinoma is the term referring to involvement of both supraglottic and glottis at the same time (Gourin, 2009).

PATIENTS AND METHODS

This study is a prospective study. It was done in the Otolaryngology-Head & Neck Surgery unit in Baquba Teaching Hospital in Diyala governorate in Iraq, from October 2018 to September 2020. The research included 84 patients with laryngeal carcinoma who admitted to the ENT department at this period. Full history was taken from the patients which include: name, age, sex, occupation, smoking habits, living area, alcohol consumption chief complaint and main symptoms (hoarseness of voice, dysphonia, dyspnea, stridor, cough, hemoptysis, dysphagia, weight loss, otalgia and throat pain) physical examination and oto-rhino-laryngological assessment by using laryngeal mirror and flexible and rigid nasolaryngoscopy. We focused on the site and side of the lesion, mobility of the vocal cords, pooling of saliva and type of mass. Neck examination has been done for cervical lymphadenopathy which include the level and number of lymph nodes involved. CT scan and MRI has been taken to every patient. Furthermore, biopsy was taken and sent for histopathological assessment.

Statistical analysis: Data were interpreted into a computerized database. Practiced statistical information was searched. Statistical analyses were done using SPSS. Incidence distribution for certain variables was done at first.

RESULTS

In both Table 1 and 2, 84 patients were included. 68 patients (81%) were men and 16 (19%) were women,

consistent to a men/ women ratio of about 4/1. Patients' ages were ranged between 36–78 years among men, while among women were 50– 70 years among, with mean ages of 61 and 63.1 years, respectively, and 62.7 for both genders.

In table 3, the most common presenting symptom was hoarseness of voice which considered (47.6%), after that stridor (42.9%), while hemoptysis (2.4%) ,odynophagia or throat Pain and sore throat comprising (2.4%), (4.8%) correspondingly.

The results in table 4 represent that supraglottic region was consist of (50%), in other hand, glottic and transglottic regions were comprised (29%), (21%) respectively. Moreover, there were no subglottic tumors in our study.

Table 1: Frequency distribution of study sample by age groups.

Age in years	n	%age
Less than 49	6	7.1%
50-59	24	28.6%
60-69	28	33.3%
More than 70	26	31%
Total	84	100%

Age range between 35-79 years with Mean/ plus or minus SD (62.6+/-9.5)

Table 2: Distribution of study sample by gender with a mean age for both genders

Genders	n	%age	Mean
Female	16	19	61
Male	68	81	63.1
Total	84	100	

Male to Female ratio = 4:1

Table 3: Frequency distribution of the patients with laryngeal carcinoma by the most common presenting symptoms. Highly Significant at P<0.01.

Chief complaint	n	%age
Hoarseness of voice	40	47.6%
Stridor	36	42.9%
Soreness of throat	4	4.8%
Hemoptysis	2	2.4%
Throat pain	2	2.4%
Total	84	100%
P value	K/S equal to 0.325 P equal to 0.00HS	

Figure 1: Distribution of patients by most common presented symptoms.

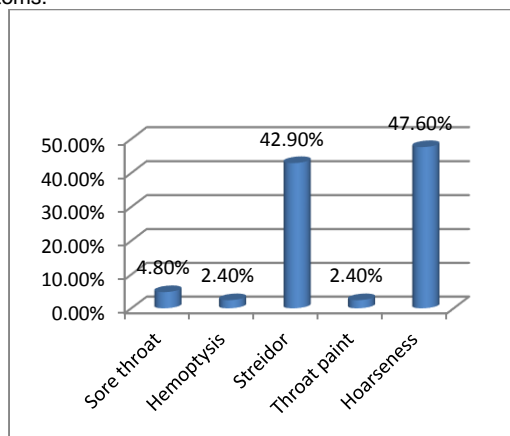


Table 4: Incidence distribution of study sample by the site of laryngeal tumor.

Tumor site	N	%age
Supra glottis	42	50%
glottis	24	28.6%
Transglottic	18	21.4%
Total	84	100%

P- value0.062

DISCUSSION

In this study, the most common principal complaint was hoarseness of voice (47.6%), after that stridor (42.9%), hemoptysis (2.4 %) with throat pain and soreness of throat comprising (2.4%), (4.8%) correspondingly. This is compatible with other study done by Vaezi, and who reported that the most common chief complaint was hoarseness of voice (35%), followed by shortness of breath and stridor (30%), dysphagia (15%), lump in the neck (10%), otalgia (10%) with sore throat and hemoptysis (5%) for each symptoms(Vaezi, 2003). In other study done byGourin,et al, they found that the most common presenting symptom of laryngeal carcinoma was hoarseness (83.6%)(Gourin, 2009). In other published study they reported the most common presenting chief complaint was hoarseness of voice (74.1%) followed by stridor (33%) and otalgia (22.3%)(Markou, 2013).

There was no subglottic involvementidentified in our literature as asolitary involvement.Our results showed that supraglottic region was more involved in malignancy (50%), whereas glottic region was seen involved in (28.6%) and trans-glottic region in (21.4%). This is closely the similar results obtained by Raitiola, et al who reported that supraglottic region was more affected than other regions and comprised (46%), the glottic (37%), subglottic (9.3%) and transglottic (7.7%). Our results were dissimilar with other reports who found that glottis tumor was more common than other types(Raitiola, 1999).

In the previous 50 years, we have observed substantial rise in the occurrence of carcinoma of the larynxparticularly in east states and decrease in the ratio of male to female(Markou, 2013). Tumor of the larynx is mostly common in male(Chu, 2008). The ratio between male and female differsglobally , from 5:1 to 30:1, whereasthe ratio in the Europe is 7:1(Peller, 2016).. In this study we reported from 84 involved patients 68 patients (81%) were men and 16 (19%) were women, consistent to a men/ women ratio of about 4/1.This may be related to tobacco smoking which considered to be the most imperative risk factor for laryngeal tumor development. However, in currently, they have distinguished a substantial increase in the women percentage with laryngeal carcinoma compared to men(Peller, 2016).

CONCLUSION

Laryngeal carcinoma is still have an imperative clinical and socioeconomic problem. All patients with laryngeal carcinoma should get a wide-ranging assessment and therapeutic plan in various clinical departments. Further studies are mandatory for better understanding and accurate management of this disease.

REFERENCES

1. Monnier, P. (2011). Applied surgical anatomy of the larynx and trachea. In *Pediatric airway surgery* (pp. 7-29). Springer, Berlin, Heidelberg.
2. Burdett, E., & Mitchell, V. (2011). Anatomy of the larynx, trachea and bronchi. *Anaesthesia & Intensive Care Medicine*, 12(8), 335-339.
3. Friedrich, G., & Lichtenegger, R. (1997). Surgical anatomy of the larynx. *Journal of voice*, 11(3), 345-355.
4. Inamoto, Y., Saitoh, E., Okada, S., Kagaya, H., Shibata, S., Baba, M., ... & Palmer, J. B. (2015). Anatomy of the larynx and pharynx: effects of age, gender and height revealed by multidetector computed tomography. *Journal of oral rehabilitation*, 42(9), 670-677.
5. Gourin, C. G., Conger, B. T., Sheils, W. C., Bilodeau, P. A., Coleman, T. A., & Porubsky, E. S. (2009). The effect of treatment. *Otolaryngologic Clinics of North America*, 41(4), 673-695.
6. Walther, E. K. (1995). Dysphagia after pharyngolaryngeal cancer surgery. Part I: Pathophysiology of postsurgical deglutition. *Dysphagia*, 10(4), 275-278.
7. on survival in patients with advanced laryngeal carcinoma. *The Laryngoscope*, 119(7), 1312-1317.
8. Vaezi, M. F., Hicks, D. M., Abelson, T. I., & Richter, J. E. (2003). Laryngeal signs and symptoms and gastroesophageal reflux disease (GERD): a critical assessment of cause and effect association. *Clinical Gastroenterology and Hepatology*, 1(5), 333-344.
9. Markou, K., Christoforidou, A., Karasmanis, I., Tsiropoulos, G., Triaridis, S., Constantinidis, I., ... & Nikolaou, A. (2013). Laryngeal cancer: epidemiological data from Northern Greece and review of the literature. *Hippokratia*, 17(4), 313.
10. Raitiola, H., Pukander, J., & Laippala, P. (1999). Glottic and supraglottic laryngeal carcinoma: differences in epidemiology, clinical characteristics and prognosis. *Acta otolaryngologica*, 119(7), 847-851.
11. Baumann, J. L., Cohen, S., Evjen, A. N., Law, J. H., Vadivelu, S., Attia, A., ... & Slebos, R. J. (2009). Human papillomavirus in early laryngeal carcinoma. *The Laryngoscope*, 119(8), 1531-1537.
12. Marioni, G., Marchese-Ragona, R., Cartei, G., Marchese, F., & Staffieri, A. (2006). Current opinion in diagnosis and treatment of laryngeal carcinoma. *Cancer treatment reviews*, 32(7), 504-515.
13. Müller, R., Paneff, J., Köllner, V., & Koch, R. (2001). Quality of life of patients with laryngeal carcinoma: a post-treatment study. *European archives of oto-rhino-laryngology*, 258(6), 276-280.
14. Peller, M., Katalinic, A., Wollenberg, B., Teudt, I. U., & Meyer, J. E. (2016). Epidemiology of laryngeal carcinoma in Germany, 1998–2011. *European archives of oto-rhino-laryngology*, 273(6), 1481-1487.
15. Antanavičiūtė, I., Rysevaitė, K., Liutkevičius, V., Marandykina, A., Rimkutė, L., Sveikatiėnė, R., ... & Skeberdis, V. A. (2014). Long-distance communication between laryngeal carcinoma cells. *PLoS one*, 9(6), e99196.