

REVIEW ARTICLE

Sonographic Advancements in Characterization of Benign and Malignant Ovarian Masses: A Systematic Review

FUROZAN BAIG^{1,2}, SAYYEDA KHADIJA¹, NIMRA AFZAL¹, IRUM RAHEEM^{1,3},¹University Institute of Radiological Sciences & Medical Imaging Technology, University of Lahore, Pakistan²Department of Medical Imaging and Ultrasonography, School of Health Sciences, University of Management & Technology, Lahore,³Department of Medical Imaging and Radiology, Northwest Institute of Health Sciences, Affiliated to Khyber Medical University Peshawar, Correspondence to Furozan Baig, Email: frozaan.beyg@gmail.com, Contact: +923336918630, ORCID: <https://orcid.org/0000-0001-9899-0556>

ABSTRACT

Background: Characterization of ovarian masses is essentially required and inevitable for optimization of clinical decision making, patient care and management. The diagnosis of ovarian masses is a frequent dilemma in clinical work. Ultrasonography remains the modality of choice in the early investigation of suspected adnexal masses because of its availability and being a safe modality.

Aim: To review the current literature on different patterns of manifestation of ovarian masses on ultrasound and its various modes, helping in differential diagnosis on the basis of morphologic, vascular and other characteristics as seen on ultrasound.

Methods: Electronic database was searched (PubMed, Google Scholar, Science direct) with data ranging from year 2000 to 2021. Most relevant studies, relating to sonographic appearances of ovarian masses were selected.

Results: Twenty five most relevant articles were found: 8 articles were regarding gray-scale ultrasound, 3 articles regarding three dimensional ultrasonography, 2 articles regarding contrast enhanced ultrasonography, 2 regarding elastography and rest were regarding combined use of gray-scale and Doppler ultrasound including color and power Doppler ultrasonography for the assessment of ovarian masses. Our results show that conventional 2D sonography, in conjunction with latest advancements helps improving the diagnosis based on typical sonographic appearances of masses. Screening for ovarian cancer also proves to be helpful for early diagnosis and improvement in survival rate.

Conclusion: Ultrasonography and its different modalities such as 3DUS, CEUS, elastography along with conventional 2D and Doppler studies accurately identifies morphologic, structural and vascular features of the adnexal masses and differential diagnosis by escaping unnecessary surgeries and improving the survival rate.

Keywords: Ultrasonography, Ovarian masses, malignant ovarian masses, contrast enhanced ultrasound,

INTRODUCTION

Ovarian cancer is the “fifth” most common cause of death among women due to cancer thus having the highest death rate¹.

Characterization of ovarian masses is essentially required and inevitable for optimization of clinical decision making, patient care and management. The identification of ovarian masses is a frequent predicament in gynecology clinics. It is the likelihood of malignancy that compels us for making reliable, proper and immediate diagnosis to decrease morbidity and mortality. Early detection of ovarian tumors remains crucial for improving patient survival rate.

Of all gynecologic carcinoma, ovarian carcinoma is most difficult to diagnose clinically. Also, correctly classifying benign masses aids in selecting the patients with ovarian pathologies that may either not need intervention, or minimal access procedures can be done if necessary. This classification between non-cancerous and malignant masses is necessary for reducing

the anxiety of patient and for better clinical decision making. Ultrasonography continues to be the modality of choice for the primary investigation of suspected adnexal masses because of its availability. Other reasons being it relatively inexpensive and noninvasive. Transabdominal and/or, transvaginal ultrasound must be done for the assessment of ovarian masses².

These ovarian masses are evaluated on gray-scale as well as Doppler ultrasound. With the advent of newer technologies, three dimensional ultrasonography and contrast enhanced ultrasonography is also being employed for better diagnosis and outcomes.

METHODOLOGY

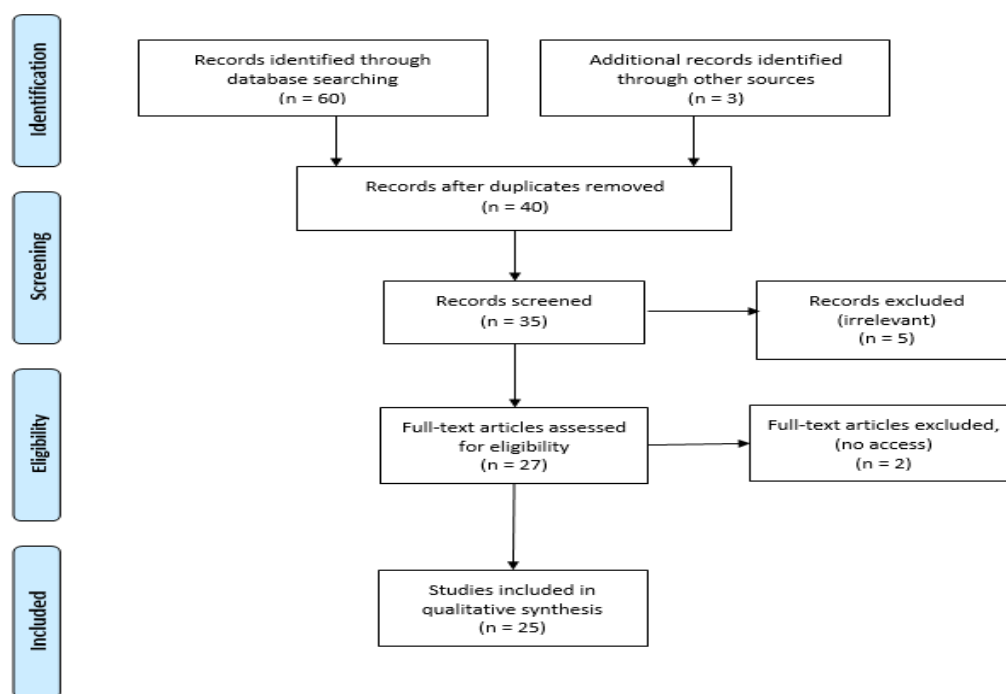
Electronic database was searched (PubMed, Google Scholar, Science direct) with data ranging from year 2000 to 2021. A total of 25 relevant studies, relating to sonographic appearances of ovarian masses were selected.

Received on 13-03-2021

Accepted on 27-06-2021



PRISMA 2009 Flow Diagram



From: Moher D, Liberati A, Tetzlaff J, Altman DG, The PRISMA Group (2009). Preferred Reporting Items for Systematic Reviews and Meta-Analyses: The PRISMA Statement. *PLoS Med* 6(7): e1000097. doi:10.1371/journal.pmed1000097

RESULTS

The most common features in benign masses, according to transabdominal and transvaginal ultrasonography with fixed Doppler indices and parameters in 60 patients, has cystic components (90%), well defined margins (84.4%) and thin septations (53.57%). In comparison, malignant masses had predominantly solid consistency (76%) with ill-defined margins (66.66%), thick septations and papillary projections (90.90%). On color Doppler, neovascularization was found in 92.59% and 42.25% of malignant and benign tumors, respectively. Central vascularity was found in 76.47% of malignant solid tumors while benign solid tumors had 25% central vascularity. 88% of malignant lesions had mean systolic velocity of greater than 15 cm/s in comparison to 14% of benign masses. Most benign masses had Resistive index >0.6 , while most malignant tumors had an RI of <0.6 . (3). These Sonographic findings were associated with histopathology to confirm the diagnosis.

Ultrasound, whether transabdominal or transvaginal, depends on morphology of the tumor to differentiate it as either benign or malignant. Morphologic features such as "thick, irregular walls and septa, papillary projections, and solid, moderately echogenic loculi" are demonstrated as indicative of malignancy. Many morphologic scoring classifications have been recommended which are based

on certain features of lesions such as: "wall thickness, inner wall structure, septal characteristics, and echogenicity"³.

Valentin et.al picked five simple rules for the prediction of malignancy (M- rules): "1- irregular solid tumor; 2- ascites; 3- at least four papillary structures; 4- irregular multilocular-solid tumor with a largest diameter of at least 100 mm; and 5- very high color content on color Doppler examination. Five simple rules were taken to characterize benign tumor (B- rules): 1- unilocular cyst; 2- presence of solid components where the largest solid component is < 7 mm in largest diameter; 3- acoustic shadows; 4- smooth multilocular tumor < 100 mm in largest diameter; and 5- no detectable blood flow on Doppler examination"⁴. These ten rules were apt for 76% of all 1233 adnexal masses in 1066 patients, resulting in a sensitivity and specificity of 93% and 90%, respectively. 903 masses (73%) were found to be benign and 330 (27%) were malignant. If these rules are not sufficient, ultrasonography with histological correlation and experienced sonologist is suggested⁴.

In 2009, "GI-RADS (Gynecology Imaging Reporting and Data System)" was introduced, which employs "pattern recognition analysis" for evaluation of adnexal masses. Findings are classified into 5 graded categories. "Grade 1 masses are considered to be definitely benign, whereas grade 5 masses are considered to be very probably malignant (51). Masses in grades 2–4 are categorized as very probably benign, probably benign, and probably

malignant, respectively". Grade 4 and 5 include malignant features such as "thick septations, papillary projections, solid parts or ascites with vascularization in solid area or central area of a solid mass" on color or power Doppler USG⁵. The sensitivity of GIRADS system in predicting malignancy was 99.1% and specificity was 85.9%⁶.

Latest practice of "microbubble contrast agents" made possible the sonographic representation of "tumor neovascularity" in ovarian tumors. Multiple studies^{7,8,9} have proved that ovarian malignancy of initial stages can be differentiated from benign masses according to the enhancement patterns. Generally, "malignant ovarian masses have greater peak enhancement, longer wash-out time, and increased vascular volume than benign masses".

A comparative study was performed by Juan et.al to compare the 2D and 3D power Doppler imaging for ovarian cancer detection in 60 patients with 69 complex adnexal masses. Complex adnexal mass were found to have at least one of the features of malignancy such as solid areas, thick septa and papillary projection or solid echogenicity. Out of 69 masses, 45(65.2%) were found to be malignant and rest were benign. Diagnostic accuracy in terms of sensitivity and specificity of 2D and 3D power Doppler were found to be almost similar for the distinction of benign from malignant masses¹⁰.

Stefano Guerriero et.al performed a prospective study in 1997 women with 2148 adnexal masses on transvaginal gray-scale, color and power Doppler ultrasonography. Cystic masses without benign echotexture were labelled as malignant. Malignant masses were categorized on the basis of flow shown on Doppler. Any solid portions of the mass was assessed with the help of color and power Doppler sonography. Masses were categorized as malignant if "flow was shown within the tumor or the solid areas" and benign if "there was no flow or if flow was only found in periphery". 468 masses were found to be malignant. Evaluating the vessel distribution in masses with color Doppler in conjunction with gray-scale ultrasonography increases the diagnostic precision of ultrasonography in adnexal masses distinction¹¹.

Resistive index (RI) validity was evaluated by Hamid et.al in 37 women on transabdominal and transvaginal ultrasonography. Ovarian masses were classified as benign or malignant according to their morphologic features on sonography. A threshold RI of 0.4 was used to differentiate benign from malignant masses. The results were similar to some other studies¹² which show a sensitivity of 26-37% when a threshold RI of 0.4 or less is used. These articles¹³ emphasize that some benign lesion such as endometriomas may show low resistant flow, which is particularly suggestive of malignant masses. Likewise, few malignant tumors show high-resistance flow. Resistive index evaluation can improve specificity for the assessment of possible malignant masses but a total reliance on RI is potentially misleading¹⁴.

US 'scoring systems' were suggested by some authors for detection of ovarian masses using various sonographic parameters. One of the first score system was proposed by Sassone et al. in 1991¹⁵.

A latest technique called 'pattern recognition'¹⁶ was presented to categorize different types of ovarian neoplasms. According to this method, tumor detection is

based on their characteristic morphologic sonographic appearance. These characteristics includes "volume, localization, associated features as ascites, internal structure (wall, inner contour/papillary projections, septa, and solid areas), echogenicity and the presence of shadow and/or Crescent sign".

In 2010, a study¹⁷ a comparative study between conventional gray-scale and color Doppler ultrasonography was done. Malignant masses were identified when flow was present at the level of vegetation or solid areas were present. Masses were classified as benign if there was no flow or at periphery. Gray-scale diagnosis of such tumors alone is found to be less accurate than using grayscale with color Doppler with a specificity of 84% in comparison of 94% and relatively comparable sensitivity (95 vs 98%)¹⁷.

In recent years, "International Ovarian Tumor Analysis (IOTA)" group introduced standardized expressions, descriptions and measurements depicting adnexal masses¹⁸. In IOTA, "masses were classified into five categories: unilocular cyst, unilocular solid cyst (a unilocular cyst containing at least one solid part possibly a papillary projection that protrude the cavity with height of $\geq 3\text{mm}$), multilocular cyst, multilocular-solid cyst (a multilocular cyst containing minimum of one solid part) and solid cyst (that contains at least 80% solid tissue)". The cystic masses were classified as: "anechoic (black), low-level echogenicity, and ground glass appearance (as often seen in endometriotic cysts), (4) hemorrhagic and (5) mixed (often seen in teratomas)". The degree of vascularization was evaluated with a scoring from 1 to 4. Color score "1 is given when no blood flow can be seen in the lesion, color score two if minimal flow can be detected, color score three is assigned when moderate blood flow exists and color score four for marked blood flow".

IOTA has also suggested many predictive models for ovarian masses, including 'Simple rules' SR which is a descriptive model that contains "five sonographic characteristics for malignant masses (M-rules) and five SR to predict a benign tumor (B-rules)". If one or more M-rules with no B-rules is present, the mass is classified as "malignant". If at least one B-rule apply with no M-rule, the mass is referred to as "benign". In cases of both B and M-rules simultaneously or no rule, other models of classification are used instead of SR¹⁹.

Another advancement, 3D ultrasonography enables the acquisition of 3D volumes^{20,21} that can be saved and reconstructed electronically and displayed as multiplanar using specialized software's. It simultaneously allows three orthogonal planes and navigation through them (axial, longitudinal and coronal). There are three main modalities using 3D-US: the 'inversion' mode that shows the shape of the cystic cavity, making the fluid filled structure appear as 'white', surface rendering for 3D reconstruction and tomographic imaging of vessels similar to Computed Tomography (CT). Volume calculation is also possible in asymmetrical or irregular structures. "3D power Doppler angiography" evaluates the vascularity of organs with the help of reconstruction and software's which calculates indices derived from power Doppler²². The routine indices are the "vascularization index (VI), flow index (FI), and the vascularization-flow index (VFI)". The VI "measures the ratio between the number of color voxels and total number

of voxels as well as amount of vessels". The FI represents "average color value of all color voxels and it shows the intensity of flow within those vessels while VFI shows both blood flow and vascularization and it is a derived parameter from VI and FI".

Another advancement, transvaginal elastography also proves to be of potential role in distinguishing between benign and malignant ovarian masses of cystic nature. The elasticity colour code of ovarian lesions was classified in 5 patterns: "pattern 1, an absent or a very small hard area; pattern 2, hard area <45 per cent; pattern 3, hard area >45 percent; pattern 4, peripheral hard and central soft areas; pattern 5, hard area occupying entire solid component with or without soft rim". Strain index was calculated by comparing surround soft tissue area to solid component. Masses with pattern 3-5 were considered malignant. Among 15 lesions, 3 masses with pattern 3-5 were considered malignant, which later proved to be true when correlated with histopathology²³.

DISCUSSION

Morphologic evaluation of ovarian masses has become clinically important for the prediction of malignancy. From the review of literature, it is observed that on conventional two dimensional sonographic evaluation of masses, malignant masses for shown to have certain features such as irregular borders, thick septations and internal echoes. But unfortunately, some of the benign lesions also happens to possess similar characteristics which renders the usability of conventional ultrasonography very limited. Color Doppler technique, which was introduced in early 1990 provided some additional information regarding tumor neovascularization and blood flow measurements. Several indexes were developed regarding flow measurements which were found to be encouraging initially as some studies(24)(25) (26) showed that complete reliance on such measurements for making a diagnosis is not clinically applicable. Later, some studies with multivariate analysis of sonographic and Doppler parameters proved that a combination of different modes which gives morphologic as well as blood flow measurements together are more reliable in prediction of ovarian malignancy^{27,28}. With the advent of newer techniques such as three dimensional sonography, power Doppler, three dimensional power Doppler and Elastography proved to be of great clinical value in prediction of the type of lesions. Currently, diagnosis are being made following the guidelines of IOTA, GIRADS and other predictive models, with different scoring systems providing significant improvement in diagnosis over the years.

Some multicenter trials have also been done to assess the diagnostic capability of ultrasound in screening for ovarian cancers. One of such trials is the randomized controlled "UK Collaborative Trial of Ovarian Cancer Screening published in Lancet Oncology in 2009"²⁹. The total patients involved in this 5 years long study were (n=202638) and about 25% of which had annual sonographic assessment. Results indicated that US has significant specificity with even better results found associated with CA-125. One more significant study by van Nagell et al. in 2011³⁰ was done to consider the outcome of

sonographic screening for the detection of ovarian cancer. In this study (from 1987 to 2011 about 38,000 women had sonographic screening done. "62 tumors were found and the 5-year survival rate was 75 % compared with 54% for unscreened women". It revealed that screening of asymptomatic females' makes early detection of ovarian cancer possible thus improving the survival rates. A pilot study which was done in the "Kentucky Ovarian Cancer Screening Program" involving about 40,000 women³¹ presented that initially complex appearing abnormalities were found to be resolved on follow up scans. It is significant because some complex lesions are short-lived and may resolve with follow-up examination. Such diagnosis can easily distinguish malignant cancers from benign tumors³².

CONCLUSION

In the last years, a significant advancement in the world of ultrasonography has been noticed in the detection and description of ovarian masses. Today, ultrasonography and its different modalities such as 3DUS, CEUS, Elastography along with conventional 2D and Doppler studies identifies morphologic, physical and certain other characteristics which maybe of vascular nature, of the adnexal masses by avoiding needless surgical procedures and thus improving the survival rate. These characteristics could be helpful for teaching purposes, especially for sonographers and sonologists with limited experience for better diagnostic accuracy. The results from previous studies were found to be reproducible for better clinical decision making. Ultrasonography is also being employed for screening purposes of ovarian cancer, serial approach was found to be very supportive as some complex pathologies are transient and clear up with follow up examinations.

Acknowledgment:: I am very thankful to Dr. Sayyeda Khadija, Assistant professor, Department (UIRSMIT) FAHS, University of Lahore, and my classmate Irum Raheem (Student of MS Diagnostic Ultrasound, University of Lahore) for their unforgettable kind help and encouraging support.

Financial & competing interests disclosure: I declare that I have no financial contribution from any association or institution. It is a learning based study and I have no competing interests.

Figure 1: Power Doppler Ultrasound showing three dimensional reconstruction of vascular bed of an ovarian mass²¹.

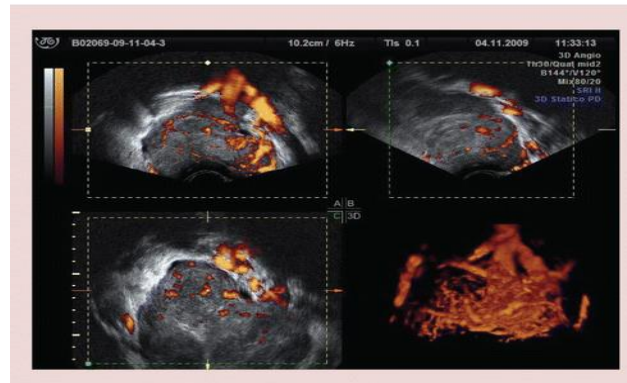
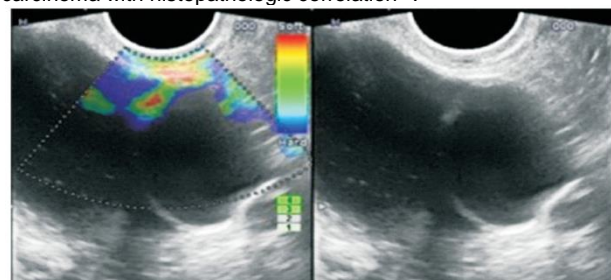


Figure 2: Ultrasound tomography image of an ovarian malignant tumour²¹.

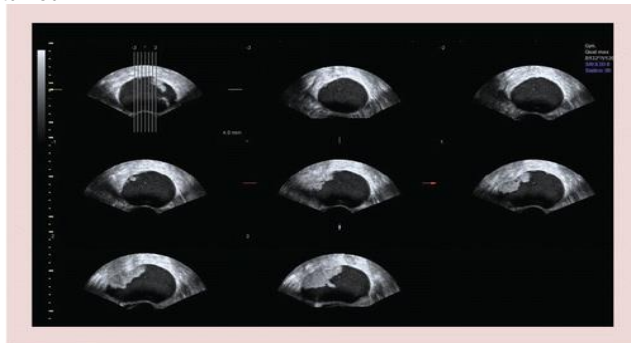

Figure 3: Elastography image of an ovarian cyst coded type 5 color pattern with nodular components, later proved to be clear cell carcinoma with histopathologic correlation²⁴.



REFERENCES

- Jacques S. Abramowicz DT. Ovarian mass—differentiating benign from malignant: the value of the International Ovarian Tumor Analysis ultrasound rules. *American Journal of Obstetrics and Gynecology*. 2017; 217(6): Pages 652-660.
- Bourne ASCELFJKCSSDIT. The characteristic ultrasound features of specific types of ovarian pathology (review). *International Journal of Oncology*. 2014; 46(2): 445 - 458.
- Jeong YY. Imaging Evaluation of Ovarian Masses. *RadioGraphics*. 2000; 20(5): 1445-1470.
- Valentin DTACTTBLADJCVHDPBVCIVSVHL. Simple ultrasound-based rules for the diagnosis of ovarian cancer. *Ultrasound in obstetrics and gynecology*. 2008; 31(6): 681-690.
- L V. Use of morphology to characterize and manage common adnexal masses. *Best Pract Res Clin Obstet Gynaecol*. 2004; 18: 71-89.
- Amor F VHAJLMCJM. Gynecologic imaging reporting and data system: a new proposal for classifying adnexal masses on the basis of sonographic findings. *J Ultrasound Med*. 2009; 28(3): 285-291.
- Orden MR JJKP. Kinetics of a US contrast agent in benign and malignant adnexal tumors. *Radiology*. 2003; 22(6): 405-410.
- Testa AC FGFEea. The use of contrasted transvaginal sonography in the diagnosis of gynecologic diseases: a preliminary study. *J. Ultrasound Med*. 2005; 24: 1267-1278.
- 9.Fleischer AC LAJHJ,ea. Contrast-enhanced transvaginal sonography of benign versus malignant ovarian masses: preliminary findings. *J. Ultrasound Med*. 2008; 27: 1011-1021.
- Juan Luis Alcázar MD GCM. Comparison of 2-dimensional and 3-dimensional power-Doppler imaging in complex adnexal masses for the prediction of ovarian cancer. *American Journal of Obstetrics and Gynecology*. 2004; 192(3): 807-812.
- Guerriero S AJASea. Transvaginal Color Doppler Imaging in the Detection of Ovarian Cancer in a Large Study Population. *International Journal of Gynecologic Cancer*. 2010; 20: 781-786.
- Schneider VL SARKHK. Comparison of Doppler with two-dimensional sonography and CA 125 for prediction of malignancy of pelvic masses. *Obstet Gynecol*. 1993; 81: 983-988.
- Hata K HTMASKMK. A critical evaluation of transvaginal Doppler studies, transvaginal sonography, magnetic resonance imaging, and CA 125 in detecting ovarian cancer. *Obstet Gynecol*. 1992; 80: 922-926.
- WH. P. Management of adnexal masses by operative laparoscopy. Selection criteria. *J Reprod Med*. 1992; 37: 603-606.
- Sassone AM TTIAA. Transvaginal sonographic characterization of ovarian disease: evaluation of a new scoring system to predict ovarian malignancy. *Obstet. Gynecol*. 1991; 78: 70-76.
- L. V. Pattern recognition of pelvic masses by gray-scale ultrasound imaging: the contribution of Doppler ultrasound. *Ultrasound Obstet. Gynecol*. 1991; 14(5): 338-347.
- Saunders BA PIWR. Risk of malignancy in sonographically confirmed septated cystic ovarian tumors. *Gynecol. Oncol*. 2010; 118(3): 278-282.
- Timmerman D VLBTCVVHVI. Terms, definitions and measurements to describe the sonographic features of adnexal tumors: a consensus opinion from the International Ovarian Tumor Analysis (IOTA) group. *Ultrasound Obstet. Gynecol*. 2000; 16(5): 500-505.
- Timmerman D TABT. Simple ultrasound-based rules for the diagnosis of ovarian cancer. *Ultrasound Obstet. Gynecol*. 2008; 31(6): 681-690.
- JL. A. Three-dimensional ultrasound in gynecology: current status and future perspectives. *Curr. Womens Health Rev*. 2005; 1(1): 1-14.
- Bega G LTAOPBEKA. Three-dimensional ultrasonography in gynecology: technical aspects and clinical applications. *J. Ultrasound Med*. 2003; 22(11): 1249-1269.
- Pairleitner H SHHGA. Three dimensional power Doppler sonography: imaging and quantifying blood flow and vascularization. *Ultrasound Obstet. Gynecol*. 1999; 14(2): 139-143.
- NazanCiledag KAEABKA. A pilot study on real-time transvaginal ultrasonographic elastography of cystic ovarian lesions. *Indian J Med Res*. 2013 June; 137(6): 1089-1092.
- Kawai M KTKFMOOHTY. Transvaginal Doppler ultrasound with color flow imaging in the diagnosis of ovarian cancer. *Obstet Gynecol*. 1992; 79: 163-167.
- Valentin L SPMK. Limited contribution of Doppler velocimetry to the differential diagnosis of extrauterine pelvic tumors. *Obstet Gynecol*. 1994 425-433; 83.
- Stein SM LNSJMRMLTJea. Differentiation of benign and malignant adnexal masses: relative value of gray-scale, color Doppler and spectral Doppler sonography. *AJR Am J Roentgenol*. 1995; 164: 381-386.
- Schelling MBKBBGGRGJea. Combined transvaginal B-mode and color Doppler sonography for differential diagnosis of ovarian tumors: results of a multivariate logistic regression analysis. *Gynecol Oncol*. 2000; 79: 78-86.
- Alca'zar JL MLLCJMLGG. A new scoring system to differentiate benign from malignant adnexal. *Am J Obstet Gynecol*. 2003; 188: 685-92.
- Menon U GMAHR. Sensitivity and specificity of multimodal and ultrasound screening for ovarian cancer, and stage distribution of detected cancers: results of the prevalence screen of the UK Collaborative Trial of Ovarian Cancer Screening (UKCTOCS). *Lancet Oncol*. 2009; 10(4): 327-340.
- Van NagelJR Jr MRDC. Long-term survival of women with epithelial ovarian cancer detected by ultrasonographic screening. *Obstet. Gynecol*. 2011; 118(6): 1212-1221.
- Pavlik EJ UFM. Frequency and disposition of ovarian abnormalities followed with serial transvaginal ultrasonography. *Obstet. Gynecol*. 2013; 122: 210-217.
- Guerriero S SLAJea. Past, Present and Future Ultrasonographic Techniques for Analyzing Ovarian Masses. *Women's Health*. 2015: 369-383.