ORIGINAL ARTICLE

Comparison of Nickel Titanium and Spring Jet expander for the Maxillary Arch Expansion

SAMINA QADAR[1], SADAF SHAHEEN[2], MUHAMMAD AZEEM[3], FAREEHA BOKHARI[4], UMER MEHMOOD BAJWA[5], WALEED KHALID[6]

[1,3] Assistant Professor Orthodontics, de'Montmorency College of Dentistry, Lahore, Pakistan.
[2] PGR Orthodontics, de'Montmorency College of Dentistry, Lahore, Pakistan.
[4]Associate Professor Orthodontics, UCD, UOL, Lahore, Pakistan.
[5] BDS Student, UCD, UOL, Lahore, Pakistan
[6] BDS Student, FMH, Lahore, Pakistan
Correspondence to Dr Samina Qadar, drsaminaqadar@hotmail.com

ABSTRACT

Background: Nickel titanium and spring jet expanders are not compared yet for expansion changes.
Aim: To compare maxillary expansion changes using Nickel titanium (NiTi) expander and the Spring Jet (SJ) expanders.
Methods: This study comprised 50 patients selected from the Orthodontics Department. Patient's age ranged from 11 to 14 years of either sex with maxillary bilateral posterior cross bite, mild maxillary arch crowding and having maxillary dentition completed from first molar to the opposite molar were selected. The study comprised two treatment groups with 25 patients in each group. The group A received treatment with NiTi expander; the group B with SJ expander.
Results: The NiTi appliance widened the palate more and the gain in arch perimeter was more whereas there was less molar tipping, extrusion and distalization by the SJ appliance. Both the expanders produced significant increase in inter-premolar and inter-canine width.
Conclusion: Both Nickel Titanium and Spring Jet expanders are equally capable of palatal expansion by relieving posterior cross bite.
Keywords: Spring Jet, NiTi expander, Maxillary Expansion.

INTRODUCTION

Maxillary arch expansion is an accepted method of treatment for the transverse correction of skeletal and dental discrepancies and to reduce crowding.[1] Treatment can result in transverse opening of maxilla, correction of cross bite, and increase in arch length.[2,3]

The rationale of expansion is that opening of expansion screw opens midpalatal suture in growing children.[4] Today various types of expansion appliances are being used.[5-7] Many clinicians rely on rapid or slow palatal expansion appliances to produce maxillary transverse change. Rapid palatal expansion is inefficient because of the intermittent nature of their force of application and is unable to rotate or distalize molars.[8,9] Slow expansion has been suggested to produce the best physiological changes.[10,11]

Many expansion appliances have been used and are studied.[12-15] Many expansion appliances are designed to achieve fully controllable mechanics for slow maxillary expansion like NiTi expander, and SJ expander.

The aim of present study was to compare the expansion changes in the maxillary arch by using two different types of expansion appliances (NiTi expander and the SJ expander) by comparing the difference of intermolar, interpremolar and intercanine width changes and by comparing the three dimensional tooth movements of the first maxillary molars.

Received on 17-10-2020
Accepted on 27-01-2021

MATERIALS AND METHODS

After taking informed consent and ethics approval, present study comprised 50 orthodontic patients selected from the Orthodontics Department. Patient's age ranged from 11 to 14 years of either sex with maxillary bilateral posterior cross bite, mild maxillary arch crowding and having maxillary dentition completed from first molar to the opposite molar, were selected. None of the patients had medical or systemic issues and craniofacial anomalies such as cleft lip or palate.

The study comprised two treatment groups with 25 patients in each group. The group A received treatment with Ni Ti expansion appliances (GAC international, Central I slip, New York) as shown in Figure 1; the group B received treatment with SJ expansion appliances (American Orthodontics, 1714 Cambridge Ave; Sheboygan, WI 53082) as shown in Figure 2. Expansion was continued till over expansion was achieved and after expansion appliance was left in place for 3 months for retention. Complete set of diagnostic records including: standardized lateral cephalometric radiographs, occlusal radiographs, study casts, extra oral and intra oral photographs were taken for every patient before and after the expansion.

Study casts of maxillary arch were marked with 0.3mm lead pencil at points from which measurements were to be taken using vernier caliper (Mitutoyo Corporation, Tokyo, Japan). All measurements were read to the nearest 0.1mm. Pre and post treatment study casts were scanned for the evaluation of maxillary arch widths at canine premolar and molar region, arch perimeter and molar rotation as shown in Figures 3-5. Lateral cephalometric tracings were traced on 0.003 inches thick

and 8x10 inches acetate sheet with a 0.3mm lead pencil. All the radiographs were traced at the same sitting to minimize tracing error. The three dimensional molar movement was measured on cephalogram as given below:

X (Molar distalization): Anteroposterior distance or horizontal measurements from PTV to the distal surface of the maxillary 1st molar.

Y (Molar extrusion): Vertical measurement from palatal plane to the most prominent bulge on the mesial surface of the maxillary 1st molar.

Z (Molar tipping): Angle between the distal surfaces of maxillary 1st molar to Frankfurt horizontal.

Statistical analysis: The data was analyzed in SPSS version 18.0. The arithmetic means, standard deviation, standard error of mean and range for all the quantitative variables was analyzed. Statistical significance was calculated through t- distribution table for comparison.

Figure 1: NiTi Expander

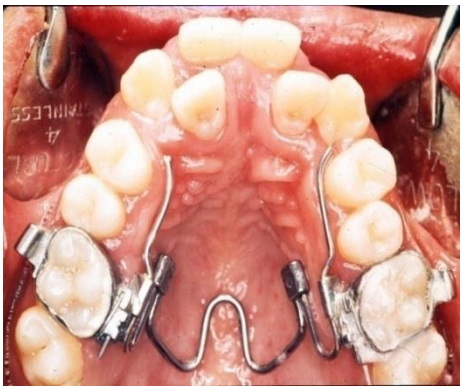

Figure 2: SJ Expander

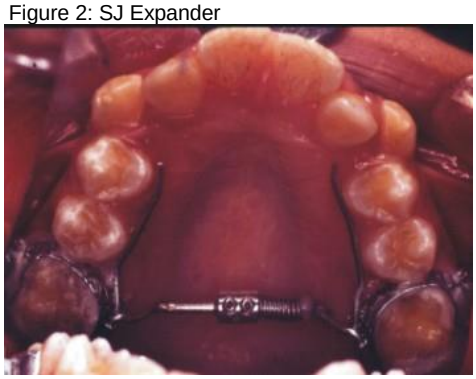

Figure 3: Arch widths measurement



m1 – m2 Intermolar width (From Mesio-palatal cusp tips)
pm1 – pm2 Inter premolar width (From buccal cusp tips)
c-1 –c2 Intercanine width (From canine tips)

Figure 4: Arch perimeter measurement

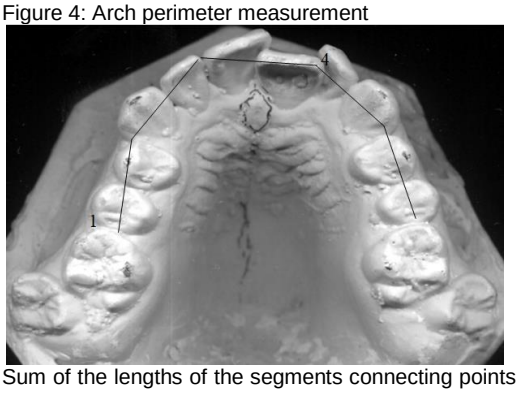

Sum of the lengths of the segments connecting points from medial of first molar to contra lateral mesial of first molar.

Figure 5: Molar rotation measurement

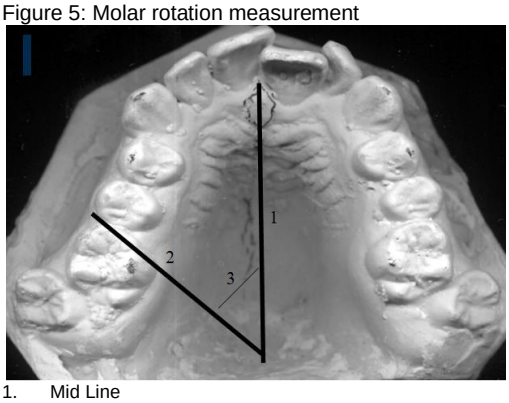

1. Mid Line
2. Line from mesiobuccal and mesiolingual cusp tips to mid line.
3. Angle

RESULTS

Table showed the pretreatment and post treatment changes of the NiTi group and SJ group, the comparison of the expansion changes on dental casts for the values of intermolar width, interpremolar width, intercanine width, maxillary first molar rotation and arch perimeter, and the pretreatment and post treatment changes of the NiTi group and SJ group for the molar tipping, extrusion and distalization.

Table I: Comparison in both the groups after expansion

	Groups	Mean	SD	Std. error mean	P value*
DIFF-Inter molar (mm)	A B	7.22 7.03	1.71 0.72	0.44 0.18	N.S
DIFF-Inter premolar (mm)	A B	4.23 3.10	0.57 1.32	0.14 0.34	P<0.001
DIFF-Inter canine (mm)	A B	1.67 0.27	2.01 0.21	0.51 5.54E-02	P<0.01
DIFF-Arch Perimeter (mm)	A B	6.48 2.01	1.49 0.42	0.38 0.10	P<0.001
DIFF Distalization(mm)	A B	2.56 1.20	3.27 1.36	0.84 0.35	N.S
DIFF-Extrusion (mm)	A B	2.86 1.60	0.58 1.42	0.15 0.36	P<0.001
DIFF-Molar rotation (deg)	A B	0.11 6.21	8.29 4.08	2.14 1.05	P<0.01
DIFF-Tipping (deg)	A B	-1.76 -1.46	1.82 3.93	0.47 1.01	N.S

DISCUSSION

The aim of present study was to compare the expansion changes in the maxillary arch by using two different types of expansion appliances (NiTi expander and the SJ expander). The mean value of the intermolar width of Ni-Ti group in our study was 7.22 ± 1.71 and in SJ was 7.03 ± 0.72 demonstrating that there was no significant difference. Posterior cross bite was corrected in all the patients following expansion. Several studies demonstrated that this change in intermolar width occurs as a result of suture opening, alveolar bone bending, and dental buccal tipping of the posterior teeth. The results are in agreement with another study using slow maxillary expansion protocol[16].

The mean value of the interpremolar width in the Ni-Ti group was 4.23mm±0.57mm and in the SJ group was 3.10mm±1.32mm showing a significant difference as Ni-Ti expander was better as compared to the SJ expander. It is correlated to the study of BeGole et al, 1998 who reported that the expansion at the first premolars in the maxilla for nonextraction cases was up to 4.40mm as a result of expansion of the maxilla and the change in the area is stable[17]. The results of the present study also showed that the ratio of changes in the intermolar width to the interpremolar width was almost same in the two groups. Similar results were also reported by Wertz & Dreskin in 1977 and Cotton in 1978.[18,19]

The mean value of inter canine width in Ni-Ti group was 1.67mm±2.01mm and in the SJ group was 0.27mm±0.21mm demonstrating that change in intercanine width was more in the Ni-Ti group. The increase in the upper intercanine width in both groups was smaller to the intermolar width. This is similar to the other studies.[20,21] The reason may be that the longer treatment time in slow maxillary expansion permits perioral muscles to be more effective on upper canines.

The mean value of gain in arch perimeter in Ni-Ti group was 6.48mm ± 1.49mm and in the SJ group was 2.01mm±0.42mm showing that performance of Ni-Ti group was better. This may be due to the correlation between increase in arch perimeter and increase in interpremolar width which is supported by the study of Adkins et al[22].

The mean value of distalization in the Ni-Ti group was 2.56mm ± 3.27 and in the SJ group was 1.20 ± 1.36 showing a difference of 1.36mm. This showed that the two appliances were not significantly different in distalization of the maxillary first molars. These findings are in agreement with those observed by Ghoshi & Nanda[23].

The mean value of molar extrusion in the Ni-Ti group was 2.86mm ± 0.58 and in SJ group was 1.60mm±1.42 showing a significant difference of 1.26mm with more extrusion in the Ni-Ti group. These results are in consistent to the studies by Haas 1965, Proffit 1986, Ladner & Muhl 1995, and Karaman et al 2002[24-27].

The mean value of molar tip was -1.76º ± 1.8 in the Ni-Ti group and 1.46º ± 3.93 in the SJ group showing a statistically insignificant difference of -0.30º. This showed that SJ group showed less tipping. The reason for the less tipping of molars in the SJ group was may be due to its design in which line of force passed close to the center of resistance of the maxillary teeth.

The mean value of the molar rotation was 0.06º ± 4.74º in the Ni-Ti group and the in the SJ group was 3.55º ± 2.33º indicating that although both the appliances were capable of showing molar rotation but the value of molar rotation was more in the SJ group thus it has more capability of mesiobuccal rotation thus correcting the mesiolingually tilted molars. The results of our study are in consistent with the study by Ciambotti in 2001.[28]

Thus the result of the present study showed that Both Nickel Titanium and Spring Jet expanders are equally capable of palatal expansion. However, there are certain limitations of this study such as preliminary nature of the research, the data presented from cephalometric radiograph is very difficult to generate (due to landmark identification problems and chances of intra observed variability), and 2-D nature of study. Further large scale studies using CBCT methods are suggested.

CONCLUSION

Both Nickel Titanium and Spring Jet expanders are equally capable of palatal expansion and relieving posterior cross bite.

Both appliances produced significant increase in premolar and canine widths.

The Ni-Ti appliance widened the palate more and the gain in arch perimeter was more whereas there was less molar tipping, extrusion and molar distalization by the SJ appliance.

REFERENCES

1. Keerthana SV, Kumar K, Thailavathy V. A Review on Rapid Maxillary Expansion. Indian Journal of Public Health Research & Development. 2019;10(12):2455-60.
2. Naoum S, Goonewardene M, Abbott PV, Karunanayake K, Budgeon C. Changes in pulp blood flow and pulp sensibility resulting from surgically assisted rapid maxillary expansion: A clinical study. American Journal of Orthodontics and Dentofacial Orthopedics. 2019 May 1;155(5):632-41.
3. Angelieri F, Franchi L, Cevidanes LH, Bueno-Silva B, McNamara Jr JA. Prediction of rapid maxillary expansion by assessing the maturation of the midpalatal suture on cone beam CT. Dental press journal of orthodontics. 2016 Dec;21(6):115-25.
4. Giudice AL, Galletti C, Gay-Escoda C, Leonardi R. CBCT assessment of radicular volume loss after rapid maxillary expansion: A systematic review. Journal of clinical and experimental dentistry. 2018 May;10(5):e484.
5. Tepedino M, Iancu-Potrubacz M, Ciavarella D, Masedu F, Marchione L, Chimenti C. Expansion of permanent first molars with rapid maxillary expansion appliance anchored on primary second molars. Journal of clinical and experimental dentistry. 2018 Mar;10(3):e241.
6. Vassar JW, Karydis A, Trojan T, Fisher J. Dentoskeletal effects of a temporary skeletal anchorage device–supported rapid maxillary expansion appliance (TSADRME): A pilot study. The Angle orthodontist. 2016 Mar;86(2):241-9.
7. McNamara JA, Baccetti T, Franchi L, Herberger T. Long-term evaluation of changes in arch dimensions produced by rapid maxillary expansion and fixed appliances. Revista Española de Ortodoncia. 2019;49(1):17-26.
8. Bartok R, Dimitriu B, Vârlan C, Stanciu R, Moldoveanu G, Gagniuc P, Suciu I, Gheorghiu IM, Mitran L, Mitran M, Suciu I. Calculations used for assessment of rapid maxillary expansion. ORL. ro. 2016 Jan 1;9(30).

9. McNamara JA, Baccetti T, Franchi L, Herberger T. Long-term evaluation of changes in arch dimensions produced by rapid maxillary expansion and fixed appliances. Revista Española de Ortodoncia. 2019;49(1):17-26.
10. Naidu S, Suresh A. SLOW PALATAL EXPANSION A NOVEL METHOD OF ARCH EXPANSION. Guident. 2019 Jan 1;12(2).
11. de Almeida AM, Ozawa TO, de Medeiros Alves AC, Janson G, Lauris JR, Ioshida MS, Garib DG. Slow versus rapid maxillary expansion in bilateral cleft lip and palate: a CBCT randomized clinical trial. Clinical oral investigations. 2017 Jun 1;21(5):1789-99.
12. Kapadia RM, Vaghani BR, Shah AM. Comparative evaluation of dental, dentoalveolar and skeletal effects of slow maxillary expansion using Jackscrew, Quadhelix and Niti palatal expander2 on a finite element model of a young skull. Indian Journal of Orthodontics and Dentofacial Research. 2017 Jul;3(3):154-62.
13. Lowe R, Makowka S, Manzella K, Warunek S, Al-Jewair T. Mechanical properties of the NiTi Memoria Leaf Spring Activated Expander (NiTi MLSAE) for maxillary transverse discrepancy correction: An in-vitro study. Journal of Clinical and Experimental Dentistry. 2020 Feb;12(2):e154.
14. de Araújo Gurgel J, Pinzan-Vercelino CR, Leon-Salazar V. Maxillary and mandibular dentoalveolar expansion with an auxiliary beta-titanium arch. American Journal of Orthodontics and Dentofacial Orthopedics. 2017 Oct 1;152(4):543-52.
15. Shah A, Shah P, Goje SK, Shah R, Modi B. Palatal Expansion and its Effects in Orthodontics. Advanced Journal of Graduate Research. 2017 Apr 21;2(1):31-6.
16. Frank SW, Engel GA. The effects of maxillary quad-helix appliance expansion on cephalometric measurements in growing orthodontic patients. American journal of orthodontics. 1982 May 1;81(5):378-89.
17. BeGole EA, Fox DL, Sadowsky C. Analysis of change in arch form with premolar expansion. American journal of orthodontics and dentofacial orthopedics. 1998 Mar 1;113(3):307-15.
18. Wertz R, Dreskin M. Midpalatal suture opening: a normative study. American Journal of Orthodontics and Dentofacial Orthopedics. 1977 Apr 1;71(4):367-81.
19. Cotton LA. Slow maxillary expansion: skeletal versus dental response to low magnitude force in Macaca mulatta. American Journal of Orthodontics and Dentofacial Orthopedics. 1978 Jan 1;73(1):1-23.
20. Akkaya S, Lorenzon S, Üçem TT. A comparison of sagittal and vertical effects between bonded rapid and slow maxillary expansion procedures. The European Journal of Orthodontics. 1999 Apr 1;21(2):175-80.
21. Mossaz-Joëlson K, Mossaz CF. Slow maxillary expansion: a comparison between banded and bonded appliances. The European Journal of Orthodontics. 1989 Feb 1;11(1):67-76.
22. Adkins MD, Nanda RS, Currier GF. Arch perimeter changes on rapid palatal expansion. American Journal of Orthodontics and Dentofacial Orthopedics. 1990 Mar 1;97(3):194-9.
23. Ghosh J, Nanda RS. Evaluation of an intraoral maxillary molar distalization technique. American Journal of Orthodontics and Dentofacial Orthopedics. 1996 Dec 1;110(6):639-46.
24. Haas AJ. The treatment of maxillary deficiency by opening the midpalatal suture. The Angle Orthodontist. 1965 Jul;35(3):200-17.
25. Fields HW, Proffit WR, Case JC, Vig KW. Variables affecting measurements of vertical occlusal force. Journal of dental research. 1986 Feb;65(2):135-8.
26. Ladner PT, Muhl ZF. Changes concurrent with orthodontic treatment when maxillary expansion is a primary goal. American journal of orthodontics and dentofacial orthopedics. 1995 Aug 1;108(2):184-93.
27. Karaman AI, BasçiftçI FA, Gelgör IE, Demir A. Examination of soft tissue changes after rapid maxillary expansion. World Journal of Orthodontics. 2002 Sep 1;3(3).
28. Ciambotti C, Ngan P, Durkee M, Kohli K, Kim H. A comparison of dental and dentoalveolar changes between rapid palatal expansion and nickel-titanium palatal expansion appliances. American Journal of Orthodontics and Dentofacial Orthopedics. 2001 Jan 1;119(1):11-20.