

# Gastric Duplication Cyst Mimicking a Liver Cyst Case Report and Review of the Literature

HUSSAM S. HASSAN<sup>1</sup>, HANY A. ELHADY<sup>2</sup>, MOHAMED SHAWKY ELFARARGY<sup>3</sup>

<sup>1</sup>Department of surgery, college of medicine, Jouf and Tanta University, KSA and Egypt

<sup>2</sup>Department of surgery, college of medicine, Jouf and Al-Azhar University, KSA and Egypt

<sup>3</sup>Department of pediatrics, college of medicine, Jouf and Tanta University, KSA and Egypt

<sup>3</sup>Associate professor of pediatrics, college of medicine, Jouf and Tanta university, KSA and Egypt

## INTRODUCTION

Gastric duplication is a relatively rare congenital anomaly, representing approximately 4-9% of gastrointestinal duplications<sup>1</sup>. It occurs more in females than males<sup>2</sup>. Typically, they are spherical cystic masses along the greater curvature or the posterior aspect of the stomach which are not communicating with its cavity. Less commonly, the anomaly is tubular in shape and has a communication with the stomach. Gastric duplications may be also located along the anterior or posterior wall of the stomach or in the cardia or pylorus<sup>3</sup>.

The spectrum of manifestation of gastric duplication varies in children according to age, and patients may present with abdominal pain, vomiting, bloody stools, feeding difficulties or other nonspecific gastrointestinal symptoms<sup>4,5</sup>.

The preoperative diagnosis of gastric duplication is difficult, and misdiagnosis is common<sup>6</sup>. These lesions maybe misdiagnosed as gastrointestinal stromal tumors, neuroendocrine tumors, neurogenic tumors, and pancreatic heterotopia<sup>7</sup>. The condition may also mimic adrenal cyst<sup>8</sup>, pancreatic cyst<sup>9</sup>, or liver cyst as in this report.

Because gastric duplications can be unexpectedly encountered intra-operatively, the surgeon should be acquainted with this anomaly regarding to anatomy and

clinical characteristics, and its appropriate surgical management<sup>3</sup>.

## CASE REPORT

An 8 years old female child was admitted to emergency unit with abdominal pain and vomiting of 6 days duration without any relevant past medical history related to intake of spoiled or otherwise unhealthy food. There was no history of change in bowel habits or weight loss.

On examination, the patient was found to be mildly to moderately dehydrated. Local examination showed a non-tender vague palpable mass in the epigastric and left hypochondrial regions measuring approximately 10 × 5 cm with restricted mobility. Pediatric and toxicology clearance were obtained.

Ultrasonography examination showed an upper abdominal cystic mass, which was 12x8x2.5 cm in size and was located between the left lobe of the liver and stomach cavity. The radiologist was unable to verify the exact origin or nature of the mass.

A barium meal showed a dilated stomach with manifestations of partial gastric an outlet obstruction. CT revealed a cystic mass occupying the epigastric and left hypochondrial area which is very likely to be a liver cyst protruding from the left hepatic lobe (Fig. 1,2)

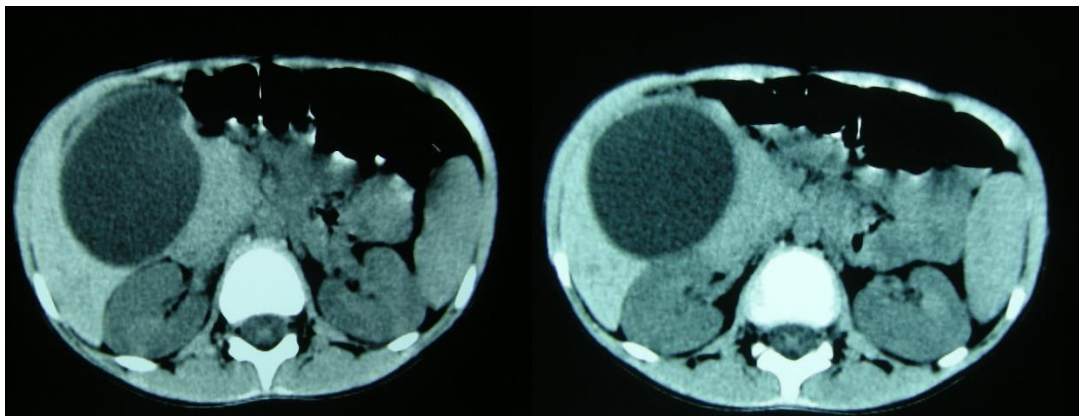


Figure 1

Figure 2

The diagnosis was made as liver cyst compressing the stomach outlet causing partial obstruction.

On laparotomy, the cyst was found to be originating from the greater curvature of the stomach at the pyloro-antral area and encircling almost the entire circumference through both the anterior and posterior surfaces. An aspirate was taken from the cyst. It was mucinous white in nature (Fig.3, 4).

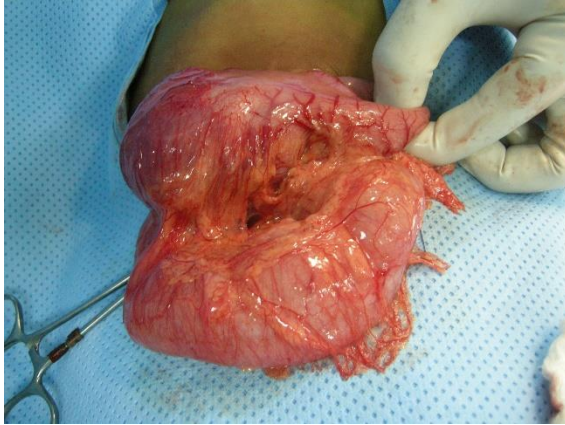


Figure 3

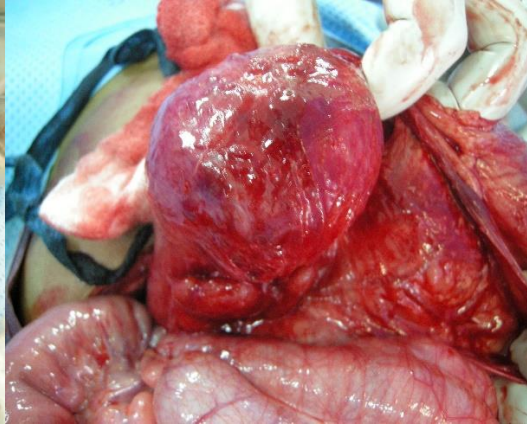


Figure 4

Resection of the swelling and adjoining part of the stomach and repair was done.

The cut surface of specimen revealed a cyst filled with clear mucinous fluid measuring 12 cm and 8 cm in the greatest dimension. The interior wall of cysts was lined by white pink epithelium, and its thickness was approximately 0.4 cm. There was no communication between the cysts and the stomach. (Fig. 5)

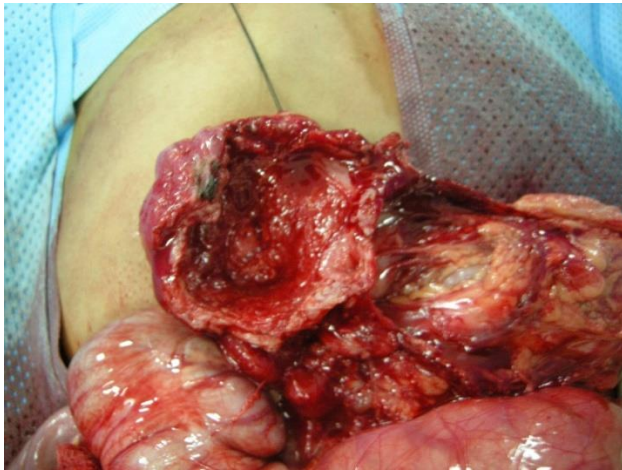

Figure 5

The Patient ran a smooth postoperative course. She was discharged from the hospital on the 11th postoperative day to an outpatient clinic follow up visits scheduled on one week, one month, three month and eight months after surgery

On the follow up visits, the patient showed complete disappearance of preoperative symptoms, with growth and development within the normal percentiles. No post operative wound infection, intestinal obstruction, bleeding or other gastrointestinal complications, such as leakage, occurred.

Histopathological report of the excised cyst revealed that the cyst wall was composed of mucosa, submucosa, and muscularis propria with myenteric plexus. The mucosa was predominantly gastric body type consisting of parietal, chief, and mucus cells with patchy intervening areas of simple columnar epithelium containing apical mucus and

cilia seen in embryonic intestinal epithelium. These findings are consistent with gastric duplication cyst.

## DISCUSSION

Duplication of the GIT is a rare congenital anomaly seen in 1 in every 4500 autopsies<sup>10</sup>. The ileum is the most common site, but this anomaly may occur anywhere in the gut from tongue to anus. Duplication cysts of ileum are usually located on mesenteric border, whereas gastric duplication cysts are usually located on the greater curvature and, to a less extent, on the pyloric antrum leading to manifestations of gastric outlet obstruction<sup>11,12</sup>.

Gastric duplication cysts are rare, representing only 4% of all gastrointestinal duplications and most of them have been reported in children<sup>13</sup>.

Various theories have been proposed to explain the occurrence of GIT duplications. Bremer postulated errors of recanalization and fusion of longitudinal folds, while McLetchie suggested that adhesion of notochord and embryonic endoderm might not elongate as quickly as its surrounding structures, causing traction diverticulum leading to duplication cyst formation. Other theories include abortive twinning, persistent embryological diverticula, and hypoxic or traumatic events<sup>14</sup>.

In the majority of cases (more than 80%), gastric duplications are cystic and do not communicate with lumen of the stomach. The remainders are tubular with some communication<sup>12</sup>.

In our case, the cyst interior was lined with gastric mucosa. Gastric duplications may also contain ectopic pancreatic tissue which may lead to pancreatitis and mimic a pancreatic pseudocyst, ectopic gastric tissues or even pseudostratified columnar ciliated epithelium may be also found in the lesion<sup>15,16</sup>.

The essential criteria for diagnosis of gastric duplication cysts are as follows: I- the whole cyst is contiguous with the stomach wall; II- the cyst is surrounded by smooth muscle, which is continuous with the muscles of the stomach; and III- the cyst wall is lined by epithelium of gastric or any other type of gut mucosa<sup>17,18</sup>.

Gastric duplications typically present early in childhood, with 67% of them are diagnosed within the first

year of life, and less than 25% are discovered after age 12<sup>17</sup>.

Clinically, gastric duplication cysts can have highly variable and nonspecific presentations ranging from ill-defined abdominal pain to nausea, vomiting, epigastric fullness, weight loss, anemia, dyspepsia with abdominal tenderness and epigastric mass on physical examination<sup>19</sup>. The cysts may also present with complications such as infection, gastrointestinal bleeding, perforation, ulceration and fistula formation<sup>20</sup>. The condition may also lead to adhesive obstruction due to mucosa corrosion effect from ectopic gastric acid secretion, or carcinoma arising in the cysts<sup>21,22</sup>. Cases of gastric duplication communicating with the pancreas have been reported as a cause of recurrent pancreatitis<sup>23</sup>.

The wide spectrum of manifestations that mimic a lot of intra-abdominal surgical conditions makes the diagnosis difficult and often it is made after laparotomy, as in our case.

A known feature of gastric duplication cysts is that they may suddenly collapse if they are communicating with the stomach cavity, leading to sudden disappearance of all manifestations leading to a dilemma to reach the correct diagnosis<sup>3</sup>.

Duplication cysts have the potential for neoplastic transformation. However, most of gastric duplication cysts in children reported in the literature are benign, with exception of only one case of gastric adenocarcinoma reported by Min et al<sup>24</sup>.

Ultrasonography is a useful diagnostic modality. It shows the cyst as a hypoechoic cystic mass with a mucosal lining and a muscular ring (muscular ring sign)<sup>25</sup>. However, ultrasonic examination of our case did not help to verify its nature.

Endoluminal ultrasound is useful to verify if the stomach lesion is intramural or extramural. When EUS demonstrates a cyst with an echogenic internal mucosal layer and a hypoechoic intermediate muscular layer, the diagnosis of gastric duplication cyst is highly likely<sup>26</sup>.

Contrast-enhanced CT scan shows the lesion as a thick-walled cystic lesion with enhancement of the inner lining. However, for smaller gastric duplication deformities, the lumen of the cyst is not clear. It may thus be misdiagnosed as a gastric stromal tumor, since strengthened focal cystic wall appears in the abdominal enhanced CT scan<sup>6</sup>. In our case, CT mislead the diagnosis which was only reached during surgery.

Although MRI should provide additional information about the cyst content compared to CT scan, the variable nature of the fluid in the lesion which differs in each case according to bleeding, chronic inflammation, or infection makes MRI seems to be of less significance than expected in diagnosis<sup>27</sup>.

The treatment choice of gastric duplication cysts is complete removal, to avoid the risk of possible complications such as obstruction, torsion, perforation, hemorrhage, and malignancy<sup>19</sup>. A simple cyst without severe inflammatory adhesion can be safely resected laparoscopically. However, laparoscopy-assisted resection by pulling the cyst out through the umbilicus is appropriate for cysts with severe inflammatory adhesion<sup>6,28</sup>.

Removal of the cyst through endoscopic submucosal dissection was also described<sup>29</sup>.

Marsupialization of the cyst to the gastric lumen seems to be an option, however, it exposes the unprotected mucosa of the cyst to gastric contents with the risk of ulceration into the stomach. Drainage procedures such as cystojejunostomy may be complicated by stenosis of the anastomosis or blind loop syndrome. Also, leaving the cyst in place exposes the patient to the hazard of potential malignant transformation<sup>11</sup>. No treatment is usually required for communicating gastric duplications when both gastric lumens are patent<sup>20</sup>.

## CONCLUSION

In conclusion, pediatric gastric duplication is rare and difficult to diagnose. A high index of suspicion is necessary. In doubtful cases of cystic mass in upper abdominal cavity related to the area of the stomach, with vague clinical manifestations and investigations, gastric duplication should be considered.

Surgical resection is the only method of treatment for duplications.

## REFERENCES

1. Azorín-Samper MDC, Fernández-Palop I, Segura-Jiménez MJ, Fernández-Martínez C, Flors-Alandi C, Checa-Ayet F. Gastric duplication cyst in the adult. A case report. *Cir Cir*. 2019; 87(S1):73-76.
2. Xv FY, Sun A, Gan Y, Hu HJ. Gastric duplication cyst mimicking large cystic lymphangioma in an adult: A rare case report and review of the literature. *World J Clin Cases*. 2019 Aug 6;7(15):2087-2093.
3. Hassan RA, Haouim A, Humaida TI, Ouslimane D. Gastric duplication cyst. *Ann Saudi Med* 24(4) 2004
4. Srivastava P, Gangopadhyay AN, Kumar V, Upadhyaya VD, Sharma SP, Jaiman R and Hasan Z: Noncommunicating isolated enteric duplication cyst in childhood. *J Pediatr Surg* 44: e9 e10, 2009
5. Sakamoto K, Hasegawa S, Yamazaki Y, Makino T, Suda T and Imada T: Ileal duplication presenting as perforation: Report of a case. *Surg Today* 30: 445-447, 2000
6. ZHANG L, CHEN Q, GAO Z, et al. Diagnosis and treatment of gastric duplication in children: A case report. *Experimental and Therapeutic Medicine* 14: 3062-3066, 2017
7. Kim SM, Ha MH, Seo JE, Kim JE, Min BH, Choi MG, et al. Gastric duplication cysts in adults: a report of three cases. *J Gastric Cancer*. 2015;15:58–63
8. Castillo-Fernández AL, Vázquez-Rueda F, Cañete MD, Caballero-Villarraso J. Retroperitoneal gastric duplication mimicking a prenatal adrenal cyst. *Congenit Anom (Kyoto)*. 2018 Jul;58(4):141-142
9. Bailey CE, Fritz MB, Webb L, Merchant NB, Parikh AA. Gastric duplication cyst masquerading as a mucinous pancreatic cyst: case report and literature review. *Ann R Coll Surg Engl*. 2014 Jan;96(1):88E-90E.
10. Potter EL. *Pathology of the Fetus & Newborn*. Chicago: Year Book Medical Publishers; 1961.
11. J. Johnston, G. H. Wheatley, H. F. El Sayed, W. B. Marsh, E. C. Ellison, and M. Bloomston, "Gastric duplication cysts expressing carcinoembryonic antigen mimicking cystic pancreatic neoplasms in two adults," *American Surgeon*, vol. 74, no. 1, pp. 91–94, 2008
12. S. Murakami, H. Isozaki, T. Shou, K. Sakai, and H. Toyota, "Foregut duplication cyst of the stomach with

- pseudostratified columnar ciliated epithelium," *Pathology International*, vol. 58, no. 3, pp. 187–190, 2008
13. Lyu XT, Pang XL, Wu L, Wang LB. Diagnosis of gastric duplication cysts in a child by endoscopic ultrasonography. *Chin Med J (Engl)*. 2019 Feb;132(4):488-490.
  14. ID.Passos, G.Chatzoulis, K.Milias, E.Tzoi, C.Christoforakis, P.Spyridopoulos. Gastric duplication cyst (gdc) associated with ectopic pancreas: Case report and review of the literature. *International Journal of Surgery Case Reports*. Vol 31, 2017, P 109-113
  15. García Nebreda M, Paseiro Crespo G, Álvaro Cifuentes E, Marqués Medina E, Burdaspal Moratilla A. Gastric duplication cyst with respiratory epithelium: An uncommon injury that has a difficult differential diagnosis. *Cir Esp*. 2019 Jan;97(1):57-59.
  16. Falletti J, Vigliar E, Zeppa P, Schettino P, Napolitano V, D'Armiento M. Gastric Duplication Cyst: A Rare Congenital Disease Often Misdiagnosed in Adults. *Case Reports in Gastrointestinal Medicine*. 2013; 2013:850967. doi: 10.1155/2013/850967. Epub 2013 Feb 12
  17. Johnston J, Wheatley GH 3rd, El Sayed HF, Marsh WB, Ellison EC, Bloomston M. Gastric duplication cysts expressing carcinoembryonic antigen mimicking cystic pancreatic neoplasms in two adults. *Am Surg*. 2008;74:91–4.
  18. Horne G, Ming-Lum C, Kirkpatrick AW, Parker RL. High-grade neuroendocrine carcinoma arising in a gastric duplication cyst: a case report with literature review. *Int J Surg Pathol*. 2007;15:187–91.
  19. K. Mardi, V. Kaushal, and S. Gupta, "Foregut duplication cysts of stomach masquerading as leiomyoma," *Indian Journal of Pathology and Microbiology*, vol. 53, no. 1, pp. 160–161, 2010.
  20. X. B. D'Journo, V. Moutardier, O. Turrini et al., "Gastric duplication in an adult mimicking mucinous cystadenoma of the pancreas," *Journal of Clinical Pathology*, vol. 57, no. 11, pp. 1215–1218, 2004.
  21. Karnak I, Ocal T, Senocak ME, Tanyel FC and Büyükpamükcü N: Alimentary tract duplications in children: Report of 26 years' experience. *Turk J Pediatr* 42: 118-125, 2000.
  22. Schalamon J, Schleef J and Höllwarth ME: Experience with gastro-intestinal duplications in childhood. *Langenbeck's Arch Surg* 385: 402-405, 2000
  23. Hoffman M et al. Gastric Duplication Cyst Communicating with Aberrant Pancreatic Duct: a rare cause of recurrent acute pancreatitis *Surgery*. 1987; 101:369.
  24. Min SH, Kim HY, Kim SH, Jung SE, Park KW, Kim WS and Park SH: Gastric adenomyoma mimicking gastric duplication cyst in a 5-year-old girl. *J Pediatr Surg* 47: 1019-1022, 2012
  25. Barr LL, Hayden CK, Stansberry SD, et al. Enteric Duplication Cysts in Children: Are their ultrasonographic wall characteristics diagnostic? *P ed iatr R adiol*. 19 90 ;2 0 :326-328
  26. Lyu T, Pang XL, Wu L, Wang LB. Diagnosis of gastric duplication cysts in a child by endoscopic ultrasonography. *Chin Med J (Engl)*. 2019 Feb;132(4):488-490.
  27. H. Maeda, T. Okabayashi, I. Nishimori et al., "Diagnostic challenge to distinguish gastric duplication cyst from pancreatic cystic lesions in adult," *Internal Medicine*, vol. 46, no. 14, pp. 1101–1104, 2007.
  28. Gupta V, Javaid U, Jaber G, Mohd D, AlMarzouqi M. Laparoscopic Resection of Isolated Retroperitoneal Gastric Duplication Cyst in an Infant. *J Coll Physicians Surg Pak*. 2019 Dec;29(12):S141-S143
  29. Fang Y, Gao T, Yang H, Ma S, Li Q, Zhou PH. Removal of an infant's gastric duplication cyst through endoscopic submucosal dissection: A case report. *Medicine (Baltimore)*. 2019 Mar;98(12):e14820