

## **Precordial ST-Segment Elevation Caused by Occlusion of Non-Dominant Right Coronary Artery PDA Branch; a case report**

HOSSEIN SHEIBANI<sup>1</sup>, ELHAM AZMOODEH<sup>2</sup>, AMIR HESSAM KHEIRIEH<sup>2</sup>

<sup>1</sup>Vice-chancellery of Treatment, Shahrood University of Medical Sciences, Shahrood, Iran

<sup>2</sup> Student Research Committee, School of Medicine, Shahrood University of Medical Sciences, Shahrood, Iran

Correspondence to Hossein Sheibani

### **ABSTRACT**

In acute ST-segment elevation myocardial infarction, primary percutaneous coronary intervention to the culprit lesion via electrocardiographic guidance is essential. We herein report the incomparable case of 44years old woman who presented with ST segment elevation in the precordial leads, while coronary angiography results indicated total occlusion of the non-dominant right coronary artery PDA branch. We reported our observations in coronary angiography and electrocardiographic data and its changes after PCI and evaluated its possible pathophysiologic mechanisms.

**Keyword:** Coronary angiography, myocardial infarction, PDA branch, total occlusion, precordial leads ST-segment elevation

---

### **INTRODUCTION**

ST-segment elevation in precordial electrocardiogram leads is characteristic of anterior wall or anteroseptal wall infarction. However, it is rarely observed in patients with proximal right coronary occlusion. In the latter scenario, patients may either have ST-segment elevation in the anterior leads alone or in both the anterior and inferior leads. These are reported to be associated with proximal right coronary artery (RCA) occlusion and right ventricular (RV) infarction, and even with isolated RV branch total occlusion. Although there are reported rare cases of patients with ST-elevation myocardial infarction (STEMI) who presented with ST-segment elevation in the precordial V1-V3 leads, but angiography results revealed total occlusion of the proximal RCA but We report a special case of a patient with ST-segment elevation in precordial V2-V5 leads, but angiography results revealed total occlusion of the PDA branch of RCA.

### **CASE REPORT**

A 44-year-old previously healthy female nonsmoker was referred to our hospital from local health center with this history that she had admitted due to one-episode typical chest pain with cold sweats and ST-segment elevation in V2-V5 in the local health center. Patient treatment was done by TNG pearl in local health center. Chest pain was subsided with pearl near completely and ST segment elevation significantly decreased in that center. The patient was referred to our hospital that admitted in our center after 2 hours while she had no chest pain but had mild chest heaviness. Upon physical examination, the patient showed no hypotension, tachypnea, desaturation, jugular vein engorgement, cardiac murmur, abnormal breath sounds, or peripheral edema. The result of electrocardiography (ECG) earlier performed in local health center showed ST-segment elevation in V2-5 (FigureE.1). The ECG performed in our emergency department then demonstrated no ST segment elevation but had inverted T wave in V2-V5 leads (Figure E.2). The first troponin in emergency room was positive and TTE results showed EF=55% without significant RWMA (FigureT.1).We decided

to medical treatment in CCU, and administered a 300mg loading dose of clopidogrel (prasugrel and ticagrelor are not available in this center) and 300 mg of aspirin after 4000 units of intravenous heparin. During 48 hours medical management at CCU she hadn'tchest pain and new dynamic ECG change (Figure E.3-6).

Coronary angiography was done in 3th day. CAG's results demonstrated left and right side co-dominant coronary arteries. LAD has no significant stenosis but was narrow vessel from importation with good run off.

Left circumflex artery (LCX) gave rise to left posterior descending artery to supply to posterior, lateral, wall and inferior walls. With the first injection in RCA, This vessel was dissected from origin to mid-portion with very slow flow with good distal delay run off. successful stenting was done in RCA from origin to mid-portion with 2stent Resolute onyx 3\*38 and 3.5\*38 and the final result was slow good flow at RCA and PLB with delay timi 2 flow in PDA, The first RV branch at RCA mid-portion was occluded after stenting that was reason for new mild ST-Segment elevation in II, III, AVF, RV4 (FigureC.1). Because the patient was symptom free and ST elevation in inferior leads and RV4 remained without dynamic change, the patient transfer to post-cath unit after 4 hours with no symptom and stale good vital signs(FigureE.7).2 hours later patient complained from paroxysmal severe chest pain that lead to sustained symptomatic VT that returned to sinus rhythm with 360 Jull monophasic shock(FigureE.8).ECG was done immediately that had fixed ST elevation similar to prior ECG but had new significant ST elevation in V2-5 similar to ST elevation in 1th ECG(FigureE.9). During 10 minutes observation despite IV nitrate therapy with high dose chest pain and ST elevation was progressive(FigureE.10).TTE was done again that demonstrated anteroseptal severe HK, inferior wall HK and mild systolic RV dysfunction(FigureT.2). We decided for repeating of CAG. In 2th CAG left terraria had no new stenosis and was similar to prior CAG.RCA,2th RV branch and PLB had good flow but PDA was completely occluded.

Immediately after wearing of RCA and ballooning of its PDA and establishing good flow in PDA (Figure C.2).

Chest pain near completely and precordial ST-Segment elevation returned to near baseline too (Figure E.11).

The patient was undertreated by Nitrate, Anticoagulant, ASA, Clopidogrel and Atorvastatin in CCU for 7 days. There were short episodes of 2 to 1 block in this period (Figures E.12). A final follow up electrocardiogram showed complete resolution of the ST-segment elevation over the V2-V5 leads without Q wave but with poor R progression and Q wave in inferior leads (Figure E.13).

At final the patient discharged with good general condition, stable vital signs and EF=50%. The patient's peak troponin I level was 15 ng/mL, while peak creatinine phosphokinase (CPK) level with the creatinine kinase muscle-brain fraction (CK-MB) were 200 IU/L and 48 ng/mL (24%). (First and second coronary angiography always are available for observation on: <http://s3.picofile.com/file/8372655718/Patient.zip.html>).

## DISCUSSION

Typically, the ECG results in RCA occlusion show ST-segment elevation in leads II, III, and aVF. Sometimes, the test results may present concomitant ST elevation in the precordial and inferior leads, but rarely in the precordial leads alone. According to previous literature, simultaneous involvement of both the anterior and inferior leads is attributed to occlusion of the proximal RCA<sup>1</sup>, while isolated ST elevation in the precordial leads has been reported to result from isolated RV branch occlusion<sup>2</sup>, proximal RCA occlusion with good collateral flow to the left coronary arteries<sup>3,4,5</sup>, or proximal RCA occlusion with predominant damage originating from the RV wall rather than the inferior wall<sup>6</sup>. Similarly, a diseased dominant RCA with extreme cardiac counter-clockwise rotation was also discussed.

In addition to the above electrocardiographic patterns, Nanavati et al. described a totally occluded RCA that presented with a normal electrocardiogram due to the existence of a Sub-Endocardial microvascular network<sup>7</sup>. This means that in cases of RCA occlusion, the ECG results may present as ST elevation of the precordial leads or with normal ST segments in the inferior leads instead of the typical II, III, and aVF ST elevation. Our patient presented with isolated ST-segment elevation in V2-V5, and coronary angiography results showed PDA branch of RCA occlusion without collateral arteries from the left coronary arteries. This scenario showed some differences from previous case reports.

Because of less RCA territory, the inferior wall was dominantly supplied by the LCA. The typical inferior lead ST-segment elevation may not have been significantly present for non-dominant RCA. Furthermore, the electrical effect may have been neutralized by the reciprocal change of precordial ST-segment elevation.

Isolated RV infarction is rare, and accounts for less than 3% of all patients with myocardial infarction<sup>8</sup>. A review of prior reports shows that it can occur in any of the following situations: acute loss of RV branch during coronary angioplasty of the RCA<sup>9,10</sup>, occlusion of a non-dominant RCA<sup>11</sup>, or acute occlusion of the proximal RCA, with a patent protecting collaterals from other vessels<sup>3,4,5</sup>, RVMI usually occurs with simultaneous inferior wall infarction. The dominant electric forces generated by the

ischemia of the inferior wall suppress the changes caused by the ischemia of the RV. On the other hand, in patients with non-dominant RCA, infarcted RV predominated electric forces and presented ST segment elevation in precordial leads.

The absence of Q-wave development in the anterior leads and progressive reduction in ST-segment elevation across the precordial leads have been reported as favoring the diagnosis of RVMI<sup>12</sup>. Lopez-Sendon et al<sup>13</sup>. Described ST-segment elevation in V4R higher than V1-V3 indicated RVMI. Although these ECG features were helpful, they were not sufficiently specific for our purposes. It was impossible to make this distinction on the basis of ECG alone.

To the best of our knowledge, this is the first reported case of "anterior ST segment elevation" caused by occlusion of PDA branch of "non-dominant" RCA. In this case angiography results showed significant narrowing in mid-part of LAD with good distal run off and she had ST segment elevation in V2-V5 either prior and later time that was both times associated with chest pain, cold sweating, positive troponin; but return to base line with oral and IV nitroglycerin intake subsequently; then we can describe other mechanism for precordial ST segment elevation that maybe was the most probably in this case. That mechanism is spasm induction in LAD mid-part due to two separate cause means drugs induce and ischemia induce subsequently.

## CONCLUSIONS

In summary, anterior ST-segment elevation for occlusion of the PDA branch of RCA hasn't been reported, and some underlying mechanisms have been proposed. Early recognition of this scenario and subsequent initiation of the appropriate management may change the outcome of the disease.

## REFERENCES

1. Jim MH, On-On Chan A, Wong CP, Yiu KH, Miu R, Wai-Luen Lee S, et al. Clinical Implications of Precordial ST-segment Elevation in Acute Inferoposterior Myocardial Infarction Caused by Proximal Right Coronary Artery Occlusion. *Clinical Cardiology: An International Indexed and Peer-Reviewed Journal for Advances in the Treatment of Cardiovascular Disease*. 2007;30(7):331-5.
2. Vavuranakis M, Drakopoulou M, Toutouzas K, Polychronis D, Stefanadis C. Right ventricular infarction mimicking anterior infarction. *Annals of noninvasive electrocardiology*. 2006;11(2):194-7.
3. Cafri C, Orlov G, Weinstein JM, Kobal S, Ilia R. ST elevation in the anterior precordial leads during right ventricular infarction: lessons learned during primary coronary angioplasty: a case report. *Angiology*. 2001;52(6):417-20.
4. Kida M, Morishita H, Yokoi H, Yoshinaga M, Yasumoto H, Kimura T, et al. Precordial ST-segment elevation caused by right coronary artery occlusion. *Journal of cardiology*. 1987;17(3):455-64.
5. Muhammad KI, Kapadia SR. Anterior ST-segment elevation with right coronary artery occlusion: a unique case of isolated right ventricular infarction. *Angiology*. 2008;59(5):622-4.
6. Triantafyllis DG, Vrahatis A, Zaharoulis A. Electrocardiographic picture of acute anterior infarction due to proximal obstruction of the right coronary artery. *Hellenic J Cardiol*. 2005;46:154-7.

7. Nanavati VI, Knapp AL, Passelaqua S. A totally occluded right coronary artery presenting with a normal electrocardiogram. *The Journal of invasive cardiology*. 2003;15(6):355-8.
8. Kinch JW, Ryan TJ. Right ventricular infarction. *New England Journal of Medicine*. 1994;330(17):1211-7.
9. Hilliard AA, Nkomo VT, Mathew V, Prasad A. Isolated right ventricular infarction—an uncommon cause of acute anterior ST segment elevation. *International journal of cardiology*. 2009;132(2):e51-e3.
10. Nabais S, Martin-Yuste V, Masotti M, Sabaté M. Isolated right ventricular infarction presenting with anterior ST-segment elevation: A case for careful assessment of right ventricular branch occlusion. *Revista Portuguesa de Cardiologia*. 2012;31(4):301-4.
11. Gregory SA, Desai AS, Fifer MA. Isolated right ventricular infarction resulting from occlusion of a nondominant right coronary artery. *Circulation*. 2004;110(20):e500-e1.
12. Geft IL, Shah PK, Rodriguez L, Hulse S, Maddahi J, Berman DS, et al. ST elevations in leads V1 to V5 may be caused by right coronary artery occlusion and acute right ventricular infarction. *The American journal of cardiology*. 1984;53(8):991-6.
13. Lopez-Sendon J, Coma-Canella I, Alcasena S, Seoane J, Gamallo C. Electrocardiographic findings in acute right ventricular infarction: Sensitivity and specificity of electrocardiographic alterations in right precordial leads V4R, V3R, V1, V2 and V3. *Journal of the American College of Cardiology*. 1985;6(6):1273-9.

Figure E1: The result of electrocardiography (ECG) performed in local health center showed ST-segment elevation in V2-5

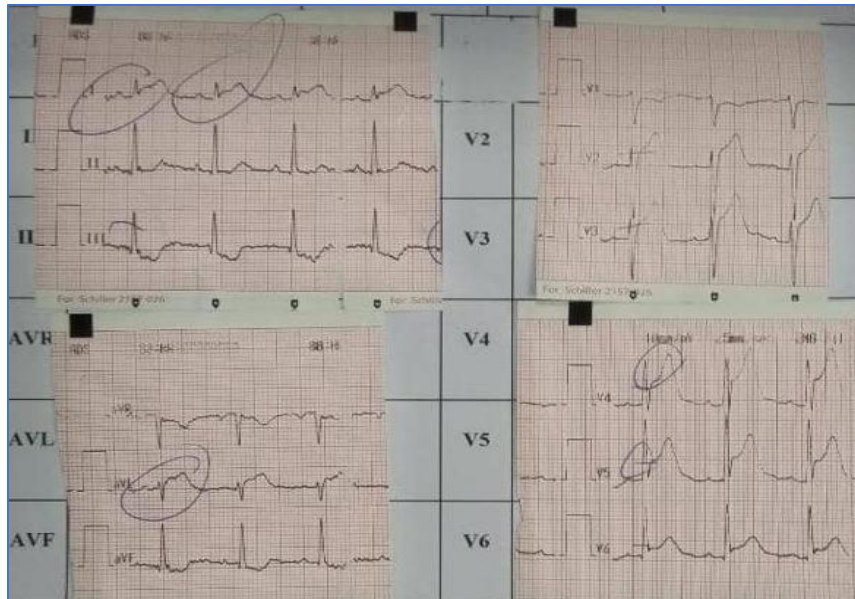


Figure C1: First coronary angiography was done in 3th day and demonstrated; A: LAD has no significant stenosis but was narrow vessel from importation with good run off. B: With the first injection in RCA, this vessel was dissected from origin to mid-portion with very slow flow with good distal delay run off.

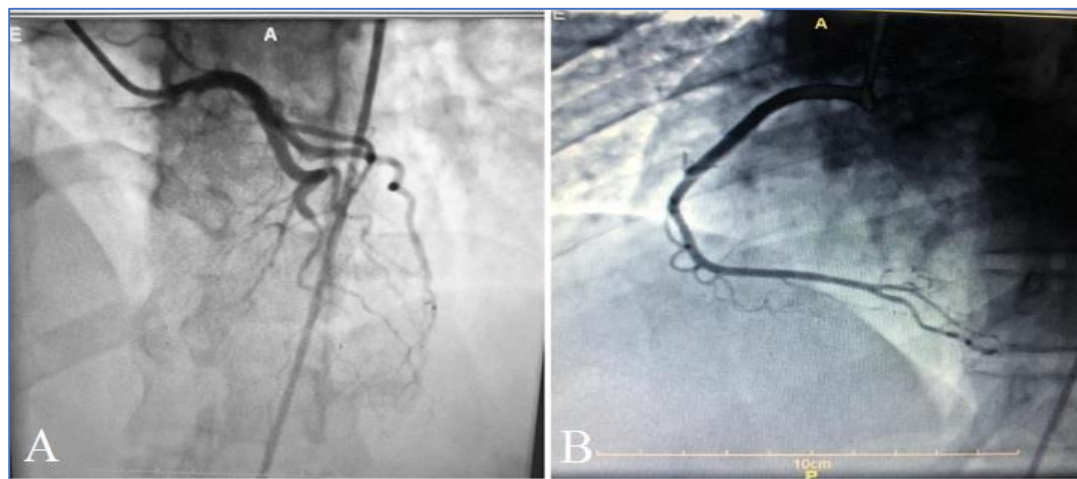


Figure E.2: The ECG performed in our emergency department then demonstrated no ST segment elevation but had inverted T wave in V2-V5 leads

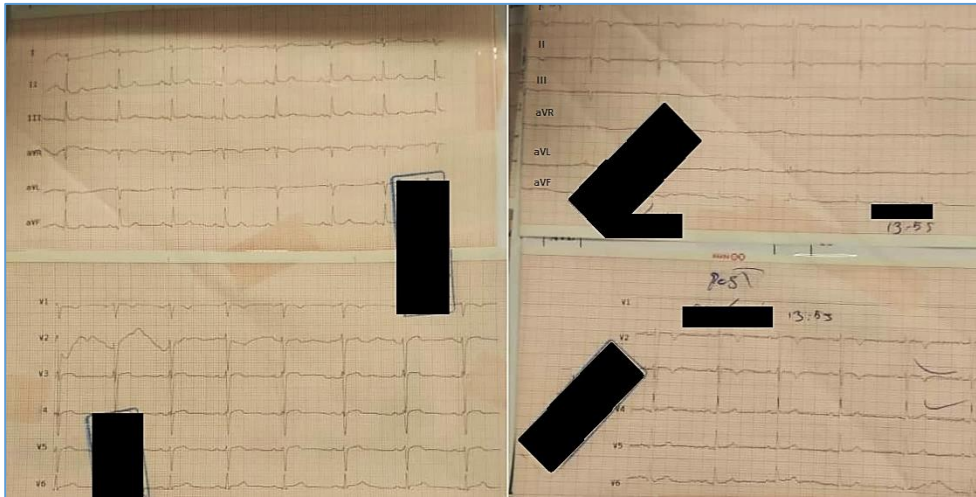
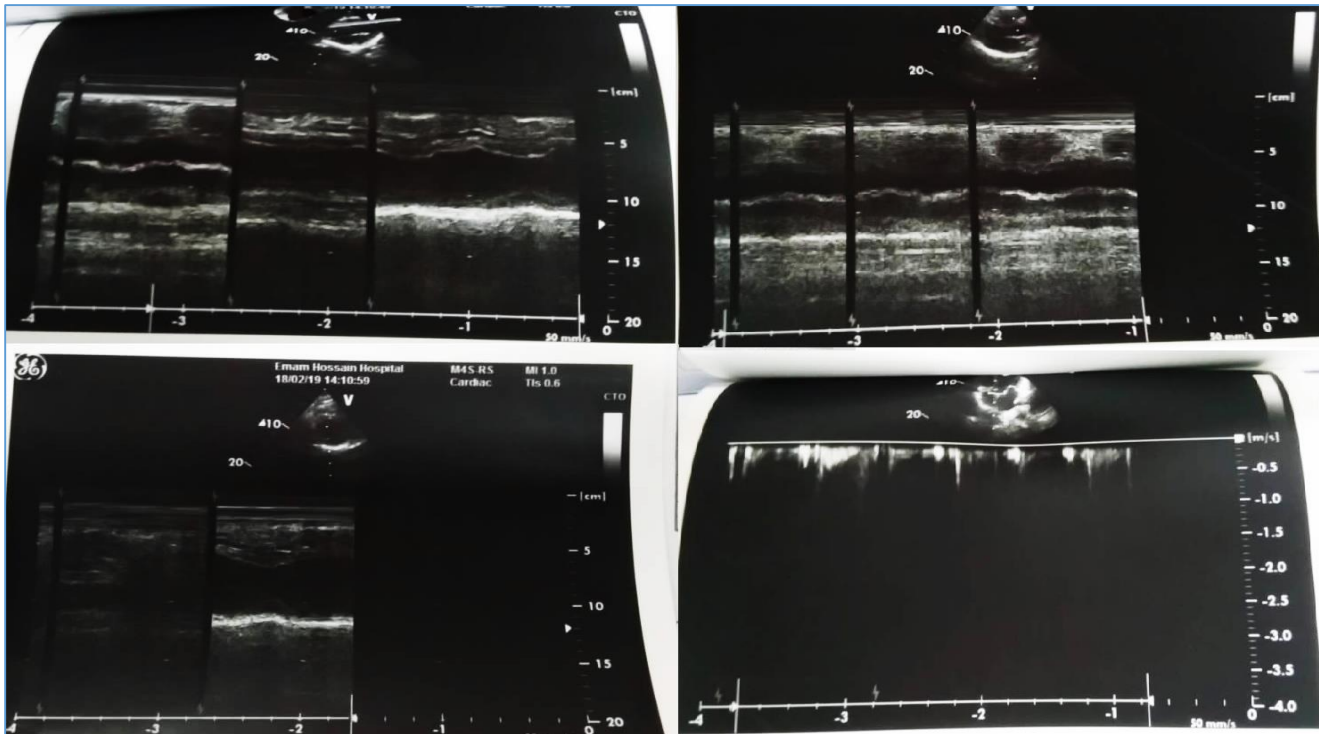


Figure T.1: Transesophageal echocardiography (TTE) results showed EF=55% without significant RWMA.





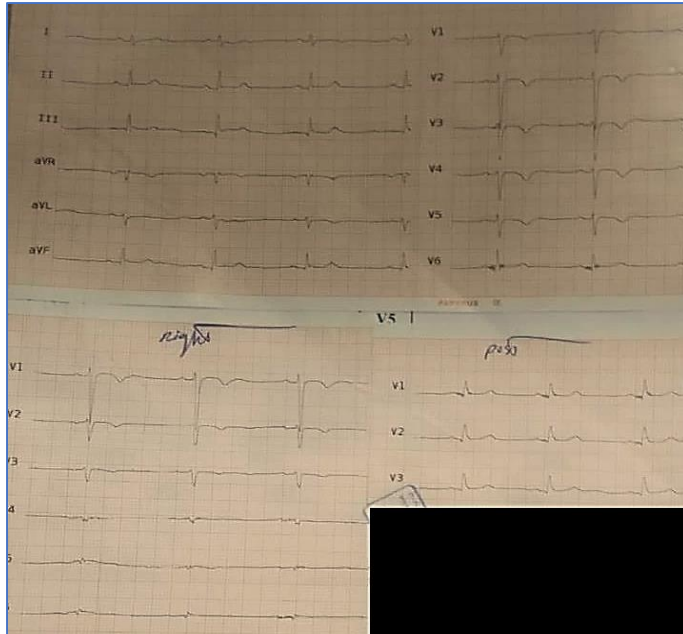


Figure E.3: When the patient transfer to CCU, an ECG was taken upon arrival.

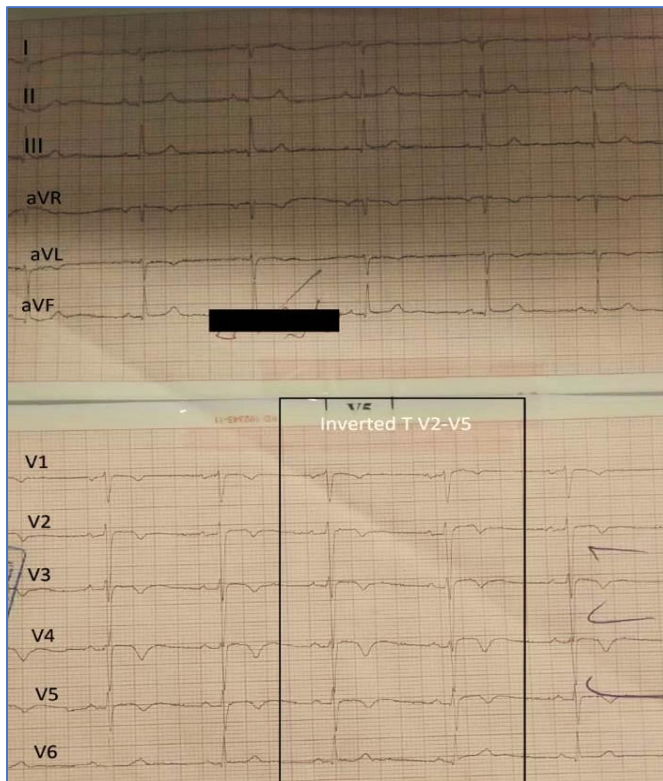


Figure E.6: An ECG was taken just before Coronary angiography and revealed inverted T on V2-V5.

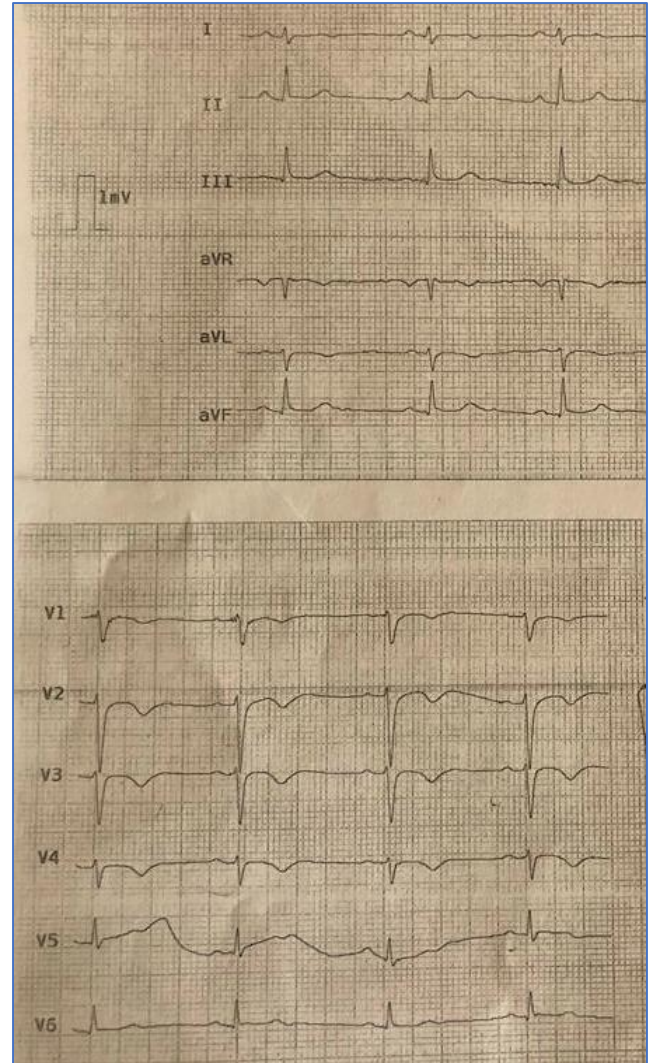


Figure E.4: In first day in CCU, the patient had chest pain, an ECG was taken among it immediately.

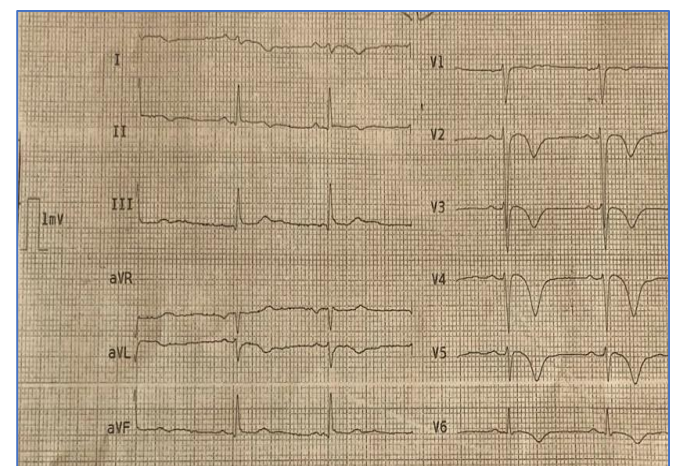


Figure E.5: ECG at CCU in second day.

Figure E.9: After sustained symptomatic VT that returned to sinus rhythm, new significant ST elevation found in V2-V5 similar to ST elevation in 1th ECG

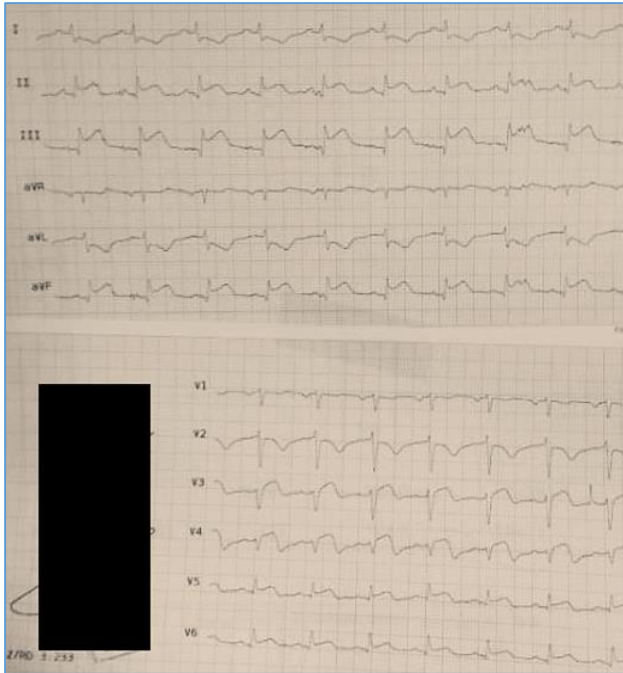


Figure E.7: When the patient transfer to post-cath unit after 4 hours, an ECG was taken and showed ST elevation had remained despite CAG.

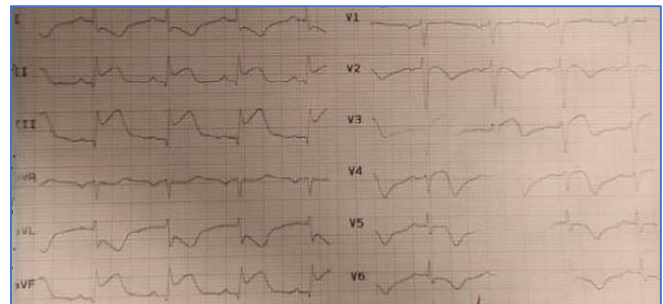


Figure E.10: Another ECG was taken after 1 hour from CAG in post-cath unit

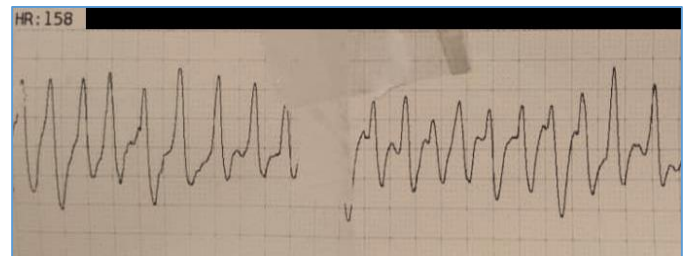


Figure E.8: The patient complained from paroxysmal severe chest pain that lead to sustained symptomatic

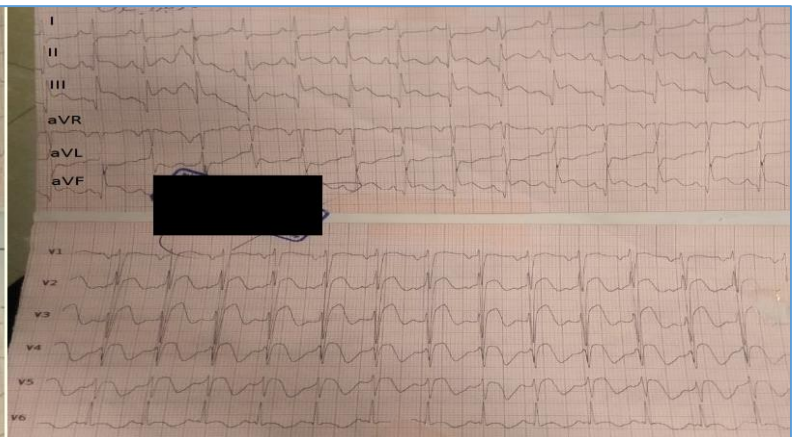
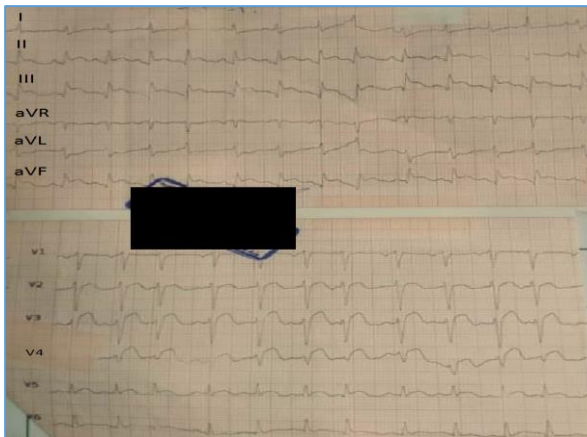


Figure E.12: There was short episodes of 2 to 1 block in CCU after second CAG

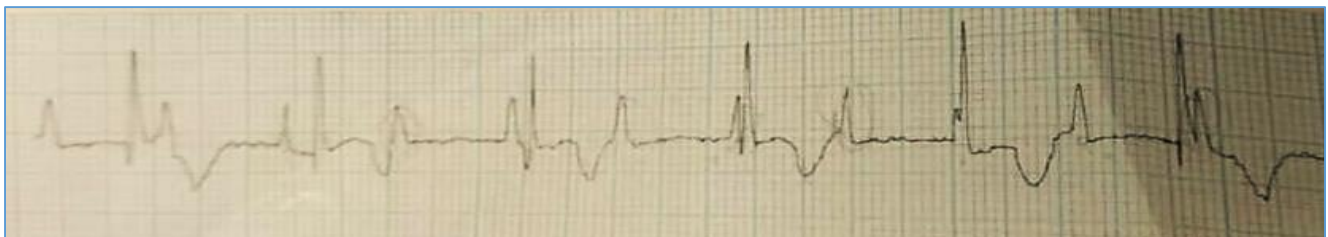




Figure E.11: After second CAG, ECG showed precordial ST-Segment elevation has returned to near baseline.

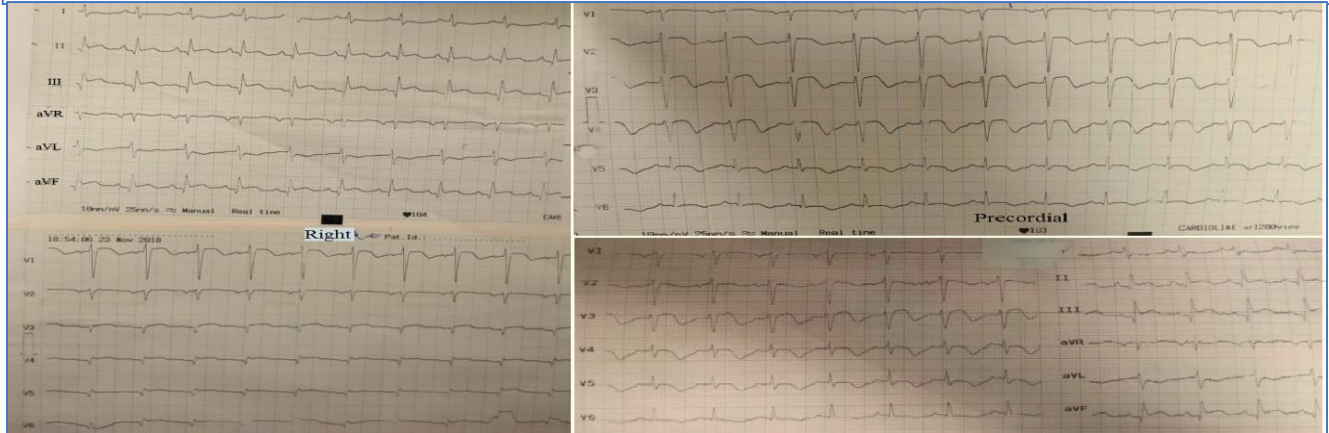


Figure E.13: A final follow up electrocardiogram showed complete resolution of the ST-segment elevation over the V2-V5 leads without Q wave but with poor R progression and Q wave in inferior leads. A: Second day's ECG after second CAG. B: Third day's ECG after second CAG. C and D: Fourth day's ECG after second CAG.

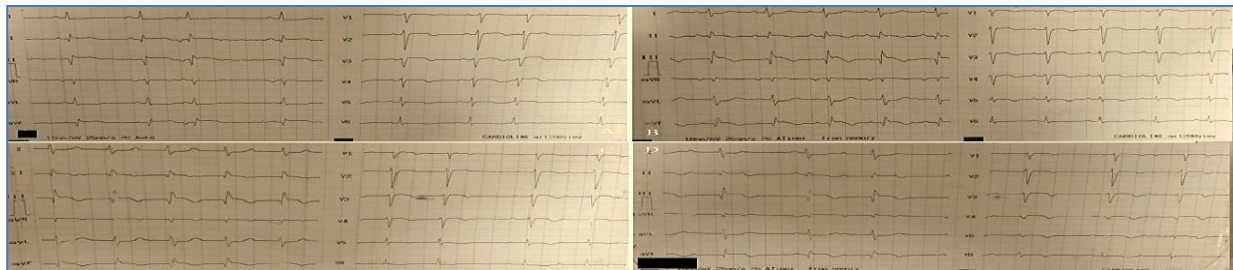

Figure T.2: Transthoracic echocardiography was done again that demonstrated anteroseptal severe HK, inferior wall HK and mild systolic RV dysfunction.

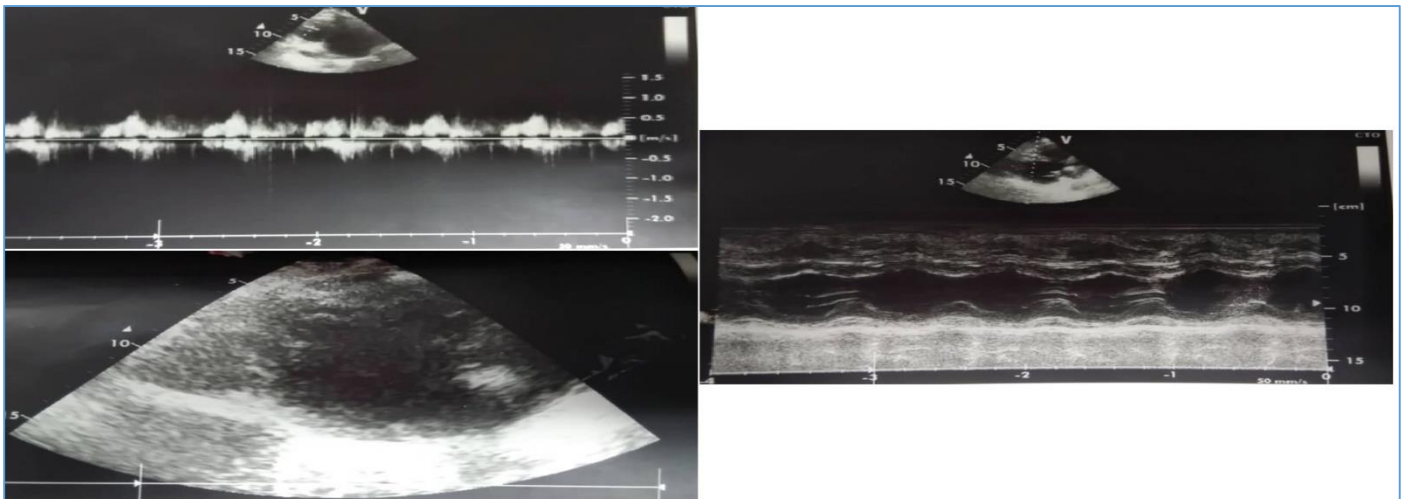


Figure C.2: We decided for repeating of CAG. In 2th CAG, A: Final injection after dissection stenting showed complete RCA flow in distal branches. B: Left injection at second angiography after VT treatment with shock, chest pain and with ST elevation showing that there was no clear new stenosis in the left coronary heart despite the aforementioned symptoms and findings. C: PCA injection in second angiography showed no significant flow in PDA. D: Wearing of PDA caused flow in this branch, immediately the patient's chest pain disappeared and also ST segment nearly returned to isoelectric line

