

Canine Transmigration and Associate Dental Anomalies – an Orthodontic and Oral Maxillofacial Surgery Study

MUHAMMAD AZEEM¹, SANA KANWAL², SOBIA KHALID³, MUHAMMAD MUDASSAR SALEEM⁴, HINA MUKHTAR⁵
USMAN SHAKOOR⁶

¹Assistant Professor Orthodontics, Faisalabad Medical University/PMC, Faisalabad, Pakistan.

^{2,3}Ex-House Officer, de'Mont Dental College, Lahore, Pakistan.

⁴Assistant Professor OMFS, IMDC, Islamabad, Pakistan.

⁵MCPS Orthodontics, de'Mont Dental College, Lahore, Pakistan.

⁶Resident, de'Mont Dental College, Lahore, Pakistan.

Correspondence: Dr Muhammad Azeem, Email: dental.concepts@hotmail.com Cell: 0345-8409007

ABSTRACT

Aim: To find difference of occurrence of dental anomalies between the patients with transmigrated lower arch canines with normal.

Methods: Present study was conducted after involving pre-treatment records of 20 patients with mandibular canine transmigration (Transmigration group: TG) and were compared with 100 normal patients with normally erupted canines (control group: CG). Intergroup differences were determined using χ^2 tests.

Results: Results showed that 12 were of type 1, while type 2 and type 3 patterns were shown by 4 canines each. Intergroup differences were insignificant.

Conclusion: It was concluded that no significant association was found between various categories of dental anomalies with mandibular canine transmigration.

Keywords: Transmigration; Canine; Dental anomalies

INTRODUCTION

Tooth impaction is infrabony placement beyond the time, whereas the anomalous abnormal placement is known as displacement¹. The term "Transmigration" refers to intraosseous migration of unerupted teeth across the midline, which causes aesthetic and functional issues in occlusion². Transmigration can be defined in several ways: According to Javid transmigration is when >half tooth has passed the midline³, as per Mupparapu transmigration is when >half tooth crown has crossing the midline⁴, and according to Tarsitano it is midline crossing⁵.

The most common tooth affected by dental transmigration is lower canine. Regarding aetiology of transmigration there is no exact cause reported⁶. Transmigrated canines are usually on one side and without symptoms, but can be accompanied by cyst or odontoma in rare cases. Prevalence rates of transmigrated canines reported are 0.33% to 0.46% in different populations^{7,8,9}.

To our knowledge, very few studies have done on association of dental anomalies in transmigrated canines. Excess tooth material has been linked to transmigrated mandibular canines.¹⁰ Therefore aim is to determine the difference of occurrence of dental anomalies between the patients with transmigrated lower arch canine with normal.

MATERIALS AND METHODS

This study was conducted after ethics approval at the Department of Orthodontics and Oral & Maxillofacial Surgery from data of June 2016 to June 2019. Following patients were selected: No Hypodontia, age 16 and 30 years, both the genders, and good quality OPGs. Following patients were excluded: craniofacial syndromes and

orofacial clefts, history of dental extractions or trauma, significant medical history, gross caries and history of prior orthodontic treatment.

A tooth was considered impacted if patient age was more than 16 years, having complete root formation on radiographs and remained in infrabony position 2 years beyond the expected eruption time^{11,12}. A canine was considered transmigrated if it was migrated to other side of midline with any amount of distance and was classified as in Table 1¹³.

20 subjects (12 girls and 8 boys) diagnosed with mandibular canine transmigration as per defined criteria were selected in the transmigration group (TG). All the subjects had a chronologic age between 16 and 30 years. For the control group (CG), 100 pre-treatment diagnostic records were included, of patients undergoing orthodontic treatment at our orthodontic department (52 girls and 48 boys). Following dental anomalies were assessed from dental model analysis and verified radiographically¹³⁻¹⁵.

- Shape anomalies: Peg laterals, dens in dentine; etc
- Number anomalies: Hypodontia or hyperdontia
- Structural anomalies: Amelogenesis or dentinogenesis imperfecta, any structural defect of enamel or dentine.
- Positional anomalies: Ectopia, impaction (other than third molars), and rotation (at least 20).

Statistical analysis: Data consisting of gender, chronologic age and dental anomalies were compiled. Age comparison between the groups was done using *t*-test. Intergroup differences were assessed using χ^2 test (Fisher exact test).

RESULTS

Out of 20 subjects having transmigrated mandibular canines, 12 were females (mean age: 22.11 years) and 8

Received on 30-06-2019

Accepted on 19-07-2019

were males (mean age: 23.31 years). The mean age of the sample was 23.31 years. All transmigrated canines were unilateral and impacted. 12 canines showed type 1 pattern, while type 2 and type 3 transmigratory patterns were shown by 4 canines each (Table 2) (Figure 1-3). Intergroup comparison showed insignificant association with transmigration (Table 2).

Table 1: Mupparapu's classification of transmigrations

Type 1: Mesioangular location, crossing the midline
Type 2: Horizontal location at inferior border of lower jaw
Type 3: At mesial or distal to cotralateral side cuspid
Type 4: Horizontal location at inferior border of lower jaw at premolar/molar region
Type 5: Vertical location in midline

Table 2: Distribution of Various Developmental Dental Anomalies in the TG (n 20) and CG (n 100).

Dental Anomalies	TG	CG	P
Shape Anomalies	2 (10%)	5 (5%)	1.00
Structural Anomalies	0 (0%)	0 (0%)	1.00
Number Anomalies	1 (5%)	1 (1%)	1.00
Positional Anomalies	2 (10%)	2 (2%)	1.00

*P<0.05, significant.

Figure 1: Transmigrated canine

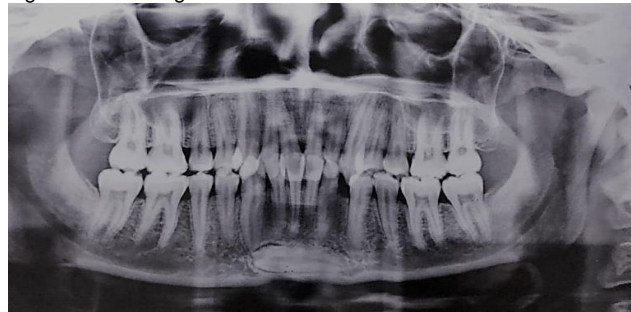

Figure 2: Transmigrated canine

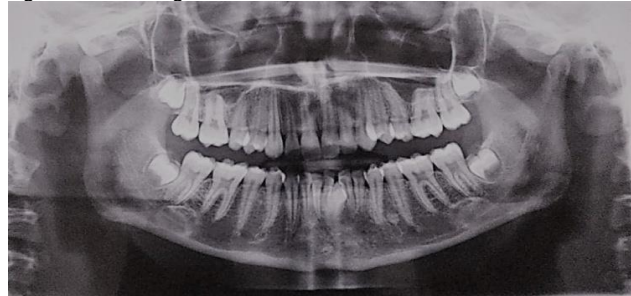
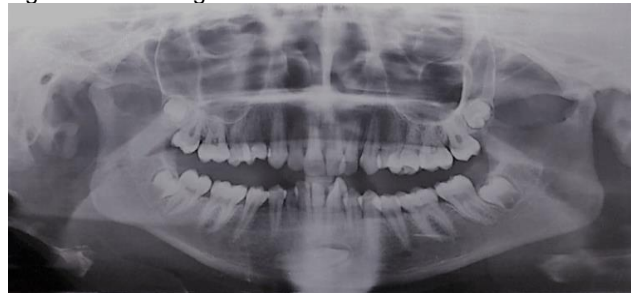

Figure 3: Transmigrated canine



DISCUSSION

To our knowledge, very few studies have been conducted on the association of dental anomalies in patients with transmigrated canines. The objective of this study was to assess occurrence of dental anomalies in both the groups. Results showed that all transmigrated canines were unilateral and impacted. Intergroup comparison showed insignificant differences. According to Holla et al. dental Class II malocclusion with increased overbite, deep plane of occlusion, excess of bolton ratios, and increase vertical growth indicated an excess apical space in the mandibular incisors resulting in a loss of canine guidance and eventually transmigrating canine¹⁰. Furthermore, retained deciduous teeth and supplemental tooth of the premolar series have been linked to transmigrated mandibular canines¹⁶. Shapira and Kuflinec analyzed 73 cases of transmigrated canines, out of which 9.5% cases were associated with hypodontia while 7% cases were associated with odontomes, and in 4% cases both anomalies were found to be associated with transmigrated canines¹⁷. Taguchi found that odontomes were a possible cause of ectopia¹⁸. Ectopic maxillary canines are also found to be associated with hypo- and hyperdontia¹⁹. Camilleri and Scerri reported case series of five transmigrated canines, and found that four put of five cases also showed ectopia of other teeth²⁰.

The limitations of present study are its observational nature and decreased sample size.

CONCLUSION

It was concluded that no significant association was found between various categories of dental anomalies with mandibular canine transmigration.

REFERENCES

1. Delli, K., Livas, C., Bornstein, M.M., 2013. Lateral incisor agenesis, canine impaction and characteristics of supernumerary teeth in a South European male population. *European J Dent.* 7(3), 278-283.
2. Plaza, S.P., 2016. Orthodontic traction of a transmigrated mandibular canine using mini-implant: a case report and review. *J orthod.* 1;43(4), 314-21.
3. Javid, B.R., 1985. Transmigration of impacted mandibular cuspids. *International J oral surg.* 1;14(6), 547-9.
4. Mupparapu, M., 2002. Patterns of intra-osseous transmigration and ectopic eruption of mandibular canines: review of literature and report of nine additional cases. *Dentomaxillofac Radio.* 31(6), 355-60.
5. Tarsitano, J.J., Wooten, J.W., Burditt, J.T., 1971. Transmigration of nonerupted mandibular canines: report of cases. *J American Dent Assoc.* 1;82(6), 1395-7.
6. Shapira, Y., Kuflinec, M.M., 2003. Intrabony migration of impacted teeth. *Angle orthod.* 73(6), 738-43.
7. Aydin, U., Yilmaz, H.H., Yildirim, D. 2014. Incidence of canine impaction and transmigration in a patient population. *Dentomaxillofac Radio.* 1, 28.
8. Aktan, A.M., Kara, S., Akgünlü, F., Malkoç, S., The incidence of canine transmigration and tooth impaction in a Turkish subpopulation. 2010. *Eur J Orthod.* 1, 151.
9. Dalessandri, D., Parrini, S., Rubiano, R., Gallone, D., Migliorati, M., 2017. Impacted and transmigrant mandibular canines incidence, aetiology, and treatment: a systematic review. *Eur J orthod.* 1;39(2),161-9.

10. Holla, A., Saify, M., Parashar, S., 2012. Transmigration of impacted mandibular canines and its association with malocclusion and morphology: an analysis of seven cases. *ORTHODONTICS: Art Practice Dentofac Enhancement*. 1;13(1).
11. Jain, S., Shetty, K.S., Jain, S., Jain, S., Prakash, A.T., Agrawal, M., 2014. Evaluation of dental age and associated developmental anomalies in subjects with impacted mandibular canines. *Angle Orthod.* 1;85(4), 638-44.
12. Joshi, M.R., 2001. Transmigrant mandibular canines: a record of 28 cases and a retrospective review of the literature. *Angle orthod.* 71(1), 12-22.
13. Gupta, S.K., Saxena, P., Jain, S., Jain, D., 2011. Prevalence and distribution of selected developmental dental anomalies in an Indian population. *J oral sci.* 53(2), 231-8.
14. Becker, A., Smith, P., Behar, R., 1981. The incidence of anomalous maxillary lateral incisors in relation to palatally-displaced cuspids. *Angle orthod.* 51(1), 24-9.
15. Shafers, W.G., Hine, M.K., Levy, B.M., Tomich, C.E., 2003. *Textbook of Oral Pathology*. 4th ed. Philadelphia.
16. Camilleri, S., 2007. Double transmigration and hyperdontia. *The Angle Orthod.* 77(4), 742-4.
17. Shapira, Y., M. M. Kufninec., 1995. Intraosseous transmigration of mandibular canines—review of the literature and treatment options. *Compend Contin Educ Dent.* 16, 1014–1024.
18. Taguchi, Y., Kuroi, J., Kobayashi, H., Noda, T., 2001. Eruption disturbances of mandibular permanent canines in Japanese children. *International J paed dent.* 1;11(2), 98-102.
19. Wang, X.P., Åberg, T., James, M.J., Levanon, D., Groner, Y., Thesleff, I., 2005. Runx2 (Cbfa1) inhibits Shh signaling in the lower but not upper molars of mouse embryos and prevents the budding of putative successional teeth. *J dent research.* 1;84(2), 138-43.
20. Camilleri, S., Scerri, E., 2003. Transmigration of mandibular canines—a review of the literature and a report of five cases. *Angle Orthod.* 73(6), 753-62.