

# A Study of Focal Lymphoid Aggregates and their Further Differentiation in Bone Marrow Biopsies: An Experience at Tertiary Care Hospital

SOBIA ASHRAF<sup>1</sup>, HAJRAH SYNDEED PAL<sup>2</sup>, AMBAREEN HAMID<sup>3</sup>, HUMERA RAFIQ<sup>4</sup>, RABIA RATHORE<sup>5</sup>, QURAT UL AIN<sup>6</sup>

## ABSTRACT

**Background:** Presence of lymphoid aggregates is a significant finding and have certain impacts while diagnosis and evaluations of bone marrow trephine biopsies. These aggregates are found in various malignant as well as benign disorders such as lymphomas, infections, autoimmune disorders etc. Differentiation between the type of these lymphoid follicles remains an important mainstay during diagnosis of various disorders.

**Aim:** To evaluate the frequency of benign disorders associated with reactive lymphoid aggregates since a large number of patients undergo these biopsies prior to formation of primary diagnosis.

**Methods:** This study was conducted in Department of Pathology, King Edward Medical University from May to June 2013. It was a cross sectional study and enrolled 152 patients. Patients with known cases of Lymphomas were excluded from the study.

**Results:** It was found that lymphoid aggregates were found in 11% of the patients with a M:F ratio of 1.6:1. Out of these, clonal lymphoid aggregates were found in 101 (66.4%) patients while the remaining 51 (33.6%) patients had reactive lymphoid nodules. Topographic distribution showed reactive aggregates were present in intertrabecular areas whereas clonal aggregates were largely found in combined paratrabecular and intertrabecular areas. The disorders associated with reactive aggregates included Myelodysplastic syndrome, aplastic anemia, viral infections, systemic autoimmune disorders and solid organ malignancies.

**Conclusion:** Finding a lymphoid aggregate in trephine biopsies requires rigorous assessment despite of topographic distribution. Immunohistochemistry plays an important role in establishing the clonality of aggregates specially in under-resourced countries.

**Keywords:** Focal lymphoid, bone marrow, nodules

## INTRODUCTION

Lymphoid aggregates, whether benign or malignant, are relatively uncommon in bone marrow (BM) biopsy specimens<sup>1</sup>. Differentiation between benign and malignant (i.e. lymphoma) aggregates can be difficult as well as challenging, especially when multiple aggregates are identified with no history of lymphoma. Moreover, considerable diagnostic difficulties arise when lymphoid cell involvement is strictly focal and composed of small to intermediate sized elements<sup>2</sup>. Differentiation between the natures of lymphoid follicle remains essential in each case for proper management of the patient.

A large number of malignant disorders are associated with lymphoid aggregates in bone marrow trephine. These include both Hodgkin lymphomas and Non-hodgkin lymphomas such as chronic lymphocytic leukemia, multiple myeloma, waldenstrom macroglobinemia and hairy cell leukemias to name a few<sup>3</sup>. Malignant features of lymphoid aggregates include predominance of B or T cells, infiltrative edges, paratrabecular location, inclusion of fat cells, location surrounding large sinuses, and large aggregates<sup>4</sup>. The non-neoplastic conditions associated with lymphoid aggregates are relatively more common. These include

aging, autoimmune diseases, inflammatory conditions, and infectious disorder<sup>5</sup>. Small nodules with distinct margins and no interstitial infiltrate as well as non-paratrabecular distribution are suggestive of benign origin.

Other diseases associated with lymphoid aggregates also include myeloproliferative neoplasms and myelodysplastic syndromes. Rare occurrences have been defined with tobacco and rituximab use<sup>6</sup>.

The diagnostic differentiation between the two types of aggregates is largely dependent upon immunohistochemical staining and flow cytometry. Due the limitations of flow cytometry for obtaining an adequate sample in cases of infiltrations into bone marrow or cellularity of the specimen<sup>7</sup>, morphological differentiation and immunohistochemistry still plays a contributory role.

In developing countries like ours, where tertiary cares have a huge burden of diagnostics is being referred, bone marrow biopsies are performed in a large number of cases where primary diagnosis is not being established<sup>8</sup>. Thus again it generally depends upon morphological characterization, expertise of the examiner and immunohistochemistry to identify malignant cases<sup>9</sup>. In order to make a correct diagnosis with minimal financial burden, it is thus important to identify the features of bone marrow involvement in benign conditions as well. The most common finding in such diseases is the presence of reactive lymphoid aggregates which may or may not be associated with other stromal changes.

The objective of the study was to determine frequency of reactive lymphoid aggregates in bone marrow biopsy

<sup>1</sup>Assistant Professor of Pathology, King Edward medical university.

<sup>2</sup>Demonstrator pathology, King Edward Medical university

<sup>3</sup>Associate professor, pathology, King Edward Medical university

<sup>4</sup>Associate professor of pathology, PGMI, Lahore.

<sup>5</sup>Associate Professor of Medicine, KiE Medical University Lahore.

<sup>6</sup>Demonstrator pathology, King Edward Medical University, Lahore

Correspondence to Dr. Ambareen Hamid, Email: dr\_ambareen@hotmail.com Cell: 0306-4466699

## MATERIALS AND METHODS

This study was conducted at Department of Hematology, King Edward Medical University and affiliated hospitals Lahore from May 2010 to June 2013. It was a Cross Sectional Study. Trephine biopsies of 1369 patients were reviewed and 152 patients having one or more lymphoid follicles were included. The patients with primary diagnosis of lymphoma with diffuse infiltration of bone marrow were excluded. Lymphoid follicles were analyzed on the basis of morphology and topographical distribution. Immunohistochemistry was performed for CD3, CD20 and CD45. For establishing clonality kappa and lambda restriction analysis was carried out in few cases.

## RESULTS

Evaluation of 1369 biopsies showed presence of lymphoid follicles in 152 (11%) patients. Out of these 57 were females and 95 were males. (M:F ratio 1.6:1)

On the basis of morphological and topographical distribution, 101 (66.4%) follicles were considered to be malignant while 51(33.6%) were benign. Confirmation was done by applying CD3, CD 20 and kappa lambda restriction. 11(7.2%) showed T cell origin by showing positivity for CD 3, 100(62%) showed B-cell origin by showing positivity for CD 20. 51(33.6%) showed positivity for both CD 3 and CD 20 and were consistent with benign origin. Monoclonality was determined in 2(3.9%) patients initially considered to be benign due to positivity with both CD3 and CD20. The associated disorders with benign lymphoid aggregates were found to be myelodysplastic syndrome, aplastic anemia, viral infections, solid organ malignancies and systemic autoimmune diseases. However, there were 10 patients (6.6%) who had reactive lymphoid follicles in bone trephines while they turned out to be suffering from lymphoid malignancies at later stage. Malignant lymphoid aggregates were primarily associated with non hodgkin lymphomas. Other major association was with hodgkin lymphomas.

Most of the benign aggregates were found in inter-trabecular area as opposed to the malignant nodules majority of which were found either para-trabecular alone or involving para-trabecular region as well. The topographic evaluation showed the following features:

Figure (n=152)

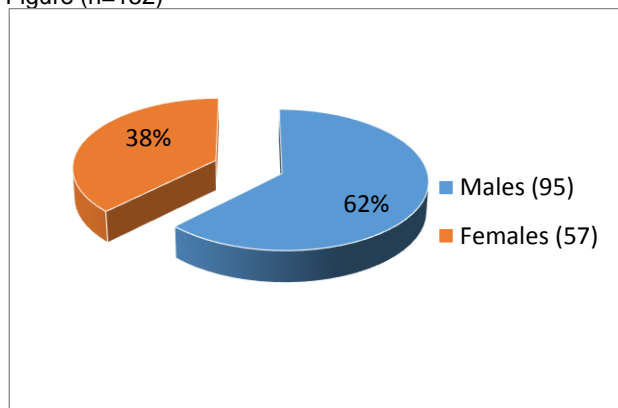


Table 1: Association of lymphoid aggregates with malignant/non-malignant disorders (n=152)

Benign Lymphoid Aggregates 51 (33.6%)	MDS n=26
	Aplastic Anemia n=07
	Viral Infections=02
	Systemic Autoimmune disorders n=02
	Solid organ malignancies n=04
Malignant Lymphoid Aggregates 101(66.4%)	Lymphoid Malignancies n=10
	Non Hodgkin Lymphomas n=78
	Hodgkin Lymphomas n=23

Table 2: Comparison between Morphological Involvement by Benign and Malignant Aggregates:

Morphological Pattern	Benign Aggregates (n=51)	Malignant Aggregates (n=101)
Para-trabecular	05 (9.8%)	31 (30.6%)
Inter-Trabecular	39 (76.4%)	05 (4.9%)
Combined Para-trabecular and Inter-trabecular	07 (13.7%)	65 (64.3%)

## DISCUSSION

In our study, it was shown that finding bone-marrow lymphoid aggregates during trephine evaluation is a significant finding (11%), though not very common. This is consistent with the previous reports where it is regarded not to be very common in other races as well<sup>1</sup>. Thus it can be concluded that the bone marrow involvement is irrespective of races and dependent on disease entity. The defect was found to be 4 and 5% respectively in older studies<sup>1,2</sup> as compared to current study. This clearly shows improvement in techniques used for histological detections of infiltrates over time.

The M:F ratio in this study was found to be 1.6:1. This is consistent with another study conducted by Ben Ezra et al<sup>10</sup> who found it to be 1.5:1. However, in another study by Theli J et al<sup>2</sup>, this ratio was 2.1:1. The probable difference between the two statistics represent more involvement in males as compared to females. Certain attributes found in males such as smoking and co-morbidities could be important in this regard. Current awareness regarding carcinogens and avoidance of them could be one possible reason for decreased ratio in men now.

The determination of clonality using kappa lambda restriction turned out to be important as it was shown in app 4 % of cases which were considered reactive initially due to presence of staining with both CD3 and CD 20. In a recent study by Gozila A et al, it is shown that genetic rearrangement is helpful in detection of clonality in 10-15 % of difficult cases<sup>11</sup>. Therefore in developing countries with budget constraints, the use of kappa lambda restriction is still justified and beneficial. The use of a limited panel antibodies for determination of clonality is useful as shown in a study by Garcia CF et al<sup>12</sup>.

Another aspect showed that reactive follicles were found in cases of malignant diseases (NHL) as well without the infiltration by the primary disease. This cannot be ignored nor can be taken as involvement of bone marrow by the disease. This finding creates a dilemma and it should be always differentiated for deciding treatment of the patient. This entity has been described in a multicentric study by Oschelis I et al<sup>13</sup>.

## CONCLUSION

The presence of lymphoid aggregate in bone marrow trephine definitely requires further investigation especially in cases where primary diagnosis has not been established. Morphological evaluation and immunohistochemistry plays an important role still in this era of molecular diagnosis. Every aggregate should be evaluated for the presence of clonal cells even if they appear to be reactive. Similarly, this helps to determine presence of reactive nodules in known cases of lymphomas.

Development of more refine techniques and their widespread availability for better diagnostic and management purposes should be emphasized upon and worked with enthusiasm to improve medical care and outcomes.

## REFERENCES

1. Foucar K, Viswanatha DS, Wilson CS. Non-neoplastic lymphoid and plasma cell disorders. In: King DW, ed. *Non-Neoplastic Disorders of Bone Marrow*. Washington, DC: American Registry of Pathology; 2008:249–282. AFIP Atlas of Nontumor Pathology; 1st series.
2. Thiele J, Zirbes TK, Kvasnicka HM, Fischer R. Focal lymphoid aggregates (nodules) in bone marrow biopsies: differentiation between benign hyperplasia and malignant lymphoma—a practical guideline. *J Clin Pathol*. 1999;52(4):294–300.
3. Thomas JS. The diagnosis of lymphoid infiltrates in the bone marrow trephine. *Current Diagnostic Pathology*. 2004 Jun 1;10(3):236–45.
4. Nelson B. Bone marrow evaluation for lymphoma. In: Jaffe ES, Vardiman J, Campo E, Arber D, eds. *Hematopathology*. Philadelphia, PA: Elsevier Press; 2010: 887–917.
5. Engels K, Oeschger S, Hansmann ML, Hillebrand M, Kriener S. Bone marrow trephines containing lymphoid aggregates from patients with rheumatoid and other autoimmune disorders frequently show clonal B-cell infiltrates. *Hum Pathol*. 2007;38(9):1402–1411.
6. Johnston A, Brynes RK, Naemi K, Reisian N, Bhansali D, Zhao X, Rezk SA. Differentiating benign from malignant bone marrow B-cell lymphoid aggregates: a statistical analysis of distinguishing features. *Archives of Pathology and Laboratory Medicine*. 2015 Feb;139(2):233–40.
7. Fend F, Kremer M. Diagnosis and classification of malignant lymphoma and related entities in the bone marrow trephine biopsy. *Pathobiology*. 2007;74(2):133–43.
8. Tyagi R, Singh A, Garg B, Sood N. Beware of Bone Marrow: Incidental Detection and Primary Diagnosis of Solid Tumours in Bone Marrow Aspiration and Biopsies; A Study of 22 Cases. *Iranian journal of pathology*. 2018;13(1):78.
9. Chauhan S, Pradhan S, Mohanty R, Saini A, Devi K, Sahu MC. Evaluation of sensitivity and specificity of bone marrow trephine biopsy tests in an Indian teaching hospital. *Alexandria journal of medicine*. 2018;54(2):161–6.
10. Ben-Ezra JM, King BE, Harris AC, et al. Staining for bcl-2 protein helps to distinguish benign from malignant lymphoid aggregates in bone marrow biopsies. *Mod Pathol* 2000;7:560–64
11. Gazzola A, Mannu C, Rossi M, Laginestra MA, Sapienza MR, Fuligni F, Etebari M, Melle F, Sabatini E, Agostinelli C, Bacci F. The evolution of clonality testing in the diagnosis and monitoring of hematological malignancies. *Therapeutic advances in hematology*. 2014 Apr;5(2):35–47.
12. Garcia CF, Swerdlow SH. Best practices in contemporary diagnostic immunohistochemistry: panel approach to hemato-lymphoid proliferations. *Archives of pathology & laboratory medicine*. 2009 May;133(5):756–65.
13. Oschlies I, Salaverria I, Mahn F, Meinhardt A, Zimmermann M, Woessmann W, Burkhardt B, Gesk S, Krams M, Reiter A, Siebert R. Pediatric follicular lymphoma—a clinico-pathological study of a population-based series of patients treated within the Non-Hodgkin's Lymphoma-Berlin-Frankfurt-Münster (NHL-BFM) multicenter trials. *haematologica*. 2010 Feb 1;95(2):253–9.