

Is Ascaris Induced Pancreatitis being Under-diagnosed?- a case report

BALAKH SHER ZAMAN¹, MUNEEBA NASIR², AHMAD KALEEM³

SUMMARY

The extraintestinal manifestations of ascaris infestation, particularly acute pancreatitis with or without cholangitis are rare to present. This case report highlights this underdiagnosed etiology of acute pancreatitis, making it first such documented report in Pakistan ever. A 13 years old presented with pain epigastrium and nausea for one day .A diagnosis of acute pancreatitis of unknown etiology was made on clinical grounds and results of preliminary laboratory investigations. It was only after vomiting of worms by the patient that a suspicion of biliary ascariasis was raised. An undoubted diagnosis of ascaris induced pancreatitis was made based on vomitus containing worms and absence of all other known etiologies of acute pancreatitis. Patient was managed conservatively. The best tool to avoid missing diagnosis of ascaris induced pancreatitis is to keep high level of suspicion in patients living in unhygienic habitats.

Keywords: Ascaris lumbricoides, acute pancreatitis, diagnosis

INTRODUCTION

Ascaris Lumbricoides infestation inflicts about 1.4 billion of the world's population making it the second most common intestinal helminth, resulting in around 20,000 deaths per annum and is highly prevalent in age groups - 4 to 14 years¹. Hepatobiliary and pancreatic ascariasis is one of the established but underdiagnosed manifestation of this helminthic infestation, however acute pancreatitis and ascending cholangitis are rare presentations². In Pakistan, gallstones are known to be the most common etiology of acute pancreatitis³ and if not timely diagnosed, significant morbidity and mortality can result from severe acute pancreatitis⁴. Here, we present an unexpected case of ascaris induced pancreatitis in a 13 years old girl, in whom the diagnosis was mainly incidental.

CASE REPORT

A 13 years old girl presented to ER Mayo Hospital, Lahore with one day history of sudden, severe epigastric pain radiating to the back and was associated with three episodes of non projectile, nonbilious vomiting with no history of hematemesis. Patient denied any previous history of pain right hypochondrium, fever, regular medication, smoking or alcohol abuse, recent surgical or any invasive procedure, sore throat, persistent diarrhea, family history of hypertriglyceridemia and had no recent

travel history. As per her mother, patient had a history of pica as she used to eat soil (geophagia) since childhood. General physical examination revealed tachycardia, marked pallor, patient was febrile (37.9F) whilst abdominal exam was significant for guarding and rebound tenderness in epigastrium with sluggish bowel sounds on auscultation. Patient was put on strict NPO regimen and fluid resuscitation was instituted.

Hematology report showed: Hb=(5.6), mild leukocytosis=(9.45[10⁹]), Serum amylase=(1033) (Normal: upto 95), Serum Lipase=(2990) (Normal:upto160), Serum LDH=424 (Normal:248), Serum Creatinine=0.4 (Normal:0.6), Serum Bilirubin=1 (Normal:1.2),Serum AST=66 (Normal: up to 32), Serum ALT=38 (Normal:upto 40), Serum alkaline phosphatase: 276 (Normal:40 to 130) Random blood sugar=125mg/dl.

An ultrasound scan of abdomen showed partially visualized, hypoechoic body of pancreas with enlarged pancreatic tail. and no calculi or sludge were appreciated in the gallbladder or in extrahepatic biliary tree. The common bile duct measured 6mm. An enhanced CT abdomen and pelvis revealed swollen pancreas with peripancreatic fat stranding with no peripancreatic collection. Main pancreatic duct measured 4mm. Both kidneys, liver, gallbladder and pelvic organs were normal (Fig. 1).

The diagnosis of acute pancreatitis (ATLANTA classification) without any hepatobiliary pathology was made. Patient was shifted to high dependency unit and was managed conservatively. While being investigated for various causes of pancreatitis, patient vomited two round worms on 3rd post admission day (Fig. 2). This raised suspicion that

¹Assistant Professor Surgery, KEMU/Mayo Hospital, Lahore

²HO, Mayo Hospital, Lahore

³MO/Registrar Surgery, Mayo Hospital, Lahore

Correspondence to Dr. Muneeba Nasir, Email:

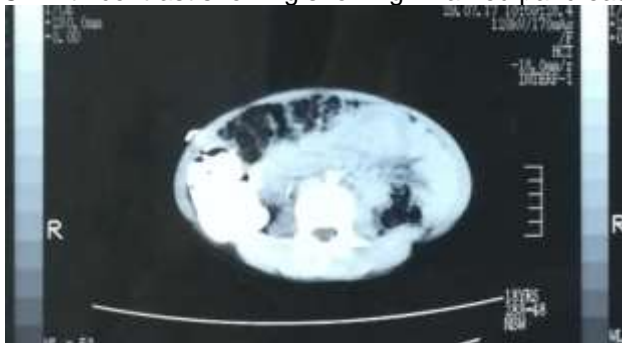
muneeba.nasir112@gmail.com Cell: 0331-7582937

ascaris infestation has led to acute pancreatitis as all other causes of acute pancreatitis were significantly ruled out. Keeping in view the hierarchy of disease events in this patient, it was strongly hypothesized that a migrating worm was the cause of her acute pancreatitis. An ERCP was not planned considering hazards of this invasive procedure in a stable patient and lack of evidence of any obstructive etiology (absence of cholangitis: fever, jaundice, pain in right hypochondrium). On 6th post admission day, her serum lipase (38), serum amylase(145.8),WBC(5.4×10^9) were back to normal. Patient showed significant recovery after vomiting worms and taking mebendazole 100 mg orally twice daily for 3 days. Subsequently, patient was fully recovered and discharged on 7th post admission day. She remained healthy on follow ups at 1 and 4 weeks.

Worm vomited by patients



CT with contrast showing showing inflamed pancreas



DISCUSSION

Ascariasis infestation globally affects around 25% of the world's population with poor sanitation as the most significant risk factor[5]. A study conducted in 2015 in a tertiary care hospital in Pakistan, showed that in 85% of the cases, cholelithiasis is the etiology of acute pancreatitis³. This is the first documented

case report of ascaris induced pancreatitis in our region.

Hepato biliary ascariasis (HPA) manifests itself as five major spectra: (1) Acalculous cholecystitis (2) Acute pancreatitis (3) Acute cholangitis (4) Biliary colic (5) Hepatic abscess¹. (6) Bile peritonitis[6] and is attributed to free motility of helminths through ampulla of Vater into and out of the biliary tree. Adults (mean age - 35 to 42 years) are predominantly affected with a female to male ratio of 3:1¹. One study concluded that around 80% of the patients with HPA had previously undergone sphincterotomy or any other surgery involving biliary tree⁷. However, both of these predisposing factors were not found in this case.

Studies revealed that the diagnosis of Ascaris pancreatitis is mostly incidental⁵ which is attributable to low specificity of imaging modalities owing to nature of worm body[8]. Among radiological studies, abdominal ultrasound is considered first line and diagnosing ascaris infestation with hepatobiliary involvement is elaborated as point of care emergency department ultrasonography (POCUS)[[9]. A motile hyperechoic longitudinal structure with hypoechogenic line and/or dilation of bile duct, pancreatic edema on ultrasound are usually indicative of biliary ascariasis⁶. Its sensitivity may be enhanced by giving fluids P/O, exerting mild pressure with transducer and by positioning the patient in left lateral decubitus - as all these maneuvers trigger worm to move¹⁰. A contrast enhanced computed tomography (CT) scanning may reveal filling defects in biliary tree or whirled groups of worms¹¹. An Endoscopic retrograde cholangiopancreatography is a gold standard therapeutic and diagnostic imaging modality when there is suspicion of pancreatico-biliary involvement¹². In this case, an ERCP was not performed owing to absence of any plethora of obstructive symptoms and signs and above all, significant improvement in patient following emesis of helminths did not favour performing this invasive procedure, which itself predisposes to acute pancreatitis¹³. Capsule endoscopy also has a role in diagnosing ascaris induced pancreatitis¹⁴. Stool testing for ova and parasites and mild eosinophilia are also indicative of parasitic infection. A conservative plan of management is mostly preferred by clinicians, that includes administration of intravenous antibiotics (if there is clinical suspicion of cholangitis), intravenous fluids, appropriate analgesics, keeping the patient nothing per oral followed by regimen of anti helminthic drugs, once acute state is resolved. As per one school of thought, a therapeutic ERCP is indicated only if patients fall in these two categories: (1) failure of conservative management (2) persistence of worms in biliary tree

after 3 weeks of conservative management¹. While mostly authors are in favor of emergent ERCP to prevent serious complications¹².

The diagnosis in this case was made beyond doubt based on history of pica, clinical presentation, hematological picture, vomitus containing worm, lack of evidence of any other pathology and significant response of patient to anti helminthic treatment. The symptoms of patient remarkably subsided following vomiting of worms.

CONCLUSION

Ascaris induced pancreatitis is underdiagnosed and frequently missed presentation in patients presenting to tertiary health setups in Pakistan. Keeping a high level of suspicion is the surgeon's best tool. A low threshold for suspecting helminthic infestation should be kept while establishing the cause of acute pancreatitis in patients with history of pica and those belonging to far flung rural areas and slums in urban areas.

REFERENCES

- 1- Khuroo MS. Ascariasis. *Gastroenterology clinics of North America* 1996; 25: 553-77.
- 2- Al-Qurashi A, Maklad KM, Al Abdulwahed O. Pancreatitis due to ascaris lumbricoides, a case report. *J Egypt Soc Parasitol* 2003; 33:657-62.
- 3- Mazhar I, Mariam M, Sughran P. Mortality and Morbidity in Acute Pancreatitis. *Journal of Surgery Pakistan*. 2015;20(4):128-132
- 4- K. M. Pal, Pashtoon Murtaza Kasi, Mohammad Tayyeb, S. M. Faisal Mosharraf, and Zafar Fatmi. Correlates of Morbidity and Mortality in Severe Necrotizing Pancreatitis. *ISRN Surgery*. 2012;20:1-5
- 5- Misra SP, Dwivedi M. Clinical features and management of biliary ascariasis in a non-endemic area. *Postgraduate medical journal* 2000;76: 29-32.
- 6- Ferreyra NP, Cerri GG. Ascariasis of the alimentary tract, liver, pancreas and biliary system: its diagnosis by ultrasonography. *Hepatogastroenterology* 1998;45:932-937.
- 7- Sandouk F, Haffar S, Zada MM, Graham DY, Anand BS. Pancreatic-biliary ascariasis: experience of 300 cases. *Am J Gastroenterol* 1997; 92: 2264-7.
- 8- Amina B, Hiten RH, Rehab Al S. Helminthic Induced Pancreatitis: Are we underdiagnosing?. *Grand Rounds Journal* 2012;12:49-55
- 9- Kessler DO, Gurwitz A, Tsung JW. Point-of-care sonographic detection of intestinal ascaris lumbricoides in the pediatric emergency department. *Pediatr Emerg Care*. 2010 Aug. 26(8):586-7.
- 10- Ramareddy RS, Alladi A, Sidapa OS, Deepti V, Akhtar T, Mamata B. Surgical complications of Ascaris lumbricoides in children. *J Indian Assoc Pediatr Surg*. 2012 Jul. 17 (3):116-9.
- 11- Pratt LT, Blachar A. Computed tomography diagnosis of intestinal ascariasis: incidental finding in a trauma patient. *Isr Med Assoc J*. 2007 Sep. 9 (9):688-9.
- 12- Sanai FM, Al-Karawi MA. Biliary ascariasis: report of a complicated case and literature review. *Saudi J Gastroenterol*. 2007 Jan-Mar. 13(1):25-32.
- 13- Martin L, Freeman MD, James A. Risk factors for post ERCP pancreatitis: a prospective multicentre study. 2001, 54(4):425-434
- 14- Wickramasinghe DP, Samarasekera DN. Intestinal helminths detected in capsule endoscopy. *Dig Endosc*. 2012 Sep. 24 (5):388.