

Acrylic Partial Denture Versus Chromium Cobalt Denture: a Study, Gauging the Patient Satisfaction for What is Best and Most Suitable in a Defined Local Population

M. RAFI ULLAH AWAN¹, HIRA ASGHAR², ASAD ULLAH³, HAIDER JAVED⁴

ABSTRACT

Aim: To assess patient satisfaction in Kennedy's class I classification in mandibular molars either by using acrylic partial denture or chromium cobalt cast partial denture.

Methods: This study was conducted at Akhtar Saeed Dental Hospital, Bahria Town, Lahore from 1st July 2016 to 31st December 2017. A total number of 32 patients were selected randomly that needed the removable partial dentures according to their own consent. These patients were categorized into two groups with 16 patients in each group. Group 1 was having patients wearing the acrylic partial dentures having Kennedy's class I classification of missing teeth in mandible. The second group had cast partial denture with same conditions. Level of satisfaction was scored by the five division grades.

Results: The p value corresponding to F-statistic of one way ANOVA is lower than 0.05 revealing that two groups are significantly different.

Conclusion: Acrylic removable partial denture remained more satisfactory to the patients as compared to cast partial denture. This significant difference resulting from patient satisfaction was in terms of esthetics, ease of repair or relining of the appliance and the economically cost effectiveness.

Keywords: Acrylic partial denture, Chromium cobalt alloy, Lingual bar, Periodontium, Mucosa,

INTRODUCTION

Patient satisfaction is one of the most important indicators in health care, measuring the health care provided. It has a positive impact on patient as well as doctor. It encircles all the facilities provided to the patient including the hospitalization, type of treatment and the quality. It is a measure that reflects how a patient is satisfied and happy from the treatment provided by the curator. There might be situations when the patient is not satisfied with the treatment given but improves health by the ailments provided and vice versa. Still this patient satisfaction is an important indicator for the health care quality provided. Many studies have been done on this satisfaction of the patient and treatment but fail to result in a proper relationship between them.¹ Sometimes the patients are more satisfied by the attractive healthcare rather than the effective healthcare².

Despite so many unnecessary factors present in between, this patient satisfaction is considered as a good and reliable source in the provision of health

care facilities and improving the quality of treatment. In dentistry sometimes, achieving this patient satisfaction becomes a challenge to the clinician after the patient having awareness about the positive outcomes of a specific treatment in terms of functionality and esthetics. Decayed and missing teeth are common like other oral diseases and anomalies that are present in the community. The missing teeth are usually replaced by the removable or the fixed prosthesis. The removable prosthesis includes the acrylic partial dentures and the cast partial dentures. These are hygienic and easy to remove and clean. The acrylic dentures are supported by the mucosa and the adjacent teeth. Their design depends upon the teeth present in the oral cavity and requirements of the patients. These removable dentures can be equally used successfully in both jaws. These dentures are useful in the mastication and bear good esthetics. They are capable to meet the esthetic demands of the patients. In the early era, the dentures were made of human extracted teeth joined together by the metallic bars³.

In the earlier 16th century, wooden dentures were used in Japan⁴. Stability and retention are the main requirements that a patient often demands in addition to the esthetics. Moreover, the repair of the denture should be possible without any difficulty. The acrylic denture can be relined and repaired easily. While in case of cast partial denture, any breakage can be handled by the soldering the metallic plate

¹Assistant Professor of Prosthodontics, Akhtar Saeed Medical & Dental College Bahria Town Lahore,

²Assistant Professor of Science of Dental Materials, Faryal Dental College Sheikhupura,

³House Officer, Lahore Medical & Dental College Lahore,

⁴Senior Demonstrator, Department of Community Dentistry, Faryal Dental College Sheikhupura

Correspondence to Dr. Asad Ullah Email: asad3215600@gmail.com Cell: 0322-5600327

and lost acrylic teeth can be fabricated. This article primarily makes a focus on the patient satisfaction achieved by the acrylic partial dentures and cast partial dentures made in chromium cobalt alloy. Thus, it provides an exciting opportunity to advance our knowledge comparing the both. The removable partial denture is a good option for the patients who cannot afford the fixed prosthesis. This is simply because they are cheap, easy to fabricate and can be made without any invasive procedure⁵.

PATIENTS AND METHODS

This eighteen months study was conducted at Akhtar Saeed Dental Hospital, Bahria Town, Lahore from 1st July 2016 to 31st December 2017. The study offers some essential insights into removable prosthesis. The patients selected had missing teeth with Kennedy’s class I classification having the bilateral free end partially edentulous in the mandible i.e., missing molars on both sides. A total number of 32 patients were selected randomly that needed the removable partial dentures according to their own consent. . All the patients had ages between 45-60 years of age. Twenty two patients were male while ten were females. The acrylic partial dentures and the chromium cobalt cast partial dentures were prepared and were used for more than 18 months. All the missing mandibular molars were fabricated in both type of appliances. The patients were categorized into two groups with 16 patients in each group. Group 1 was having patients wearing the acrylic partial dentures with Kennedy’s class I classification of missing teeth. The second group had cast partial denture with same scenario. All the patients had good oral hygiene and no other missing teeth in the oral cavity. The remaining teeth in the oral cavity were in good form and no malocclusion or over eruption of teeth in the opposing arch was there. There was enough space in the arch for the missing teeth to be accommodated in the appliances. The patients did not have any systemic disease. All patients were informed all about the cleansing of the removable appliances and to maintain the oral hygiene at the time of appliance insertion. The patients were fully motivated to give a full time use to the appliance. At the time of final follow up, all the appliances were in good and acceptable condition. There was no damage or malformation in any of the selected case. The apparent condition of the appliance was exhibiting its thorough use by the patient according to the instructions provided. Contact information was already taken and all patients were requested for three follow ups at six months interval. Moreover, the patients were also informed to contact the clinician in case of any

breaking or damage to the appliance. For the sake of convenience, to get the outcome of the satisfaction level, the grades were made understand to the patients in their own language in a simple way. Our aim was to provide conceptual theoretical framework based on the said criteria. Informants response about satisfaction was recorded according to following scoring. Patient graded satisfaction are (1) *unsatisfactory*, (2) *fair*, (3) *good*, (4) *very good* and (5) *excellent*.

RESULTS

The p value corresponding to F-statistic of one way ANOVA is lower than 0.05 suggesting that two groups are significantly different (Table 1). The result is significant at p< 0.05. What is striking about the figures in the graph is slightly raised mean for the acrylic partial denture (Fig. 1).

Fig. 1: Raised mean of acrylic partial denture

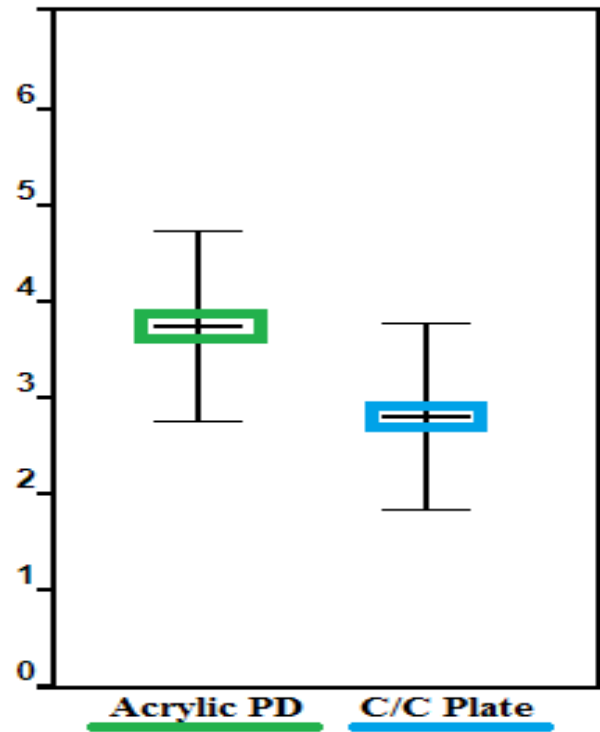


Table 1: Comparison of both groups

Treatments	Acrylic PD (A)	Chromium Cobalt RPD (B)	Grand Total
Observations N	16	16	32
Sum $\sum xi$	60.0000	45.0000	105.0000
Mean \bar{x}	3.7500	2.8125	3.2812
sum of squares $\sum xi^2$	240.0000	141.0000	381.0000
sample variance s^2	1.0000	0.9625	1.1764
sample std. dev. S	1.0000	0.9811	1.0846
std. dev. of mean $SE\bar{x}$	0.2500	0.2453	0.1917

Analysis of Variance (ANOVA)

Groups	Sum of squares	Degrees of freedom	Mean square
Treatment	7.0312	1	7.0312
Error	29.4375	30	0.9812
Total	36.4688	31	

Treatment pair	Tukey HSD Q statistic	Tukey HSD p Value	Tukey HSD interference
A vs B	3.7857	0.0119318	p<0.05

Further analysis exhibit the following results:

$Q_{critical}$ at α 0.05, $k=2$, $v=30$ =2.8882

$Q_{critical} < Q_{error}$ for the observed pair.

DISCUSSION

Acrylic dentures are made of acrylic teeth and the supporting acrylic plate. These are most widely used prosthesis in dentistry. They are easy to manipulate and cost effective. Moreover, these acrylic dentures are more biocompatible and esthetically acceptable. They use support from the existing teeth as well as from the adjoined mucosa and the bony tissues. In addition stainless steel wire clasps are also used which act as firm gripping of the denture plates and support the retention. The ease of repair is the positive point making it popular one. Although there are certain demerits associated with these prosthesis like compromised stability, difficulty in periodic removal, more size and liable to fracture yet they are being used extensively giving an equal satisfaction to the patients. They are also used as temporary substitute of the missing teeth. Once the patient gets used of its wearing and removal, it can be well tolerated and acceptable by the patients. The other type of removal prosthesis is the chrome cobalt plate dentures. Like the acrylic dentures they are also supported by the adjacent mucosa and the remaining teeth through their base plate and certain retainers. They are hygienic, comfortable to wear, having good fitting, strong enough and having goods masticatory efficiency. But in the same way they are expensive and sometimes beyond the affording capacity of the patient. Their fabrication require special skilled techniques and need special impression protocols. In contrast to the acrylic dentures, they are less bulky due to thin metal plates and stronger enough. The removable appliances have the advantage that they can be removed by the patient himself in order to make it clean or while sleeping. The fixed prosthesis is only removed by the clinician. The clasp of the removable partial denture has also an effect of the environment i.e., dry or wet on the retention of appliance. Mourshed et al⁷ have concluded this through their investigation⁶. Recently a new concept of the single metal restoration has been emerged. According to this view the use of single metal is

beneficial as the combination of different metals can cause corrosion, so this possibility can be eliminated. For this purpose pure titanium should be used.

The chewing efficiency is improved and marked in the short end dental arch with the removable partial denture⁸ Compound aker clasp is more beneficial than the circular or other types of clasps in Kennedy class I removable partial denture. It has the potential to reduce the abutment alveolar bone resorption⁹ The lack of teeth not only compromise the chewing efficacy but also the esthetics. There are a lot of changes that take place when the teeth are missing. One of them is the inclination of the teeth. This inclination if severe may result in difficulty in the fabrication of the prosthesis. This change in the position of teeth can cause the changes in the position of maxilla with respect to the mandible.¹⁰ The acrylic has a porous nature. It has the tendency to absorb the water and thus can swell. This property of the material can lead to the aggregation of the microorganisms^{11,12}.

A good oral hygiene is mandatory for the healthy periodontium as well as the remaining dentition. Caries being the most common cause of the tooth damage. This is enhanced by the poor oral hygiene. Therefore the removal of the plaque and the maintenance of oral hygiene is very necessary especially in patients wearing the removable partial dentures. The removable partial denture frame may act as reservoir for certain pathogens. This needs a periodic visit to the clinician.¹³ As far as the satisfaction of the patient is concerned, it is the main key factor in the oral health related quality of life. It gives a strong clue about the oral health related quality of life for the denture wearers¹⁴.

There must be good oral hygiene in order to make the removable prosthesis successful. In addition good abutment teeth and sound bony support also play an important role in the longevity of the prosthesis and the health of periodontium. The cast prosthesis has a reasonable flexibility so that it can be retentive in the undercut areas. Moreover it is light and less bulky as compared to thick acrylic plates. It is esthetically compromised material especially in the anterior teeth. In the bilateral free end saddle, a lingual bar is present. It is basically a major connector that unites the two contra lateral sides of the denture. It covers the cingula of the anterior teeth and designed to the contour of the gingiva. This plate is thin and flexible. The interproximal areas are blocked by the metal and the rest part of the metallic plate is not above the middle third of the cingula. The lower border of the bar is semi circular rounded. This type of restoration not only replaces the missing posterior teeth but also supports the anterior teeth. Removable partial

denture has always been a difficult task that clinician often face during clinical practice. The mind of the patient is usually directed towards the fixed prosthesis due to periodic removal and wearing of the denture and decreased esthetics. A clinical survey was done in which different chromium cobalt dentures were examined. The main focus of the survey was to assess the oral hygiene and the health of the gingiva. It was observed that there was high prevalence of the plaque, gingivitis and the gingival recession along the clasps of the prosthesis. Thus it strongly recommended that there must be high degree of oral hygiene maintenance for the denture users¹⁵. The bars and clasps of the cast partial dentures might impinge the soft tissue.¹⁶ Taken together, these results show that there are possibilities of minor soft tissue injuries. Cast partial dentures are difficult to repair and are heavy. It is more technique sensitive as compared to acrylic partial denture. Removable partial dentures have the ability to crush the food into smaller sized particles but they can never achieve the full masticatory function¹⁷. As argued by Ogunrinde¹⁸ the design of the lingual bar, which acts as a major connector, also plays a vital role in the gingival health. The quality of life pertaining to the oral health is related not only to the dental factors but also to the socioeconomic and psychological factors¹⁹.

CONCLUSION

Establishing the result of the research, low cost and ease of the repair make removable acrylic partial denture top notch and more convenient to the majority of patients. For my money, speech, retention and esthetics are the main concerns of the patients. When all these parameters are achieved, they give patients ease and satisfaction. Although the metallic chrome cobalt removable partial denture is also acknowledged by most of the patients, yet conventional acrylic removable partial denture remains popular among the patients and plain sailing for the clinician.

REFERENCES

1. Farley H, Enguidanos ER, Coletti CM, Honigman L, Mazzeo A, Pinson TB, et al. Patient satisfaction surveys and quality of care: an information paper. *Ann Emerg Med* 2014;64(5): 351–7.
2. Falkenberg K. Why rating your doctor is bad for your health [2013]. cited at: www.forbes.com
3. Donaldson JA. The use of gold in dentistry. *Gold Bul* 1980;13(3): 117–24.
4. Moriyama N, Hasegawa M. The history of the characteristic Japanese wooden denture. *Bull Hist Dent* 1987;35(1):9-16.
5. Nassani MZ, Tarakji B, Baroudi K, Sakka S. Reappraisal of the removable partial denture as a treatment option for the shortened dental arch. *Eur J Dent* 2013;7:251-6.
6. Mourshed B, Qaed NM, The effect of environment (dry and natural saliva) on clasp retention: in vitro study - Part I. *Eur J Dent* 2017;11(3):352-6.
7. Ohkubo C, Sato Y. Titanium removable denture based on a one-metal rehabilitation concept. *Dent Mater J* 2017;36(5):517-23.
8. Omo JO, Sede MA. Masticatory efficiency of shortened dental arch subjects with removable partial denture: a comparative study. *Niger J Clin Pract* 2017;20(4):459-63.
9. Abd El-Khalik MM, El Mekawy NH. Mandibular Kennedy Class I partial denture management by broad stress distribution philosophy (radiographic assessment). *J Indian Prosthodont Soc* 2016;16(3):282-7.
10. Kelly JT Jr. A multidisciplinary approach to restoring posterior bite collapse. *Compendium of Continuing Edu Dent* 1007; 18(5): 483–9.
11. Kurnatowska A, Bieniek J, “The level of cariogenic bacteria in wearers of partial dentures. *Protetyka Stomatologiczna* 2006; 56(2): 130–5.
12. Kanli A, Demirel F, Sezgin Y. Oral candidosis, denture cleanliness and hygiene habits in an elderly population. *Aging Clin Exp Res* 2005;17(6):502-7.
13. Mengatto CM, Marchini L. Partial denture metal framework may harbor potentially pathogenic bacteria. *J Adv Prosthodont* 2015;7(6):468-74.
14. Yen YY, Lee HE, Wu YM, Lan SJ. Impact of removable dentures on oral health-related quality of life among elderly adults in Taiwan. *BMC Oral Health* 2015;15:1-7.
15. Yeung AL, Lo EC, Chow TW. Oral health status of patients 5-6 years after placement of cobalt chromium removable partial denture. *J Oral Rehabil* 2000;27:183-89.
16. Waerhog J. periodontology and partial prosthesis. *Int Dent J* 1968;18:101106
17. Bessadet M, Nicolas E. Impact of removable partial denture prosthesis on chewing efficiency. *J Appl Oral Sci* 2013;21(5):392-6.
18. Ogunrinde TJ, Dosumu OO. The influence of the design of mandibular major connectors on gingival health. *Afr J Med Med Sci* 2014;43(1):29-33.
19. Pistorius J, Horn JG. Oral health-related quality of life in patients with removable dentures. *Schweiz Monatsschr Zahnmed* 2013;123(11):964-71.