

# Incidence of Post-Operative Complications of Inguinal Hernia and Hydrocele Open Surgery in Children

SAQIB JAVAID, NAIMA RASOOL, MUSTAFA LATIF CHOUDHRY

## ABSTRACT

**Background:** Recent advances in inguinal hernia surgery have shifted the paradigms towards laproscopic surgery. We, in Pakistan, are mainly relying on open surgery due to various constraints yet yielding appreciable results with minimal complications. This study was conducted to document the postoperative complications of elective inguinal hernia and hydrocele open surgery in children in our setup.

**Methods:** This descriptive study was conducted at Pediatric Surgery Department, Combined Military Hospital (CMH) Lahore, Pakistan, from September 2015 to June 2017. Patients from 10 days to 12 years of age diagnosed clinically as inguinal hernia and hydrocele were selected for the study by consecutive random sampling. Patients with incarcerated, strangulated or obstructed hernia who underwent emergency herniotomy or had other concomitant diseases were excluded. Hernia and hydrocele were operated electively through open surgery with minimal dissection. Follow up was done at 1 week, 4 weeks, 12 weeks and 24 weeks to note the postoperative complications of the surgery. Data was analyzed using SPSS 20.

**Results;** A total of 241 elective PPV ligations and herniotomies were performed at CMH Lahore in the duration of study. Out of these, 195 (80.91%) were male patients while 46 (19.08%) were female. Post-operative complications were noted in 41 (17.01%). Commonest being scrotal edema in 34 (14.10%), stitch granuloma in 5 (02.07%) and hematoma in 02 (0.83%) patients. No injury to vessels or vas deferens, surgical site infection, recurrence of hernia or testicular atrophy was noted.

**Conclusion:** Open surgery for inguinal hernia and hydrocele is still a safe surgery provided vigilant approach is undertaken with minimal tissue handling, yields appreciable results with minimal postoperative complications.

**Level of Evidence:** Level IV

**Keywords:** Children, Inguinal hernia, Hydrocele, Patent processus vaginalis, Open herniotomy, Postoperative complications

---

## INTRODUCTION

Inguinal hernia's descriptions date back to 1550 BC. The frequency of inguinal hernia is 1 to 2% in new born and increases up to 30% in premature babies. Right sided hernias are twice as common as those on the left.[1]In children inguinal hernia and hydrocele share the same etiology that is, Patent processus vaginalis accounts as a leading cause of nearly all inguino-scrotal hernia and hydrocele occurring in infancy and childhood<sup>2</sup>.

Management by PPV ligation and herniotomy is also considered to be the most commonly employed elective surgical procedure in pediatric age group. Surgery is usually performed as an outpatient procedure on early elective list once the diagnosis of hernia is made to prevent the strangulation of hernia, however non communicating hydrocele can be observed safely up to 12-24 months of age for possible spontaneous resolution<sup>3</sup>.

Laparoscopic surgery has emerged as a popular alternative in the management of inguinal hernia surgery in last decade owing to it being safe, feasible, gives a clear view of anatomical structures and vas deferens is not touched, opposite side ring is also seen and can be managed in the same setting<sup>4,5</sup>.

However, many recourse scare centers, still open surgery for inguino-scrotal swellings is relied upon<sup>5,6</sup>. In our setup, we carry out open herniotomy and PPV ligation with minimal complications. Open surgery is preferred due to

lack of resources, increased workload and limited number of skilled surgeons and helping operation theater staff. This study was conducted to report our experience of open inguinal hernia and hydrocele surgery and postoperative complications in our pediatric population.

## MATERIAL AND METHODS

This observational study was conducted at Pediatric Surgery Department, Combined Military Hospital, Lahore, from September 2015 to June 2017 after approval from the Ethics committee of the hospital. Patients from 10 days to 12 years of age diagnosed on the basis of strong history given by parents and on clinical examination, as inguinal hernia and hydrocele were selected for the study by consecutive random sampling. Ultrasound was done in a total of 8 patients to confirm the diagnosis in case of very tense and large hydroceles to rule out suspicion of malignancy. Age, gender of patients and side of the inguino-scrotal swelling were noted. Patients then underwent elective open PPV ligation, hydrocelectomy or herniotomy by senior consultant surgeon as well as by senior resident under direct supervision of the consultant.

All surgeries were done under general anesthesia with prophylactic standard antibiotic dose at the time of anesthesia. All patients were operated through lower skin crease incision of 1 cm. After skin incision, subcutaneous tissues and Scarpas fascia were split, Cremasteric muscle fibres were split to reach the sac. Sac was picked up from the superficial inguinal ring in patients under 2 years of age. On the other hand, inguinal canal was cut by

---

*Department of Pediatric Surgery, CMH, Abdur-Rehman Road Cantt, Lahore, Pakistan*

Correspondence to Dr. Saqib Javaid, Email:, Tel: 00923224459990

giving incision in oblique appenerosis in case of patients greater than 2 years of age and in which sac was not identifiable from superficial inguinal ring. Sac or PPV was ligated at deep ring in all cases after careful separation from vas and vessels. In cases of hydrocele, hydrocelotomy was done by pushing the hydrocele from scrotum and opening the hydrocele sac from superficial inguinal ring. Inguinal canal closed. Wound was closed by 4.0 vicryl in all patients.

In difficult cases, incision was extended, sac was approached and opened and care was taken that all walls of the sacs are separated and transfixed at deep ring. Distil sac was left as such.

Patients were kept Nil Per Oral (NPO) for 3 to 5 hours postoperatively. Gradually oral diet was started. Majority of the patients were operated on day care basis. No post-operative antibiotic was given and patients were discharged at the evening of the operating day or the next day.No antibiotic was prescribed on discharge. Parents were asked to removedressing after 2 days.

Follow up was done at 1 week, 4 weeks, 12weeks, 24 weeks and 1 year to note the postoperative complications of the surgery. Minimum follow up was for 12 weeks and maximum follow up for 1 year. Data was analyzed using SPSS 20. Quantitative variables were expressed as frequency and percentages. Patients with incarcerated, strangulated or obstructed hernia who underwent emergency herniotomy or had other concomitant diseases like Spina bifida, Down’s syndrome, bladder/ cloacalexstrophy and muscular dystrophies, were not included in the study. They were responders, recovered that is why they didn’t show up for further followups and assumed normal.

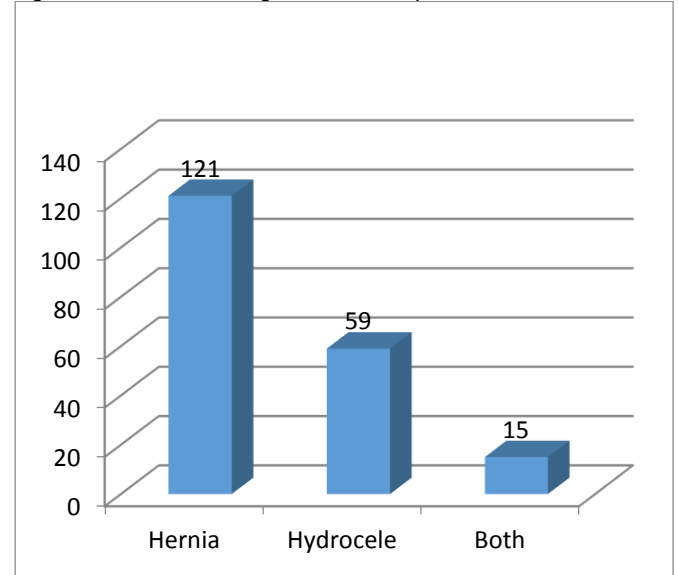
**RESULTS**

Post-operative complications were noted, common complication was scrotal edema noted in 1<sup>st</sup> week. Split granuloma noted in 1<sup>st</sup> two weeks. Hematoma occurred in 2 patients in the 1<sup>st</sup> day. No long term complications were noted within 1 year of follow up. All children followed up for till 4 weeks, 20 patients did not followup after 4 weeks and were assumed normal.

A total of 241 elective PPV ligations and herniotomies were performed at Combined Military Hospital, Lahore in the duration of study. Out of these, 195(80.91%) were male patients, while 46 (19.08%) were female patients. Out of 195 patients, 121(50.20%) were clinically diagnosed as inguinal hernia, 59 (24.48%) as cases of hydrocele and 15

(6.22%) cases having communicating hydrocele along with hernia (Fig. 1).

Fig. Indication of PPV ligation in male patients



Out of 195/241 male patients, 94(48.20%) patients had right sided inguinal hernia/hydrocele, 89 (45.64%) had left sided inguinal hernia/hydrocele and 12(6.15%) had bilateral hernias/hydrocele. A total of 46/241(19.08%) Female patients were operated for herniotomies, out of which 25 (54.34%) having right sided inguinal hernia, 16 (34.78%) had left sided inguinal hernia and 05 (10.86%) had bilateral hernias (Table1).

Post operative complications noted in 41/241 (17.01%). Commonest were scrotal edema in 34 (14.10%), stitch granuloma in 05 (02.07%) and hematoma in 02 (0.83%) patients (Table-2). Almost all complications were noted in male patients, except one stitch granuloma seen in one female patient. No injury to vessels or vas deferens, surgical site infection, recurrence of hernia or testicular atrophy was noted in any of the operated cases during year follow up visits.

Table 1: Gender distribution of Inguinal Hernia in Girls and PPV ligation in Boys (n= 241)

Male =195 (80.91%)			Female= 46 (19.08%)		
right	left	bilateral	Right	Left	bilateral
94	89	12	25	16	5

Table 2 Post operative complications in males

Age	Scrotal edema	Stich granuloma	Heamatoma
Neonate (n=30) Hernia	2	3	1
1-2 years (n= 35) Hernia	8	1	Nil
2-5 years (n=79)			
Hernia- 50	5	1	1
Hydrocele- 15	12		
Both - 14	3		
>5years (n=51)			
Hernia -32	3	Nil	Nil
Hydrocele-18	1		
Both- 01	Nil		

In females- only one stitch granuloma

## DISCUSSION

Congenital inguinal hernia and hydrocele surgery are the most common surgical procedures in Pediatric age group. Hernia needs to be surgically resolved in order to prevent incarceration or strangulation as the diagnosis is made, however there is consensus in wait for spontaneous resolution in hydrocele for 1-2 years (5). In our study, a total of 241 cases electively operated for inguinal hernia and hydrocele.

Out of 241 patients, 195 (80.19%) were male patients and 46 were female (19.08). As long as site is concerned, 119 (59.37%) patients had right sided inguinal hernia, 105 (43.56%) had left sided hernia and 17 (7.05%) bilateral hernia. Our results are supporting the fact that male are much more likely to have hernia than females and right sided hernia and hydrocele are predominant than left sided as reported in other large studies<sup>1,7,8</sup>.

The diagnosis of inguinal hernia and hydrocele was mainly based on well directed history and physical examination. The use of Ultrasound does prove helpful in confirming the diagnosis, in case there is a suspicion of malignancy on examination in tense and large hydrocele<sup>9</sup>.

Laparoscopic surgery for inguinal hernia and communicating hydrocele is widely used all over the world as an alternate for conventional open herniotomy in order to achieve shorter operating time, better cosmetic results, faster recovery and fewer complications<sup>10</sup>. Here, in our setup we perform open hernia and hydrocele surgery because of lack of resources, lack of skilled helping staff, patients and learning constraints. We operate through a small incision (1- 1.5 cm) and as minimal dissection as possible in order to minimize the chance for complications as in practice in many other centers<sup>4,5,6</sup>.

Common post herniotomy and PPV ligations complications which are reported in international literature are injury to vessel and vas deferens, surgical site infection and reoccurrence are considered as major complications having an incidence rate of 2%, 1.2% and 2.9% respectively<sup>11,12</sup>. None of such complications recorded in our study during follow period of 01 year.

In our study, a total of 41 (15.62%) post-operative complications were noted out of which scrotal edema occurred in 34 (14.10%) of patients, stitch granuloma in 05 (2.07%) and hematoma in 02 (0.83%) patients being the least common.

Scrotal edema was observed mostly in children of below 05 years of age, mainly after hydrocelelectomy. Parents may notice scrotal swelling for months after surgery, probably due to the fact that hydrocele is a mesosrotal swelling, in which distal sac remains intact thus increasing the chances of post-op fluid accumulation<sup>13</sup>. In order to prevent and minimize the anxiety of parents due to residual swelling at the site after surgery, they were counseled about swelling and instructed to nurse the baby in diaper as scrotal support. These efforts lead to the resolution of scrotal edema in all the patients over a period 2-4 weeks

Second most common complication was stitch granuloma occurring in 05 (02.07%) patients which was probably due to the use of 4.0 Vicryl suture. In all patients stitch thread has to be cut and removed in outpatients. This complication can be avoided by using a 5.0 Vicryl and applying a deep knot.

Scrotal hematoma occurred in 02 (0.83%) patients during follow up, both required wide bore needle aspiration once and got resolved.

## CONCLUSION

Open surgery for inguinal hernia and hydrocele is still a safe surgery provided vigilant approach is undertaken with minimal tissue handling, yields appreciable results with minimal post-operative complications

## REFERENCES

1. Inguinal hernias and hydroceles in infancy and childhood: A consensus statement of the Canadian Association of Paediatric Surgeons. *Paediatr Child Health*. 2000;5: 461–2.
2. Rafailidis V, Varelas S, Apostolopoulou F, Rafailidis D. Nonobliteration of the Processus Vaginalis. *Journal of Ultrasound in Medicine*. 2016; 35:805-18.
3. Hall NJ, Ron O, Eaton S et al (2011) Surgery for hydrocele in children-an avoidable excess? *J Pediatr Surg*. 2011; 46:2401–2405
4. Ramanathan Saranga Bharathi, Manu Arora, Vasudevan Baskaran, Pediatric Inguinal Hernia: Laparoscopic Versus Open Surgery. *JLS*. 2008; 12: 277–281.
5. Acharya H, Agrawal R, Agrawal V, Tiwari A, Chanchlani R. Management of inguinal hernia in children: a single center experience of 490 patients. *Int Surg J*. 2016;3 : 345-8.
6. Herniotomy in resource-scarce environment: Comparison of incisions and techniques Musa Ibrahim, Kabir Ibrahim Getso, Mohammad Aminu Mohammad, Nurlan Nurkenovich Akhparov, Rassulbek Rakhmanberdievich Aipov. *Afr J Paediatr Surg*. 2015; 12: 45–50.
7. Erdoğan D, Karaman İ, Aslan MK, Karaman A, Çavuşoğlu YH. Analysis of 3776 pediatric inguinal hernia and hydrocele cases in a tertiary center. *Journal of pediatric surgery*. 2013; 48:1767-72.
8. Suvera MS, Damor PB, Patel SV. Surgery for inguinal hernia in pediatric age. *Int J Res Med Sci*. 2013; 1: 112-5.
9. Ashraf Talaat Youssef, Inguinoscrotal and inguinolabial swelling in infancy: Role of ultrasound, *African Journal of Urology*, 2015;4: 201-209
10. Surgical Repair of Pediatric Indirect Inguinal Hernia: Great Waves of Change from Open to Laparoscopic Approach. *J Surg Transplant Sci* 2016; 4: 103411- 13
11. Taqvi SR, Akhtar J, Batool T, Tabassum R, Mirza F. Complications of inguinal hernia surgery in children. *Journal of the College of Physicians and Surgeons-Pakistan: JCPSP*. 2006; 16:532-5.
12. Dhakne BS, Beedkar AN, Dalvi MR, Bhalgat BS. Herniotomy and its outcome in congenital inguinal hernia at a tertiary care hospital: descriptive study. *International Surgery Journal*. 2016; 4:157-61.
13. Sabiston, D. C., and H. K. Lyrly. *Essentials of Surgery*. Philadelphia, PA: W. B. Saunders Co., 1994.