

---

## CASE REPORT

# Renal Tubular Acidosis Type 1 with Nephrocalcinosis, Osteomalacia, Sub Nephrotic Proteinuria and Subclinical Sjogren's Syndrome - A Case Report

AURANGZEB AFZAL, BILAL SHAHID, AIZAZMAND

### SUMMARY

**Background:** Renal tubular acidosis type 1 is associated with medullary nephrocalcinosis and osteomalacia. These conditions are usually not related to any significant proteinuria. This is a case report where these things are associated with significant proteinuria and subclinical sjogren syndrome.

**Case presentation:** A 19 year old female with renal tubular acidosis type 1, nephrocalcinosis, osteomalacia and sub nephrotic proteinuria was discovered to be having deranged renal function tests and positive serological results for sjogren's syndrome. She was treated with heavy dose of potassium citrate and sodium bicarbonate which lead to resolution of proteinuria, renal dysfunction, bone pains and metabolic acidosis without any immunosuppression.

**Conclusion:** Sjogren syndrome may be asymptomatic in renal tubular Acidosis type 1. Correction of hypokalemia and metabolic acidosis can correct associated proteinuria and renal dysfunction.

**Keywords:** Medullary nephrocalcinosis; Renal tubular acidosis type I; Sjogren syndrome.

---

### BACKGROUND

Sjögren's syndrome is an autoimmune disease of exocrine glandular system, affecting mainly the salivary and lacrimal glands. The disease was named after a Swedish ophthalmologist Henrik Sjögren (1899-1986), who first described the clinical manifestations of Sjogren Syndrome. Sjögren's syndrome may be found in association with other autoimmune disorder (e.g., rheumatoid arthritis, systemic lupus erythematosus, and scleroderma). Sjögren's syndrome may also trigger inflammation in extraglandular tissues such as lung, liver, kidney, pancreas, skin, and central nervous system. There are about 4 million people in the United States with manifestations of Sjogren Syndrome<sup>1</sup>.

Sjogren's syndrome has been associated with numerous extraglandular manifestations and could have varied presentations depending upon the order of occurrence of these symptoms<sup>2</sup>.

Although renal tubular acidosis (RTA) coupled with autoimmune interstitial nephritis, develops in a significant number of patients with Sjögren's syndrome (SS), most of the subjects are asymptomatic<sup>3</sup>.

This case report is intended to highlight the fact that the patients without sicca symptoms can develop features of renal tubular acidosis, proteinurea and nephrocalcinosis which shows dramatic improvement with correction of metabolic abnormalities without steroids.

---

*Department of Nephrology, Lahore General Hospital, Lahore  
Correspondence to Dr. Aurangzeb Afzal, Head of Department  
Email: aurangzebafzal@gmail.com*

### CASE PRESENTATION

A 21 year old unmarried female was referred to nephrology Outdoor of a tertiary care hospital of Lahore with history of progressive weakness, bone pains and unexplained hypokalemia for the last 6 months. It was associated with mild frothing of urine but no history of altered color, quantity and frequency. There was no suggestive history of diabetes mellitus, hypertension, autoimmune disease, periodic paralysis, thyrotoxicosis, chronic liver disease, chest pain, dependent edema, gritty feeling in eyes, dry mouth and depression.

She was discovered to be having stable vitals with pulse of 80/min, respiratory rate 20/min, temperature 98.6 F and blood pressure of 110/80 mm of hg. There bilateral upper and lower limb proximal muscle weakness (4/5) along with bowing of lungs. Rest of systemic examination was normal.

On investigations serum potassium of 2.7 mEq/l, Na 139mEq/l, S/creatinine 1.6mg/dl, blood urea nitrogen 26 mg/dl, serum bicarbonate 9mmol/l, serum chloride was 12 mEq/l with anion gap of 7. Serum calcium, magnesium and phosphate were normal. On ABGs, pH 7.21; pCO<sub>2</sub> 17 mmHg; pO<sub>2</sub> was 99mm of Hg, HCO<sub>3</sub> was 9mEq/l, SO<sub>2</sub> was 99%.

Urine routine examination showed pH of 6.2, specific gravity of 1.005 with proteinuria ++. There was no microscopic hematuria. 24-hr urine protein was 2450 mg/day; urine electrolyte level; K: 63mmol/day (25–125), Na 152mmol/day (40–220), phosphorous: 133 mg/day (400–300) Free T<sub>3</sub>, free T<sub>4</sub> and thyroid stimulant hormone levels were all within normal values. 25-OH vit D: 19ng/mL (10–50) Ultrasonography showed normal kidney size with

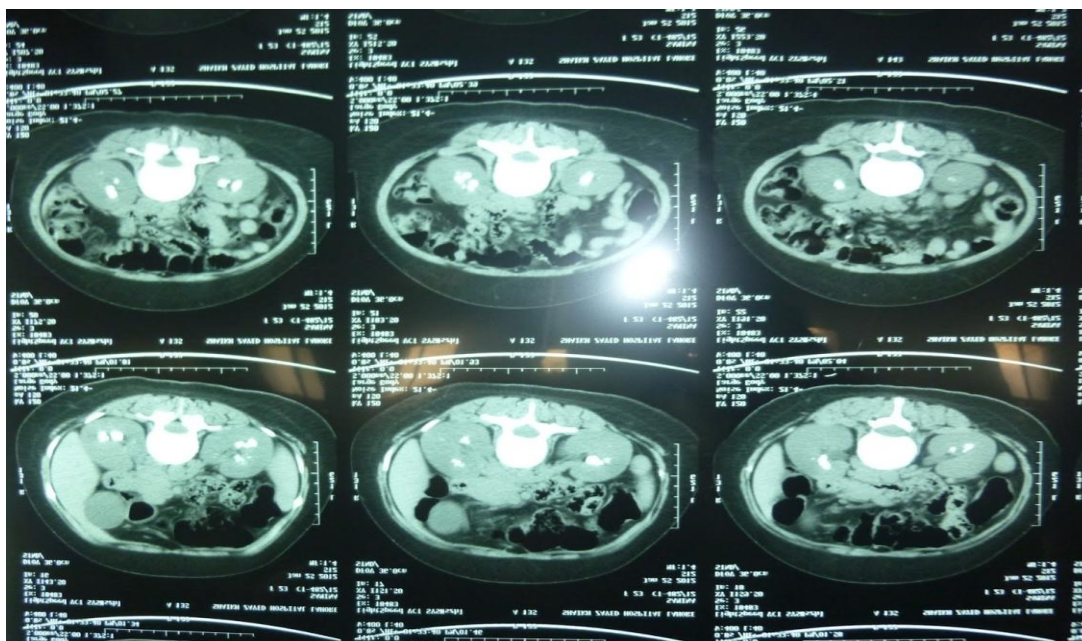
medullary nephrocalcinosis. It was confirmed by X ray and computerized tomography of kidney and urinary bladder.

Antineutrophilic cytoplasmic antibody, complement levels and Antids DNA were normal. Extractable nuclear antigen shows positive anti Ro anti La antibodies. Schirmer's test was negative without any history of gritty feeling in eyes and dry mouth.

Acid load test was not felt necessary for diagnosis of distal renal tubular acidosis, as severe acidosis was present and urine pH was still above 5.3 on 4 different occasion. Urinary anion gap was

positive. She was being managed with Tab potassium citrate (10 mEq) started from 10 mEq thrice a day gradually titrated up to 40 mEq thrice a day. Oral Sodium bicarbonate was added in dose of 1 gram thrice per day gradually titrated to 2 gram thrice per day.

This led to progressive improvement of all abnormalities. Hypokalemia, metabolic acidosis, renal dysfunction and proteinuria turned normal progressively in next 8 weeks. Bone pains improved significantly too. After 3 months she is being maintained on potassium citrate 30mEq/l 3 times a day.



CT KUB of the patient.

## DISCUSSION

RTA is known to have a significant association with medullary nephrocalcinosis either as a causation or consequence. Although the alliance of type I hypokalaemic renal tubular acidosis with medullary nephrocalcinosis is well known, the association of these two clinical conditions with nephrotic syndrome is somewhat rare. Proteinuria in patients with Renal tubular acidosis is frequently regarded as 'tubular' as it usually excretes low molecular weight proteins (less than 40 000Da)<sup>4</sup>. In Sjogren's syndrome higher globulin concentrations and more autoantibodies are found in association with RTA than in association with normal acidification (Talaletal.,1968).The pSS is estimated to have a prevalence of between 0.5 and 2% in different populations, however it remains undiagnosed in a major bulk of patients . About two third of patients suffering from primary sjogren

syndrome develop extraglandular manifestations. Candid renal involvement in primary sjogren syndrome is uncommon and recent literature about the subject showed a clinically significant involvement in exceptionally few number (5%) of cases. Tubular and less commonly, glomerular disease have been reported. Interstitial nephritis is the most frequently reported abnormality on histopathology. Other phenomena such as renal tubular acidosis (RTA), subnephrotic proteinuria, nephrocalcinosis, and chronic kidney disease are also found to occur<sup>5</sup>.Renal involvement in Primary Sjögren's Syndrome may be seen in as much as 27% of cases. In a large case study, a decrease in urinary concentrating capacity was the most frequently observed defect found in 20% of cases<sup>6</sup>. In the study conducted by Andreas V. Goules Thirty-five patients with primary Sjogren Syndrome (4.9%) had clinically significant renal involvement, exhibiting a total follow

up time after renal diagnosis of 252.2 person-years. Thirteen patients (37.1%) had only interstitial nephritis, 17 patients (48.6%) had glomerulonephritis (GN) only, while 5 patients (14.3%) had both defects. Nine patients died (25.7%), 11 developed Chronic Renal Failure (including 4 requiring chronic hemodialysis) (31.4%), and 9 developed lymphoma (25.7%). The overall 5-year survival rate was 85%. Kaplan-Meier analysis showed statistically significant reduced survival for patients of primary Sjogren Syndrome with renal involvement compared to those without renal involvement ( $P < 0.0001$  by log rank test), with increased mortality seen amongst glomerulonephritis patients. Eight of 9 reported deaths (89%) and 8 of 9 lymphomas (89%) were also observed amongst patients with glomerulonephritis<sup>7</sup>. The mechanisms involved in Sjogren Syndrome and RTA are postulated by Cohen et al. among others, to involve the absence of H(1)-ATPase in the cortical collecting tubules. However, other authors, such as Siamopoulos et al. feel that the pathogenesis of RTA is multifactorial and involves the effects of excreted monoclonal proteins and immunologically induced interstitial inflammation. Pokorny et al<sup>5</sup> reported a group of 65 patients with primary Sjogren Syndrome showing extraglandular manifestations either at the onset of or in the midst of the disease throughout. The mean age of the patients at onset was 41.8 years and at the time of definite diagnosis was 45.8 years. There was a 10:1 female predominance. Articular (32 cases), lacrimal (30 cases), and salivary (30 cases) manifestations were the most common initial symptoms. Other symptoms were found to be related to chronic atrophic gastritis (35 patients). Renal involvement was detected in 15 of the 65 patients<sup>8</sup>. Balogun RA et al. describes distal renal tubular acidosis, medullary nephrocalcinosis, and proteinuria in a patient with focal segmental glomerulosclerosis<sup>9</sup>. The previous understanding was to treat the patient with high dose steroids to revert the active disease progress of Sjogren Syndrome associated with renal tubular acidosis and proteinuria or progressive renal insufficiency. This study help established the fact that such patients can be treated without steroids<sup>10,11</sup>.

This case study has a few notable features distinguishing from others. Firstly, our patient was younger by at least 10 years when compared with other studies. There was a diagnostic delay in this patient also just like same other patients described in

literature. The diagnostic delay is not exceptional because with the wide spectrum of subtle manifestations and the multiple confounding signs & symptoms, it is very likely for the patient to present first in other specialties rather than nephrology.

## CONCLUSION

Nephrocalcinosis, distal renal tubular acidosis, and proteinuria occurring in a patient with subclinical Sjogren Syndrome is rare. Potassium citrate should preferentially be used in treating such patients.

## REFERENCES

1. Siamopoulos KC, Elisaf M, Drosos AA, Mavridis AA, Moutsopoulos HM. Renal tubular acidosis in primary Sjogren's syndrome. *Clin Rheumatol* 1992;11(2):226-30.
2. Soy M, Pamuk ON, Gerenli M, Celik Y. A primary Sjogren's syndrome patient with distal renal tubular acidosis, who presented with symptoms of hypokalemic periodic paralysis: Report of a case study and review of the literature. *Rheumatol Int* 2005;26(1):86-9.
3. Fujimoto T, Dohi K. Renal involvement in Sjogren's syndrome—interstitial nephritis and glomerulonephritis (Article in Japanese). *Nihon Rinsho* 1995;53:2495–502.
4. Rasheed A, Balogun1, Nancy D, Adams1, Joseph Palmisano1, Harold Yamase2, Irfans Chughtai1 and Andre A. Kaplan. Focal segmental glomerulosclerosis, proteinuria and nephrocalcinosis associated with renal tubular acidosis. *Nephrol Dial Transplant* (2002) 17: 308–310.
5. Pulukool Sandhya\*,1, Debashish Danda 1, Simon Rajaratnam 2 and Nihal Thomas. Sjogren's, Renal Tubular Acidosis And Osteomalacia - An Asian Indian Series. *The Open Rheumatology Journal*, 2014, 8, 103-109.
6. Sui RUBO,1 Lei ZHANG. Primary Sjogren's Syndrome Presenting with Renal Tubular Acidosis and Central Pontine Myelinolysis: A Case Report. *Turk J Rheumatol* 2013;28(1):58-61.
7. Andreas V. Goules, Ioanna P. Tatouli, Haralampos M. Moutsopoulos, Athanasios G. Tzioufas. Clinically Significant Renal Involvement in Primary Sjogren's Syndrome: Clinical Presentation and Outcome. *Arthritis & Rheumatism*. Volume 65, Issue 11 November 2013 Pages 2945–2953.
8. Gary W. Crooks, Burton Zweiman. Clinical and Diagnostic Laboratory Immunology An Unusual Presentation of Sjogren's Syndrome., July 1996, p. 483–484.
9. Suneth Karunarathne, Yapa Udayakumara, Dumitha Govindapala and Harshini Fernando. Medullary nephrocalcinosis, distal renal tubular acidosis and polycythemia in a patient with nephrotic syndrome. Karunarathne et al. *BMC Nephrology* 2012, 13:66, 1-4.
10. Saeki Y, Ohshima S, Ishida T, et al. Remission of the renal involvement in a patient with primary Sjogren's syndrome (SS) after pulse high-dose corticosteroid infusion therapy. *Clin Rheumatol* 2001;20:225–8.
11. Reddy KS, Jha V, Nada R, et al. Respiratory paralysis in Sjogren syndrome with normal renal function. *Natl Med J India* 2003;16:253–4.