

To Determine the Various Clinical Conditions Presenting with Bleeding per Rectum at Tertiary Centre in Quetta

MOHYUDDIN KAKAR¹, MOBEEN UR REHMAN², MUSHTAQ AHMED JAFFER³

ABSTRACT

Aim: To determine the various clinical conditions presenting with bleeding per rectum.

Methods: This was a cross section analytical study conducted at Sandeman Provincial Hospital Quetta Pediatric surgical ward from February 2015 to November 2015. A total of 45 patients of either sex from ages of One day to 14 year who presented with bleeding per rectum were included with non-probability convenient sampling technique. Patients were admitted via OPD and emergency. Detailed history and physical examination encompassing the duration and comorbid conditions, per rectal and abdominal examination was performed.

Results: 45 patients with bleeding per rectum were evaluated, out of which 2(4.4%) were dysentery, 12 (26%) anal fissure, 10(22%) rectal polyp, 8(17%) intussusception, 5(11%) rectal prolapse, 2(4.4%) abdominal lymphoma, 3(6.6%) meconium ileus, 2(4.4%) necrotizing enterocolitis, 1(2.2%) rectal mass.

Conclusion: Bleeding per rectum is the presenting complaint of a myriad clinical conditions, which should be sought and investigated.

Key words: Clinical condition, Bleeding per rectum, Tertiary centre

INTRODUCTION

Lower gastrointestinal bleeding is a rare condition in childhood pathology¹. Lower GI bleeding was more common among 2-10 year-old children and is rarely encountered in neonates². Gastrointestinal polyps are commonly encountered during childhood and are one of the most common causes of rectal bleeding in this age group³. Primary gastrointestinal malignancy constitutes approximately 2% of paediatric neoplasm⁴. Colorectal polyps are a common cause of gastrointestinal bleeding in children⁵. Colorectal polyps are detected in 6.1% overall and in 12% among those with lower gastrointestinal bleeding during pediatric colonoscopy. Approximately 26% are multiple juvenile or adenoma⁶.

Meckel diverticulum (MD) is one of the most common congenital gastrointestinal anomalies and occurs in 1.2-2% of the general population. MD usually presents with massive painless rectal bleeding, intestinal obstruction or inflammation in children and adults⁷. Solitary rectal ulcer syndrome is a rare benign disorder in children which often goes unrecognized or easily misdiagnosed with other common diseases. It usually presents with rectal bleeding, constipation, mucous discharge, prolonged straining, tenesmus, and lower abdominal pain⁸. Gastric duplication cysts are an uncommon congenital anomaly and rectal bleeding is a rare presentation of a complicated gastric duplication

cyst⁹. When rectal bleeding occurs in an otherwise asymptomatic child, it can be classified as isolated rectal bleeding (IRB). Among the different etiologies suggested for IRB, one of the most common is a hypersensitivity reaction of the bowel mucosa to digested antigens¹⁰. The most frequent clinical presentation of intestinal polyps is painless rectal bleeding¹¹. EDs should be kept in mind when examining patients with an abdominal mass and bleeding per rectum¹². Lower gastrointestinal bleeding (LGIB) along with intestinal perforation is a well-known complication of typhoid fever¹³. Angiodysplasia (vascular malformations) of the colon is extremely rare in children, and, as in adults, present with lower gastrointestinal hemorrhage¹⁴.

PATIENTS AND METHODS

This study was conducted in the Department of Paediatric Surgery Civil Hospital Quetta. Duration of this study was from February 2015 to November 2015. Study design was cross section analytical. Children included in this study were from 1 day to 15 years of age. Both genders were included. The patients were admitted via OPD and emergency.

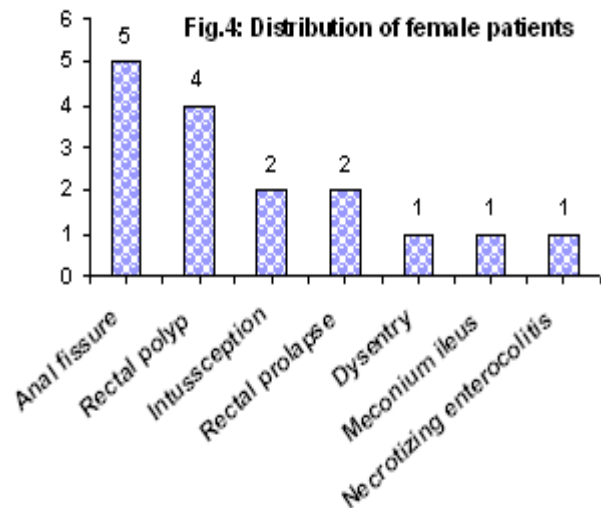
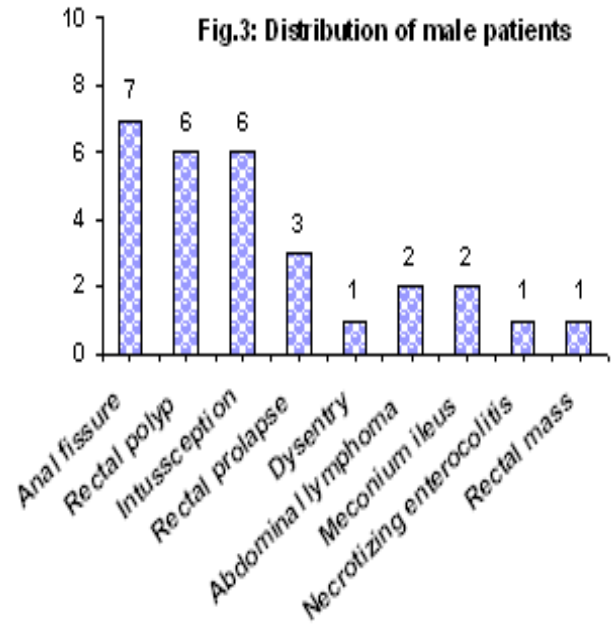
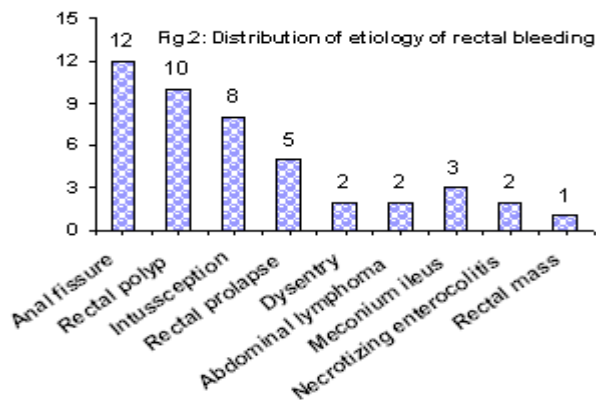
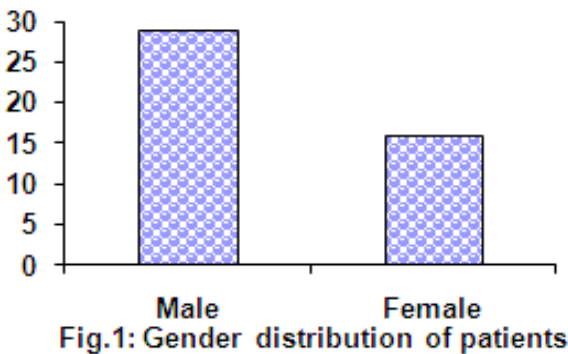
RESULTS

In our study the male to female ratio was 1.6:1. Anal fissure was the most encountered entity which accounted for 26% of total cases. Out of anal fissure patients 58.33% were male and 41.73% were female. These accounted for 15.5% and 11.1% of total cases

¹Department of Pediatric Surgery,

^{2,3}Department of Pediatric Medicine, Bolan Medical College Quetta
Correspondence to Dr. Mobeen-ur-Rehman e-mail:
mobin38@gmail.com

gender wise. The second most common etiology seen in our study was rectal polyp which was present in 22.22% of cases. Out of these 60% were male and 40 % were female. These accounted for 13.3% and 8.8% of total cases gender wise. All patients were 5 to 7 years of age in this group. Intussusception was the third most common diagnosis in this study. It accounted for 17% of cases and age ranged from 4 to 9 months. Out of these 75% were male and 25% were female. Overall these accounted for 13.3% and 4.4% gender wise in total study. The next most common diagnosis was rectal prolapse which was 11.11% of total cases. These patients ranged from 4 to 6 years of age. Out of these 60% were male and 40% were female. Gender wise they accounted for 6.6% and 4.4%. of total cases. Dysentery accounted for 4.4% of total cases and age group ranging from 5 to 6 years of age. Two thirds of the dysentery patients were male and one third was female. Gender wise they constituted 4.4% and 2.2% of cases respectively. 4.4% of patients had abdominal lymphoma and 100% were male. 6.6% of patients were diagnosed and treated as meconium ileus and they ranged from 3 to 5 days of age. Two thirds were male and one third was female. 4.4% of cases had necrotizing enterocolitis with half male and half female patients. 2.2% of cases presented with rectal mass and all were male.



DISCUSSION

Lower gastrointestinal bleeding refers to blood loss originating from a site distal to the ligament of Treitz. The aetiology varies depending on the age of patients. Excluding benign anorectal pathology in children and young people, Meckel's diverticulum, juvenile polyps and inflammatory bowel disease are the main causes¹⁵. Bleeding per rectum is an uncommon presentation in pediatric patients¹⁶. Gastrointestinal hemorrhage in children is a critical condition that demands quick and effective management. The differential diagnosis of gastrointestinal hemorrhage is wide¹⁷. Rectal bleeding therefore should not be ignored but

evaluated further with at least a digital rectal examination and a sigmoidoscopy¹⁸. Currently we are no nearer than 10 or 20 years ago providing a safe, adequate, and effective round-the-clock endoscopic services for acute life-threatening gastrointestinal bleeding in children¹⁹.

The gender ratio in our study was similar to one Iranian study carried out in 2009²⁰. In a study carried out by Rouge, Houdu et al the frequency of anal fissures was 58.8% which is much higher than in our study. Mapel and Schum showed that the frequency of females with anal fissure was higher than in our study. The difference could be due to racial and dietary factors.

The frequency of rectal polyp was higher in our study than found in the study done in Ivory coast²¹ but less than found by Egyptian workers^{22,23}. Our male predominance in cases of intussusception was noted in other international studies as well²⁴. The WHO recommendation of sentinel hospital based surveillance for post-marketing surveillance after rotavirus vaccine introduction is likely to a better approach than active surveillance²⁵. The frequency of intussusception was higher in our study than found by Egyptian workers.²³ Rectal prolapse in pediatrics has its highest incidence in infancy and is uncommonly seen in industrialized countries²⁶. The mean age of presentation in our study was higher than found in an Iranian study²⁷. Our frequency of amoebic dysentery was less than found by Indian workers which may be difference of hygiene²⁸. Non-Hodgkin's lymphoma (NHL) is a relatively common childhood cancer that can present in a myriad of ways²⁹. Lymphomas are the third most common cancer in children and Burkitt lymphoma (BL) accounts for about 40% of them. The rectum is extremely seldom involved in BL³⁰. Workers have found it to be an insignificant cause of rectal bleeding³¹.

CONCLUSION

Bleeding per rectum is the presenting complaint of myriad clinical conditions, which should be sought and investigated.

REFERENCES

1. Yankov IV, Spasova MI, Andonov VN, Cholakova EN, Yonkov AS. Endoscopic diagnosis of intramural hematoma in the colon sigmoideum in a child with high titer inhibitory hemophilia A. *Folia Med (Plovdiv)* 2014;56(2):126-8.
2. Zahmatkeshan M, Fallahzadeh E, Najib K, Geramizadeh B, Haghighat M, Imanieh MH. Etiology of lower gastrointestinal bleeding in children: a single center experience from southern iran. *Middle East J Dig Dis* 2012;4(4):216-23.
3. Kay M, Eng K, Wyllie R. Colonic polyps and polyposis syndromes in pediatric patients. *Curr Opin Pediatr* 2015;27(5):634-41.
4. Debnath CR, Debnath MR, Gafur MA, Huq MH. A 12 years old boy with carcinoma rectum. *Mymensingh Med J* 2010;19(1):116-8.
5. Thakkar K, Fishman DS, Gilger MA. Colorectal polyps in childhood. *Curr Opin Pediatr* 2012;24(5):632-7.
6. Thakkar K, Alsarraj A, Fong E, Holub JL, Gilger MA, El Serag HB. Prevalence of colorectal polyps in pediatric colonoscopy. *Dig Dis Sci* 2012;57(4):1050-5.
7. Park JS, Lim CW, Park T, Cho JM, Seo JH, Youn HS. Suppurative meckel diiverticulum in a 3-year-old girl presenting with periumbilical cellulitis. *Pediatr Gastroenterol Hepatol Nutr* 2015;18(1):66-70.
8. Urganc N, Kalyoncu D, Usta M, Eken KG. A rare cause of severe rectal bleeding: solitary rectal ulcer syndrome. *Pediatr Emerg Care* 2014;30(10):736-8.
9. Surridge CA, Goodier MD. Gastric duplication cyst: A cause of rectal bleeding in a young child. *Afr J Paediatr Surg* 2014;11(3):267-8.
10. Reiter O, Morag I, Mazkereth R, Strauss T, Maayan-Metzger A. Neonatal isolated rectal bleeding and the risk of hypersensitivity syndromes. *J Perinatol* 2014;34(1):39-42.
11. Caiulo S, Moramarco F, Caiulo VA. Juvenile polyp. *Eur J Pediatr* 2014;173(1):125.
12. Rasool N, Safdar CA, Ahmad A, Kanwal S. Enteric duplication in children: clinical presentation and outcome. *Singapore Med J* 2013;54(6):343-6.
13. Shaikhani MA, Husein HA, Karbuli TA, Mohamed MA. Colonoscopic findings and management of patients with outbreak typhoid fever presenting with lower gastrointestinal bleeding. *Indian J Gastroenterol* 2013;32(5):335-40.
14. Yannam GR, Yu DC, Kelly DR, Chen MK, Beierle EA. Angiodysplasia (vascular malformations) of the colon presenting as an acute abdomen. *J Pediatr Surg* 2012;47(10):e37-40.
15. Ruiz Clavijo D, Fernandez-Urien I, Vila JJ, Goni S, Gonzalez de la Higuera B, Martinez Echeverria A. [Severe lower gastrointestinal bleeding in a 25-year-old patient]. *An Sist Sanit Navar* 2012;35(3):517-20.
16. Al-Hussaini A, Lone K, Al-Sofyani M, El Bagir A. Gastric heterotopia of rectum in a child: a mimicker of solitary rectal ulcer syndrome. *Ann Saudi Med* 2014;34(3):245-9.
17. Karakus SC, Sarsu SB, Celtik C, Gokce S, Koku N. Rare causes of gastrointestinal hemorrhage in infancy. *Pediatr Int* 2015;57(2):304-7.
18. Mukherji A, Rathi AK, Sharma K, Kumar V, Singh K, Bahadur AK. A study on presentation and behavior of colo-rectal carcinoma in young Indian patients. *Trop Gastroenterol* 2011;32(2):122-7.
19. Thomson M, Belsha D. Endoscopic management of acute gastrointestinal bleeding in children: Time for a radical rethink. *J Pediatr Surg* 2015.
20. Haghi Ashtiani MT, Monajemzadeh M, Motamed F, Moradi Tabriz H, Mahjoub F, Karamian H, et al. Colorectal polyps: a clinical, endoscopic and

- pathologic study in Iranian children. *Med Princ Pract* 2009;18(1):53-6.
21. Okon JB, N'Dri N, Toth'o A, Assi C, Diakite M, Soro D, et al. [Diagnosis of hematochezia in Abidjan Cocody University Hospital (Ivory Coast)]. *Med Sante Trop* 2012;22(4):398-400.
 22. El-Shabrawi MH, El Din ZE, Isa M, Kamal N, Hassanin F, El-Koofy N, et al. Colorectal polyps: a frequently-missed cause of rectal bleeding in Egyptian children. *Ann Trop Paediatr* 2011;31(3):213-8.
 23. El-Khayat HA, El-Hodhod MA, Abd El-Basset FZ, Tomoum HY, El-Safory HA, Hamdy AM. Rectal bleeding in Egyptian children. *Ann Trop Paediatr* 2006;26(4):337-44.
 24. Singh JV, Kamath V, Shetty R, Kumar V, Prasad R, Saluja T, et al. Retrospective surveillance for intussusception in children aged less than five years at two tertiary care centers in India. *Vaccine* 2014;32 Suppl 1:A95-8.
 25. Jehangir S, John J, Rajkumar S, Mani B, Srinivasan R, Kang G. Intussusception in southern India: comparison of retrospective analysis and active surveillance. *Vaccine* 2014;32 Suppl 1:A99-103.
 26. Siafakas C, Vottler TP, Andersen JM. Rectal prolapse in pediatrics. *Clin Pediatr (Phila)* 1999;38(2):63-72.
 27. Sarmast MH, Askarpour S, Peyvasteh M, Javaherizadeh H, Mooghehi-Nezhad M. Rectal prolapse in children: a study of 71 cases. *Prz Gastroenterol* 2015;10(2):105-7.
 28. Khurana AK, Saraya A, Jain N, Chandra M, Kulshreshta R. Profile of lower gastrointestinal bleeding in children from a tropical country. *Trop Gastroenterol* 1998;19(2):70-1.
 29. Foley RW, Aworanti OM, Gorman L, McGovern B, O'Sullivan M, Smith OP, et al. Unusual childhood presentations of abdominal non-Hodgkin's lymphoma. *Pediatr Int* 2015.
 30. Favini F, Massimino M, Esposito V, Maestri L, Fava G, Spreafico F. Rectal burkitt lymphoma in childhood. *J Pediatr Hematol Oncol* 2008;30(2):176-8.
 31. Meyer CT, Wilsey MJ, Hale GA, Monforte HL, Danielson PD. Primary Burkitt's lymphoma of the colon--an uncommon cause of acute constipation and abdominal pain. *Fetal Pediatr Pathol* 2012;31(4):254-9.