

# Role of CT Angiography in Preoperative Vascular Mapping of Potential Renal Donors

TAYYABA AFZAL, SALAHUDDIN, AALIYA HALEEM

## ABSTRACT

**Background:** CT Angiography is a reliable and non invasive technique for pre operative evaluation of potential kidney donors especially for vascular mapping. The aim of this study is to evaluate the prevalence of various anatomic variations regarding the renal vessels that can be detected on MDCT.

**Methods:** A descriptive study was conducted in the Radiology Department of CMH, Rawalpindi from 1 July 2013 to 31 August 2015. Totally 105 patients who were candidates for kidney donation underwent CT Angiography (16 slice Philips Brilliance). The contrast enhanced scans were achieved by doing arterial and venous phase imaging at 25 and 55 seconds respectively from the start of injection of 100 ml of intravenous contrast at an injection rate of 3-5ml/sec. Multi planar reconstructions along with 3 D volumetric and MIP images were reviewed by an experienced consultant radiologist.

**Results:** Out of 105 potential donors, accessory renal artery was detected in 29(27.6%), accessory renal vein in 9(8.57%). 16 patients (15.23%) had early branching renal artery whereas 8(7.61%) had late confluence of renal vein. Retro aortic and circumaortic renal vein was seen in 3 and 1 patient (2.85% and 0.95%) respectively.

**Conclusion:** CT Angiography should be used as the primary imaging modality for pre operative workup of potential renal donors especially for evaluation of normal as well as variant vascular anatomy thereby eliminating the need for more invasive procedures like catheter angiography.

**Keywords:** Kidney, renal artery, renal vein

---

## INTRODUCTION

As renal transplant from living related donors is treatment of choice for end stage renal disease, proper pre operative evaluation has become more important<sup>1,2</sup>. Successful transplantation requires detailed assessment of the donor to reduce the incidence of complications which can threaten survival of the graft as well as recipient<sup>3,4</sup>. Preoperative screening not only helps in the selection of the patient but also facilitates in the decision whether to harvest right or left kidney. Laparoscopic donor nephrectomy is more technically challenging because of limited field of view and in these patients accurate and detailed preoperative imaging becomes more important. CT angiography is a reliable diagnostic tool for detection and evaluation of normal as well as variant vascular anatomy<sup>5,6</sup>. In preoperative planning helical CT angiography has replaced catheter angiography with reasonable good accuracy in depiction of normal as well as variant renal anatomy<sup>7</sup>.

MDCT offers faster image acquisition times with near isotropic data acquisition in multiple vascular phases. Overall it enables improved spatial or temporal resolution while decreasing motion and

improving partial volume artifacts and reducing radiation dose. Radiologists are responsible for providing accurate anatomic information about the donor's renal parenchyma, arteries, veins and collecting system. As elsewhere reporting accuracy depends on the radiologist's level of expertise, attention to detail as well as commitment to careful image evaluation<sup>8</sup>.

Literature search doesn't show any data giving the exact incidence of duplication of renal vessels as well as other vascular variations in our population. So a comprehensive study was conducted with this purpose in mind.

## MATERIAL AND METHODS

The objective of the study was to describe the spectrum of vascular variations seen on CT angiography in potential kidney donors. This was a descriptive study with non-probability convenience sampling. Patients underwent serum urea and creatinine examination as a prerequisite of undergoing contrast enhanced CT examination. Patients with normal renal profile were given appointment for CT Angiography. From 1 July 2013 to 31 August 2015 total number of 105 potential donors underwent MDCT Angiography with 16 slice Philips Brilliance at CMH Rawalpindi.

---

*Department of Radiology, CMH, Rawalpindi*  
*Correspondence to Dr. Tayyaba Afzal, Classified*  
*Radiologist Email: drzaafir@yahoo.com>*

After 3-6 hours fasting, each patient ingested 750 ml of water over 30 - 45 minute period as he or she waited for CT examination. History of any allergy to intravenous contrast was excluded. An informed consent was taken after explanation of the CTA procedure and the technique of breath holding. For administration of IV contrast an 18 G canula was inserted into a peripheral vein. A scout film was obtained. Then in every case arterial and venous phase imaging was done at 25 and 55 sec respectively from the start of injection of 100ml of intravenous contrast at an injection rate of 3 -5 ml/sec. The area scanned extended from above the level of kidneys to aortic bifurcation in arterial phase and from the level of kidneys to iliac crest in venous phase. The contrast enhanced scans were achieved using 2 mm collimation with a pitch of 7.5. After 5-10 minutes delay scan was repeated to visualize the collecting system and ureters.

Axial data was reconstructed with 1 mm overlapping reconstruction. The data was transferred to work station where multi planar reconstructions along with 3 D volumetric and MIP images were reviewed by an experienced consultant radiologist. Number of bilateral renal arteries, veins, early branching of renal artery, late confluence of renal vein any other normal variant as well as any incidental pathology in kidneys as well as elsewhere in abdomen was commented upon. Accessory renal artery may arise from aorta as well as iliac, coelic or mesenteric artery and may be polar or hilar. An early division of renal artery is described as occurring less than 1.5cm from lateral aortic wall on left and in retrocaval portion on right. Late venous confluence is considered when venous branches join within less than 1.5 cm of lateral aortic wall on left or at a distance of less than 1.5cm from its confluence with IVC on right. Presence of circumaortic as well as retroaortic left renal vein was also commented upon. All scans were also analysed in detail to exclude any pathology /incidental finding in the kidneys as well as elsewhere in abdomen. All analyses were performed using SPSS version 18. Incidence of occurrence of various variables as well as their relative percentage was calculated.

**RESULTS**

The number of patients included in this study was one hundred and five (105). Mean age of the patients was 39 years. 59 patients were male whereas 41 were female. 95 patients were either a blood relation of the intended recipient or was related through marriage. Renal accessory artery was detected in 29 patients (14 polar and 15 hilar). Accessory renal vein was detected in 9 patients (4 on right side, 5 on left

and one bilateral). Early branching renal artery was identified in 16 patients (5 on right side, 8 on left side and 3 bilateral). Moreover 8 patients showed late confluence of renal vein (6 on left, 1 on right and 1 bilateral). 3 patients had retroaortic renal vein whereas 1 had circumaortic renal vein. 10 patients had renal stones (5 on right side, in 4 on left side whereas bilateral in 1 patient). Renal cell carcinoma was incidentally discovered in one patient whereas one patient had right sided ureteric duplication along with bilateral accessory renal arteries and therefore was considered unsuitable as a potential donor. Other incidental abdominal findings included gall stones in 5 patients, abdominal lymphadenopathy in 3 and hepatic nodules in 2 (Table 2).

Table 1:

CTA Findings	Incidence %age
Renal accessory artery	29(27.6%)
Renal accessory vein	9(8.57%)
Early branching renal artery	16(15.23%)
Late confluence renal vein	8(7.61%)
Retroaortic renal vein	3(2.85%)
Circumaortic renal vein	1(0.95%)
Renal stone	10(9.52%)
Other incidental findings	10(9.52%)

Fig. 1: Gender distribution of potential donors (n=105)

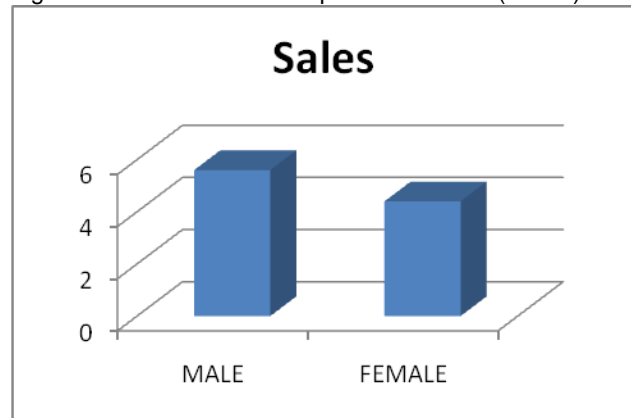


Fig. 2: CT scan of a 25 year old male showing right accessory renal artery

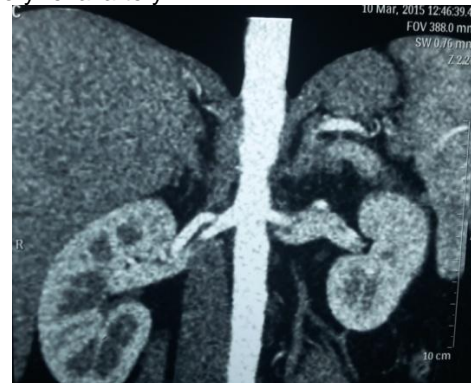

Fig. 3: CTA Volumetric reformation of a potential donor showing bilateral accessory renal arteries

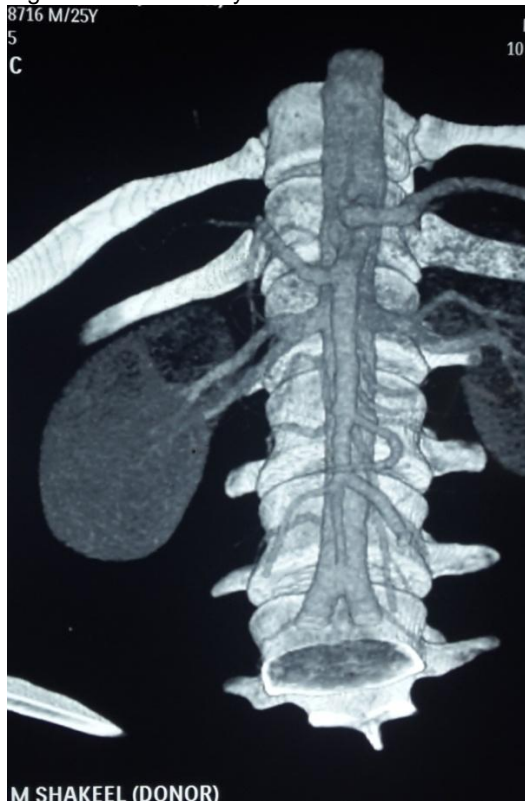
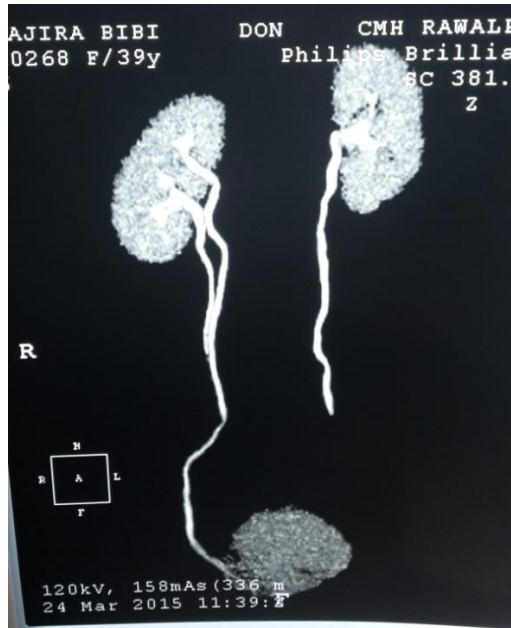
Fig. 4: CT Volumetric reformations during the delayed phase showing right sided duplicated ureter. The same patient had early division of left renal artery and was considered an unsuitable candidate though renal harvesting is not absolutely contraindicated from such patients



## DISCUSSION

As an organ kidney has one of the highest incidence of variant vascular anatomy. Precise pre operative mapping of renal arterial as well as venous anatomy is a prerequisite for successful surgery. The anatomical information required before conventional transplant surgery includes number,length,location and branching pattern of renal arteries as well as the status of donor kidney's collecting system<sup>9,10</sup>. CT also provides accurate definition of renal as well as adrenal, gonadal and lumbar vein.<sup>11</sup> Detailed knowledge of venous anatomy is also essential to reduce the incidence and amount of renal bed hemorrhage which can compromise survival of the graft and even that of the donor. Multiple renal arteries as well as anomalous venous drainage is not a contraindication to harvesting of the involved kidney but they are less problematic when identified in detail by preoperative mapping<sup>12</sup>.Multidetector CT has a reported accuracy of 95-100% for vascular anatomy with the use of 4,8,16 or 64 row scanners<sup>13,14,15</sup>. It is preferred over MR angiography due to better spatial resolution and reduced imaging time.

MDCT helps in deciding which kidney is to be harvested.If one kidney is altered but not contraindicated for transplantation and then the altered kidney is transplanted. Moreover CT angiography was well tolerated by all the patients and none of the patients reported any serious side effects from the examination.Most of the patients were young and healthy as mean age was 39 years. Majority of patients(95/105, 90.47%) were related to the recipient. This is consistent with our social norms.

Most of our other findings were in line with results of previous studies. Incidence of renal accessory artery in our study was 29% whereas in other studies it was 23 -40%<sup>4,8,16,17</sup>.However, renal cell carcinoma was incidentally discovered in one patient,hepatocellularcarcinoma in one and hepatic metastasis in one patient. So 2.85 % of the otherwise healthy subjects had undiagnosed malignancy.

## CONCLUSION

Need for renal transplantation has undergone exponential growth and cadaveric donations are inadequate to meet this ever increasing demand with consequential increased requirement for living donors<sup>18</sup>.Renal vascular anomalies are commonly encountered during living donor kidney workup. The accuracy of computed tomography in their preoperative evaluation is well documented. Multi detector CT combined with 3 D CT angiography can provide a minimally invasive and accurate

preoperative evaluation of potential kidney donors in a single study.

## REFERENCES

1. Rubin GD, Alfrey EJ, Dake MD, et al. Assessment of living renal donors with spiral CT. *Radiology*.1995;195(2):457-62
2. Kim JK, Park SY, Kim HJ et al. Living donor kidneys: usefulness of multidetector row CT for comprehensive evaluation. *Radiology* 2003; 229:669-76
3. Kawamoto S, Montgomery RA, Lawler LP, Horton KM, Fishman EK. Multidetector CT angiography for preoperative evaluation of living laparoscopic kidney donors. *AJR Am J Roentgenol*. 2003 Jun;180(6):1633-8.
4. Rydberg J, Kopecky KK, Tann M, Persohn SA, Leapman SB, Filo RS, et al. Evaluation of prospective living renal donors for laparoscopic nephrectomy with multidetector CT: the marriage of minimally invasive imaging with minimally invasive surgery. *Radiographics*. 2001 Oct; 21: S223-36.
5. Urban BA, Ratner LE, Fishman EK. Three dimensional volume rendered CT angiography of the renal arteries and veins: normal anatomy, variants, and clinical applications. *Radiographics* 2001; 21: 373-86.
6. F. Fraioli, C. Catalano, L. Bertolotti, M. Danti, F. Fanelli, A. Napoli, M. Cavacece, R. Passariello. Multidetector-row CT angiography of renal artery stenosis in 50 consecutive patients: prospective interobserver comparison with DSA. *Radiol med*(2006) 111: 459-68.
7. Rubin GD, Alfrey EJ, Dake MD, et al. Assessment of living renal donors with spiral CT. *Radiology* 1995; 195:457-462
8. Pozniak MA, Balison DJ, Lee FT, Tambeaux RH, Uehling DT, Moon TD. CT angiography of potential renal transplant donors. *Radio Graphics* 1998; 18(3): 565–587.
9. Derauf B, Goldberg ME. Angiographic assessment of potential renal transplant donors. *Radiol Clin North Am* 1987; 25:261–265.
10. Walker TG, Geller SC, Delmonico FL, Waltman AC, Athanasoulis CA. Donor renal angiography: its influence on the decision to use the right or left kidney. *AJR* 1988; 151:1149–1151
11. Smith PA, Ratner LE, Lynch FC, Corl FM, Fishman EK. Role of CT angiography in the preoperative evaluation for laparoscopic nephrectomy. *RadioGraphics*
12. Mandal AK, Cohen C, Montgomery RA, Kavoussi LR, Ratner LE. Should the indications for laparoscopic live donor nephrectomy of the right kidney be the same as for the open procedure? anomalous left renal vasculature is not a contraindication to laparoscopic left donor nephrectomy. *Transplantation* 2001; 71:660–664
13. Türkvatan A, Akinci S, Yildiz S, Olçer T, Cumhuri T. MDCT for preoperative evaluation of vascular anatomy in living renal donors. *Surg Radiol Anat* 2009; 31(4):227–235.
14. Blondin D, Andersen K, Kroepil P et al. Analysis of 64-row multidetector CT images for preoperative angiographic evaluation of potential living kidney donors [in German]. *Radiologe* 2008; 48(7):673–680
15. Pollak R, Prusak BF, Mozes MF. Anatomic abnormalities of cadaver kidneys procured for purposes of transplantation. *Am Surg* 1986; 52:233-56.
16. Neymark E, La Berge JM, Hirose R, Melzer JS, Kerlan RK Jr, Wilson MW, et al. Arteriographic detection of renovascular disease in potential renal donors: incidence and effect on donor surgery. *Radiology* 2000; 214: 755-60.
17. Sebastia C, Peri L, Salvador R, Bunesch L, Revuleta I et al. Multidetector CT of living renal donors: Lessons learned from surgeons. 2010 Nov; 30 (7).