

The Role of Diagnostic Laparoscopy for Acute Abdominal Conditions: An Evidence-Based Review

MOHAMMAD IQBAL ADIL, ANWAR ZEB*

ABSTRACT

Aim: To prove that the diagnostic laparoscopy plays a major role in acute surgical emergencies.

Duration & Place of study .Twenty five patients were seen as an emergency in Ittefaq Hospital, Lahore Pakistan from August 2015 until December 2015 with acute abdomen.

Methods: Twenty five different patients were seen as an emergency with acute abdomen. Clinical diagnosis made with history, examination haematological, biochemical and diagnostic radiology followed by diagnostic laparoscopy and definite procedure carried out in Ittefaq hospital in 6 months.

Results: It was confirmed that diagnostic laparoscopy is far superior tool not only in diagnostic but in therapeutic procedures and is far superior investigation compare to radiological investigation in acute emergencies.

Conclusion: Diagnostic laparoscopy has a major role in life saving procedures in acute emergencies for making correct diagnosis in surgical dilemmas and correct treatment.

Keywords: Diagnostic laparoscopy, Outcomes, Acute abdomen, surgical intervention, Critical care.

INTRODUCTION

Diagnostic laparoscopy is minimally invasive surgery for the diagnosis of intraabdominal diseases. This study aim was a critical examination of the available literature on the role of laparoscopy for the diagnosis and treatment of acute intra abdominal conditions. A systematic study was performed for the period August 2015 until December 2015 for 25 patients admitted in Ittefaq Hospital Trust under my care as an emergency. The level of evidence in the identified articles was graded. This review examines the role of diagnostic laparoscopy for acute abdominal pain and the acute abdomen experienced by the critically ill patients admitted. The indications, contraindications, risks, benefits, diagnostic accuracy of the procedure, and associated morbidity are discussed. The limitations of the available literature are highlighted, and evidence-based recommendations for the use of diagnostic laparoscopy to determine acute intra-abdominal conditions are provided from the literature.

METHODS

Study carried out for abdominal surgery .The aim was to develop evidence-based recommendations for the most common diseases that may cause acute abdominal pain. Diagnostic laparoscopic tools and expertise required to provide high standard of surgery and results.

*Associate Professor, MBBS Medical College ,AJK
*S.R.Surgery, Lahore General Hospital, Lahore
Correspondence to Dr. Mohammad Iqbal Adil, Consultant
General & Laparoscopic & Breast Surgeon, Ittefaq
Hospital, Lahore Email: drmiadil@hotmail.com
Cell: 0347-4125674*

RESULTS

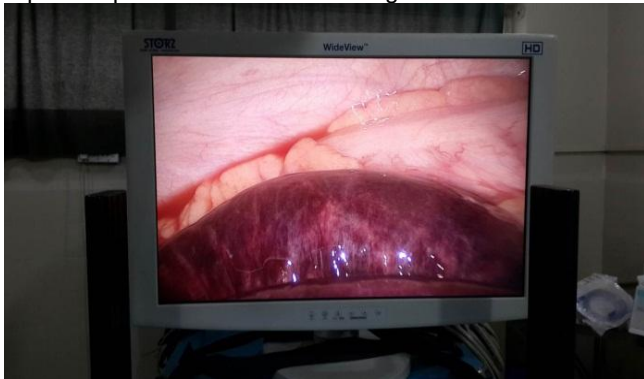We did study on twenty five surgical patients admitted under my care as an emergency with acute abdomen. Some patients and relatives made self-referral from other hospitals, some were referred by medical consultant colleagues after ultra sound scan and some admitted through accident and emergency in Ittefaq Hospital Trust Lahore from August 2015 to December 2015.

First patient was 30 years old mother of 3 admitted as an emergency with abdominal pain of 3 days duration She was very unwell, dehydrated, hypotensive and tachycardia .Her abdomen was tender with sigs of generalised peritonitis. She had raised inflammatory markers and her Chest X Ray showed no gas under the diaphragm .However, her abdominal x-rays showed some distended bowel loops .She was admitted in Surgical ICU and resuscitated with fluids, IV antibiotics and catheterisation before taking to theatre for diagnostic laparoscopy and proceed.

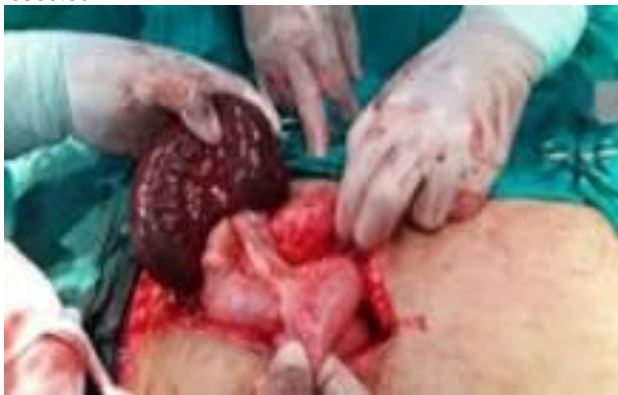Interestingly she was taken to 4 different hospitals in the Lahore city and diagnosis of acute appendicitis was made on the basis of clinical examination and ultrasound scan but luckily family and her husband refused the treatment because of dissatisfaction of the treatment offered by these hospitals. On examination she was tender all over her abdomen with signs of peritonism .There was no clear signs of appendicitis. Therefore, I took her to theatre and performed diagnostic laparoscopy where I found ischaemic bowel involving terminal ileum with some free intraperitoneal fluids. She had normal appendix. I then converted laparoscopy to open

laparotomy and did resection anastomosis of the small bowel with side to side anastomosis with the Linear Stapler 75. She made marvellous recovery and was discharged after 5 days of operation. She was followed subsequently in Outpatients and had no issue whatsoever. Finally discharged as a happy patient and a family. Histology confirmed ischaemic small intestine due to infarction. Had she been operated for appendectomy in other hospitals through classical incision she would have died due to missed diagnosis .

Laparoscopic view of the ischaemic gut



Laparotomy showing ischaemic small intestine which was resected

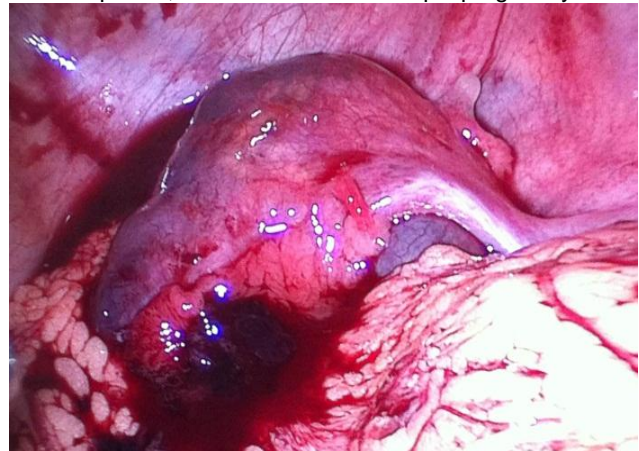


Second patient was 26 years old recently married women who were admitted under the medical team with 2 days history of RIF pain. She was admitted under medical team with lower abdominal pain .She also had some spotting per vagina but had normal periods. Her last period was 4 weeks ago .She had an ultrasound scan arranged by medical team which showed as following "Anteverted uterus, Mild endometriosis, no PID or pelvic fluid seen, normal ovaries. Possibility of appendicitis could not be ruled out".

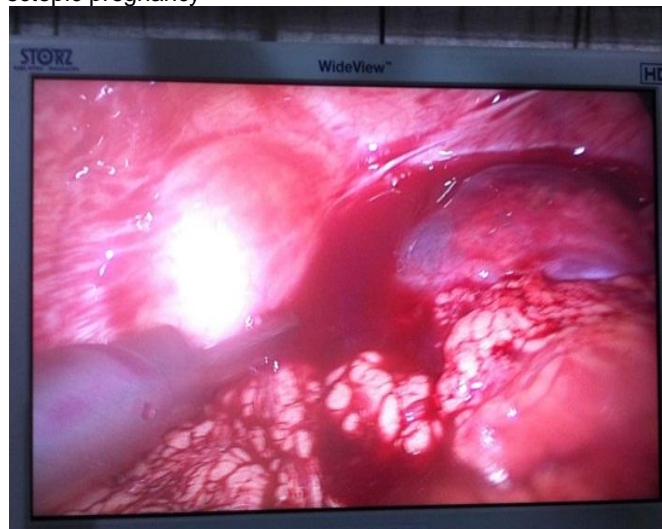
History, examination and investigations did not fit into the appendicitis .She had normal bloods with no leucocytosis. She also had normal urinalysis

.Pregnancy test was carried out which was negative .On examination she looked pale and unwell with tender lower and right side of abdomen with some guarding .I proceeded with diagnostic laparoscopy which showed approximately 1.5 litres of blood in the pelvis and ectopic pregnancy in her right fallopian tube and trophoblast . She had normal appendix .On call Gynaecologist was called in theatre who confirmed the diagnosis of ectopic pregnancy .Because of her limitations in laparoscopic surgery I performed right Salpingectomy laparoscopically and removed the trophoblast and sent it for histology. Pelvis was washed out thoroughly and 1.5 litres of blood drained .She made excellent recovery and was discharged on 4th post-operative day. Histology confirmed trophoblast due to ectopic pregnancy. Had she operated for appendectomy through open technique a major pathology could have been missed up threatening to her life.

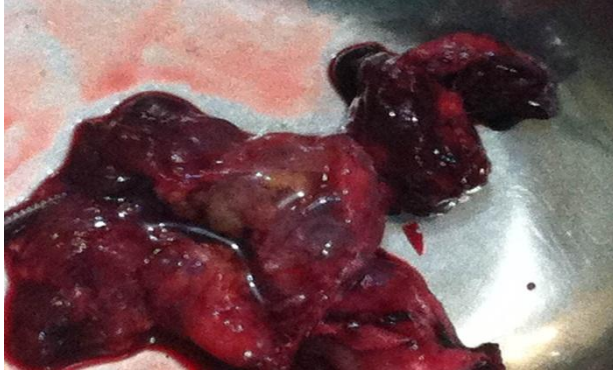Blood in pelvis , dilated uterus and ectopic pregnancy



Laparoscopic view, blood in pelvis, dilated uterus and ectopic pregnancy



Trophoblast of ectopic pregnancy



Third patient was admitted under my care with chronic abdominal pain since she had C Section 3 months ago under a gynaecologist. As she treated initially by the gynaecologist therefore they were called in but they refused to take over. Therefore, we continued treating her. Her CT showed some fluid filled cavities. She was offered laparoscopy but refused. She was then treated conservatively and discharged. After that she had multiple admissions in various hospitals with the ongoing abdominal pain without improvement. She was admitted in neighbouring hospital on 20 November 2015 where she was offered Laparotomy. But On 24 November 2015, she was self discharged from a local private hospital in Lahore and admitted under my care in Ittefaq hospital as an emergency for the further treatment. She was looking unwell with normal vital signs. She had tender abdomen with no signs of peritonism. She had normal bloods and urine. Xrays chest and abdomen showed no gas under the diaphragm but some dilated loops of small bowel. Ultra sound in the local hospital suggested appendicitis. Diagnosis of adhesions due to previous surgery was made and I arranged for her to have diagnostic laparoscopy which confirmed massive adhesions within her abdominal cavity and suspended small intestine with the anterior abdominal wall which I released. I then divided all the adhesions laparoscopically. She made uneventful recovery and discharged with satisfactory results. She was followed in Outpatients and finally discharged as a happy patient.

Other 17 cases were of various pathology, at least 3 males and 4 females had acute appendicitis. They had laparoscopic appendicectomy and discharged with excellent results. Three patients were admitted as an emergency with acute abdomen. Diagnostic laparoscopy confirmed empyema treated with Laparoscopic cholecystectomy. Other 3 admitted with acute cholecystitis treated with laparoscopic cholecystectomy with good results and discharged next day.

Three patients had blunt abdominal trauma as a result of Road traffic accident and were diagnosed having intra abdominal bleeding. Two patients had perforated duodenal ulcer and one splenic injury which was sorted laparoscopically. One of them had mesenteric vessel tear and had laparoscopic repair. Other two had chronic pain due to adhesions as a result of previous surgery which benefited with laparoscopic adhesiolysis.

DISCUSSION

Emergency laparoscopic exploration can be used to identify the causative pathology of acute abdominal pain. Laparoscopic surgery also allows treatment of many intraabdominal disorders. This report was prepared to describe the effectiveness of laparoscopic surgery compared to open procedures and laparotomy.

Laparoscopic surgery is superior than conventional surgery in terms of hospital stay, less pain, early recovery and least possible chance of incisional hernias and satisfaction of the patients and early return to work. I would recommend laparoscopic surgery for the above benefits to the patients.

RECOMMENDATIONS

Laparoscopic surgery was found to be clearly superior for patients with a presumable diagnosis of perforated peptic ulcer, appendicitis, ectopic pregnancy, trauma, ischaemic gut due to mesenteric infarction and chronic adhesions. In stable patients with acute abdominal pain, diagnostics laparoscopy should be done before considering explorative surgery. However, diagnostic laparoscopy may be useful if no diagnosis can be found by conventional diagnostics. More clinical data are needed on the use of laparoscopy after blunt or penetrating trauma of the abdomen.

CONCLUSIONS

Due to diagnostic and therapeutic advantages, laparoscopic surgery is useful for the majority of conditions underlying acute abdominal pain, but minimal invasive diagnostic aids with laparoscopy should be done first before proceeding on to open surgery depending on symptom severity. Moreover laparoscopy should be advocated if routine diagnostic procedures have failed to yield results. More expertise and training is required to promote skilled laparoscopic surgery in units.

REFERENCES

1. Forde KA, Ganepola GA; Is mandatory exploration for penetrating abdominal trauma extinct? The morbidity and mortality of negative exploration in a large municipal hospital. *J Trauma.*, 1974; 14(9): 764-766.
2. Sosa JL, Baker M, Puente I, Sims D, Sleeman D, Ginzburg E et al., Negative laparotomy in abdominal gunshot wound: Potential impact of laparoscopy. *J Trauma.*, 1995; 38(2):194-197.
3. Kirshtein B, Roy-Shapira A, Lantsberg L, Mandel S, Avinoach E, Mizrahi S; The use of laparoscopy in abdominal emergencies: *Surg Endosc.*, 2003; 17(7): 1118-1124.
4. Sugarbaker PH, Bloom BS, Sanders JH, Wilson RE; Preoperative laparoscopy in diagnosis of acute abdominal pain. *Lancet*, 1975; 305(7904): 442-445.
5. Salky BA, Edey MB; The role of laparoscopy in the diagnosis and treatment of abdominal pain syndromes. *SurgEndosc.*, 1998; 12(7): 911-914.
6. Nord HJ; Complications of laparoscopy. *Endoscopy*, 1992; 24(8): 693-700. 7. Larson GM; Laparoscopy of abdominal emergencies. *Scand J Gastroenterol.*, 1995; 208: 62-66.
7. Berci G, Sackier JM, Paz Partlow M; Emergency laparoscopy. *Am J Surg.*, 1991; 161(3): 332-335.
8. Townsend MC, Flancbaum L, Choban PS, Cloutier CT; Diagnostic laparoscopy as an adjunct to selective conservative management of solid organ injuries after blunt abdominal trauma. *J Trauma.*, 1993; 35(4): 647-651.
9. Ivatury RR, Simon RJ, Stahl WM; A critical evaluation of laparoscopy in penetrating abdominal trauma. *J Trauma.*, 1993; 34(6) 822-827.
10. Sosa JL, Arrillaga A, Puente I, Sleeman D, Ginzburg E, Martin L; Laparoscopy in 121 consecutive patients with abdominal gunshot wounds. *J Trauma.*, 1995; 39(3): 501-504.
11. Gajic O, Urrutia LE, Sewani H; Acute Abdomen in Medical ICU. *Crit Care Med.*, 2002; 30(6): 1187- 1190.
12. Brandt CP, Priebe PP, Eckhauser ML; Diagnostic laparoscopy in the intensive care patients. Avoiding the non -therapeutic laparotomy. *SurgEndosc.*, 1993; 7(3): 168-172.
13. Sauerland S, Lefering R, Neugebauer EA; Laparoscopic versus open surgery for suspected appendicitis. *Cochrane Database Syst Rev.*, 2010; 10:CD001546.
14. Van den Broek WT, Bijnen AB, de Ruiter P, Gouma DJ; A normal appendix found during diagnostic laparoscopy should be removed. *Br J Surg.*, 2001; 88(2): 251-254.
15. Teh SH, O'Ceallaigh S, Mckeon JG, O'Donohoe MK, Tanner WA, Keane FB; Should an appendix that looks 'normal' be removed at diagnostic laparoscopy for acute right iliac fossa pain? *Eur J Surg.*, 2000; 166(5): 388-389.
16. Memon MA, Brow G; Laparoscopic closure of acutely perforated duodenal ulcer- an early experience. *Ir Med J.*, 1993; 86(3): 106-107.
17. Lau WY, Leung KL, Kwong KH, Davey IC, Robertson C, Dawson JJ et al.; A randomised study comparing laparoscopic vs open repair of perforated peptic ulcer using suture or sutureless technique. *Ann Surg.*, 1996; 224(2): 131-138.
18. Miserez M, Eypasch E, Spangenberg W, Lefering R, Troidl H; Laparoscopic and conventional closure of perforated peptic ulcer. A comparison. *SurgEndosc.*, 1996; 10: 831-836.
19. So JB, Kum CK, Fernandes ML, Goh P; Comparison between laparoscopic and conventional omental patch repair for perforated duodenal ulcer. *SurgEndosc.*, 1996; 10(11): 1060- 1063.
20. Ferrozzi L, Lippolis G, Petitti T, Carnevale D, Masi M; Laparoscopic cholecystectomy for acute cholecystitis: our experience. *G Chir.*, 2004; 25(3): 80-82.
21. Eldar S, Sabo E, Nash E, Abrahamson J, Matter I; laparoscopic cholecystectomy for acute cholecystitis: Prospective trial. *World J Surg.*, 1997; 21(5): 540-545.
22. Asoglu O, Ozmen V, Karanlik H, Igci A, Kecer M, Parlak M et al.; Does the complication rate increase in laparoscopic cholecystectomy for acute cholecystitis? *J LaparoendoscAdvSurg Tech A.*, 2004; 14(2): 81-86.
23. Willsher PC, Sanabria JR, Gallinger S, Rossi L, Strasberg S, Litwin DE et al.; Early laparoscopic cholecystectomy for acute cholecystitis: