

---

## CASE REPORT

# Irreducible Fixed Intussusception Causing Small Gut Obstruction

ANAS AHMAD, SADAF ISHAQUE, KHALID JAVED ABID, RIZWAN AHMAD KHAN

### SUMMARY

Intussusception in adults is rare and more common in the paediatric population. Clinically, most adult patients have chronic non-specific symptoms due to partial obstruction. In contrast, most paediatric patients present with the classic triad of abdominal pain, vomiting and blood in stool. Adult intussusception is commonly associated with an organic aetiology, most likely a benign or malignant neoplasm as a lead point of intussusception. We describe a case of a 30-year-old woman with subacute presentation due to ileoileal intussusception secondary to postoperative adhesions. She had a surgical history of one appendectomy, two cesarean sections and a laparoscopic cholecystectomy performed recently. On history, clinical examination and investigations diagnosis of ileoileal intussusception was made. During laparotomy, fixed irreducible intussusception was found. Intussusception was resected and ileoileal anastomosis was done.

**Keywords:** Adult intussusception, intestinal obstruction, ileoileal intussusception.

---

### INTRODUCTION

Intussusception represents abnormal telescopic of the bowel into the lumen of an adjacent segment, leading to obstruction. It is the most common cause of obstruction in infants and young children and is often idiopathic<sup>1</sup>. Intussusception in adults is rare and accounts for <5% of cases of intestinal obstruction; it is usually associated with an organic aetiology<sup>2</sup>. Clinically, the classic triad of abdominal pain, vomiting and blood in stool is seen in one-third of paediatric patients, but rarely in adults. In two-thirds of paediatric and most adult patients, intussusception presents with subacute to chronic non-specific symptoms secondary to partial obstruction. Owing to its high incidence in the paediatric population, intussusception is always a diagnostic consideration in this age group, but not in adult patients<sup>3</sup>. We describe this interesting case of intussusception with a subacute presentation in a 30-year-old patient secondary to a rare benign lesion.

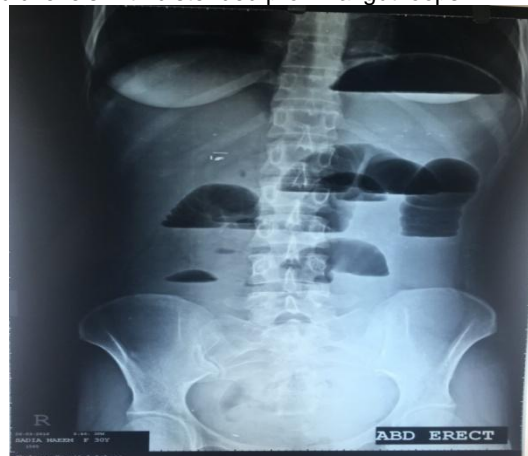### CASE PRESENTATION

A 30 year old female presented to emergency with a 1 month history of episodic cramping abdominal pain lasting from 15 s to 1 min. She started having continuous pain of increased intensity for the past 3 days along with projectile vomiting and absolute constipation. The pain was localized to the periumbilical area with radiation to the right lower quadrant. On examination, diffuse abdominal

tenderness was noted. Rebound tenderness was present in the right lower quadrant.

All routine labs were normal. Abdominal X ray erect and supine revealed multiple air fluid levels with distended proximal gut loops (Fig. 1). On abdomino-pelvic ultrasound, dilated fluid-filled bowel loops and pelvic ascites were identified with normal adnexa and uterus. Abdominal and pelvic CT scan revealed target-like appearance of a bowel segment on axial view (Fig. 2) and the same segment was visualized as a sausage-shaped mass (Fig. 3) on coronal view in the right lower quadrant. These findings were classic for ileoileal intussusception. The small bowel loops proximal to the area of intussusception were dilated. Mild pelvic ascites was also noted. The patient's postop course was uneventful and she was discharged 4 days after surgery.

Fig. 1: Abdominal X ray erect and supine revealed multiple air fluid levels with distended proximal gut loops



---

Dept. of Surgery, Shalamar Medical & Dental College, Lahore  
Correspondence to Prof. Khalid Javed Abid Email: profdrkhalid@gmail.com Cell: 0300-9434692

Fig. 2: Sausage-shaped mass on coronal view

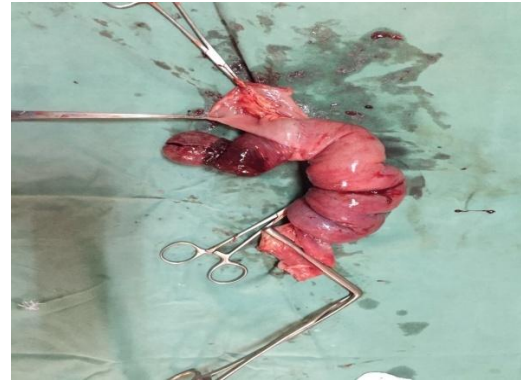
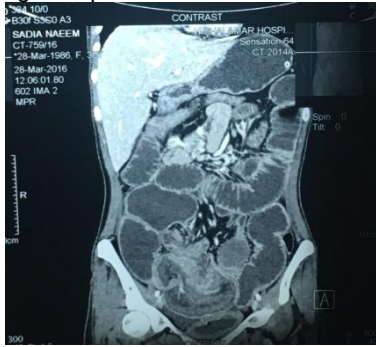
Fig.3: Target-like appearance of bowel segment on axial view

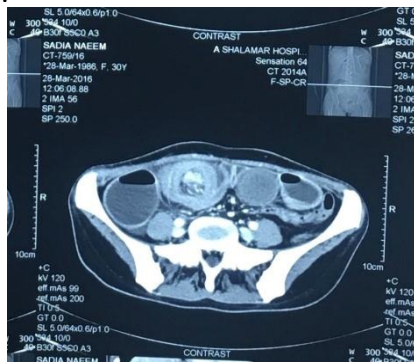


Fig. 4

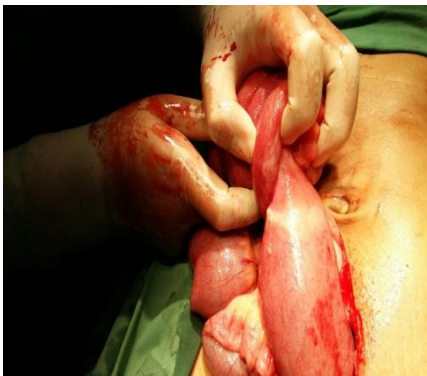

Fig. 5:

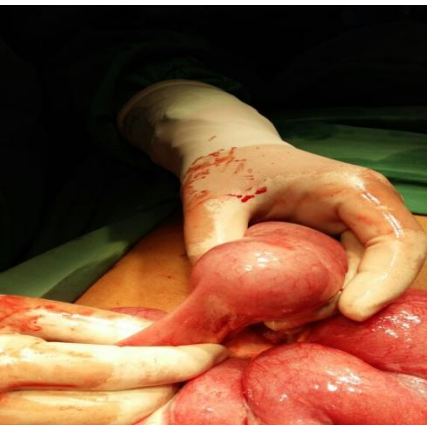

Fig. 6:

The patient underwent an exploratory laparotomy. An intussuscepted segment of ileum was identified in the right lower quadrant. The bowel appeared to be viable, but 8cm intraluminal fixed mass was palpated that was irreducible (Fig. 4,5,). Then approximately 25\*6\*4 cm of ileum with mass was resected and an ileoileal anastomosis was performed (Fig. 6).

## DISCUSSION

Intussusception represents abnormal telescoping of the bowel into lumen of an adjacent segment, leading to obstruction. This case represents intussusception as a rare cause of small gut obstruction in adults. Intussusception is defined as telescoping of proximal segment of GIT within the lumen of adjacent segment.

### Intussusception

- Primary intussusceptions (common in children)
- Secondary intussusception (adults)

Intussusception occurs when one segment of proximal bowel telescopes into the lumen of an adjacent distal segment of bowel, resulting in obstruction and possibly ischemic injury and death of the affected segment of the bowel. Only about 5% of all cases of intussusception are thought to occur in adults<sup>2</sup>. Diagnosing intussusception in adults is challenging, owing to varied presenting symptoms and time course. Unlike the typical pediatric presentation of acute onset, episodic abdominal pain, currant jelly stools, and vomiting, adults often present with a vague history of symptoms that might include diarrhea, constipation, and weight loss. Nausea, vomiting, and abdominal pain are the most common manifestations among adults<sup>1,3,5</sup>. This case also exemplifies the subacute clinical presentation of intussusception in adults. Her initial symptom of intermittent cramping pain is probably secondary to incomplete obstruction, with automatic correction of intussusception. The patient's clinical symptoms worsened when the intussusception was no longer automatically reducible, leading to complete

obstruction. This clinical course is common in adults and often leads to a delay in diagnosis<sup>3</sup>. Cramping abdominal pain is the most common symptom in patients with adult intussusception. Other common symptoms include nausea, vomiting and abdominal distension, which are associated with partial obstruction. Less than 20% of patients have initial presentation of an acute abdomen<sup>8</sup>. Ninety percent of adult cases have an organic aetiology as a lead point of intussusception<sup>3</sup>. A neoplastic process represents the cause of intussusception in approximately two-thirds of these cases. The neoplasm could be either benign or malignant. Up to 60% of colonic intussusceptions are secondary to malignancy, but less than one-third of small bowel intussusceptions are due to malignancy<sup>8</sup>. Most common non-malignant lesions associated with intussusception are lipomas, Peutz-Jeghers and adenomatous polyps. Idiopathic intussusception in adults accounts for less than 10% of cases and are more common in small intestinal cases<sup>3</sup>. Non-neoplastic causes of intussusception include anatomic anomalies like Meckel's diverticulum, adhesions secondary to previous surgeries and inflammatory conditions such as Crohn's disease and celiac disease<sup>10,11,12</sup>.

A correct preoperative diagnosis was made in less than a third of cases in 1 study. Radiologic studies are helpful, but not always diagnostic. Abdominal computed tomography is the most accurate diagnostic procedure, revealing intussusception in 78% of cases. Barium enema examination yields a diagnosis in about half of cases; upper gastrointestinal studies yield a diagnosis in fewer than a quarter of cases<sup>1,9</sup>.

Our patient likely had idiopathic intussusception. Among adults, idiopathic enteric intussusception appears to be more common than idiopathic colonic intussusception<sup>4,8</sup>. In contrast to children, a large proportion (more than 90% in some studies) of adults with intussusception have underlying lesions<sup>11,13,14</sup>. Many case reports show unusual associations of intussusception with other conditions, including Meckel diverticulum<sup>2</sup>, Crohn's disease<sup>11</sup>, postoperative recovery, celiac disease, and local inflammation resulting from pancreatitis.<sup>2</sup> The most common benign cause of enteric intussusception was postoperative adhesions<sup>1</sup>. Malignancy was more commonly associated with colonic intussusception than with enteric intussusception<sup>8,12</sup>. One study reported no difference between sexes in type of intussusception or etiologic factors<sup>4</sup>. Cases of intussusception were evenly distributed among adults of all ages, but the cause of intussusception was more likely to be malignancy among 60- to 80-year-

old patients than among 20 to 60-year-old patients<sup>4,9</sup>.

Surgical resection without reduction is generally advocated as the best treatment for adults with intussusception<sup>1,3</sup>. Some authors support hydrostatic reduction for certain cases<sup>7</sup>. Transient, relatively asymptomatic enteric intussusceptions (particularly of the proximal small bowel) might be incidental findings on computed tomography that do not require intervention<sup>9,13</sup>.

## CONCLUSION

Our patient represents an interesting case of intussusception that highlights the elusive, indolent course that adult intussusception can take. Our patient had intermittent symptoms for 1 month before bowel obstruction. This case report indicates that intussusception, although rare in adults, should be considered in the differential diagnosis of abdominal pain.

## REFERENCES

1. Weihmiller SN, Buonomo C, Bachur R. Risk stratification of children being evaluated for intussusception. *Pediatrics* 2011;127:e296–303
2. Azar T, Berger DL. Adult intussusception. *Ann Surg* 1997;226:134–8
3. Marinis A, Yiallourou A, Samanides L, et al. Intussusception of the bowel in adults: a review. *World J Gastroenterol* 2009;15:407–11
4. Fletcher CDM. *Diagnostic histopathology of tumors*. 3rd edn Philadelphia: Elsevier Health, 2007
5. Kaneko T, Karasawa Y, Inada H, et al. An adult case of intussusception due to inverted Meckel's diverticulum accompanied by angiolipoma. *Nihon Shokakibyō Gakkai Zasshi* 1996;93:260–5
6. Aminian A, Noaparast M, Mirsharifi R, et al. Ileal intussusception secondary to both lipoma and angiolipoma: a case report. *Cases J* 2009;2:7099.
7. Della Volpe N, Bianco L, Bonuso C, et al. Rare ileal localisation of angiolipoma presenting as chronic haemorrhage and severe anaemia: a case report. *J Med Case Rep* 2008;2:129.
8. Haas EM, Etter EL, Ellis S, et al. Adult intussusception. *Am J Surg* 2003;186:75–6
9. Baleato-Gonzalez S, Vilanova JC, Garcia-Figueiras R, et al. Intussusception in adults: what radiologists should know. *Emerg Radiol* 2012;19:89–101
10. Afgha FP. Intussusception in adults. *AJR Am J of Roentgenol*. 1986;146(3):527–31.
11. Weilbaecher D, Bolin JA, Hearn D, Ogden W., II Intussusception in adults. Review of 160 cases. *Am J Surg*. 1971;121:531–5.
12. Warshauer DM, Lee JK. Adult intussusception detected at CT or MR imaging: clinical-imaging correlation. *Radiology*. 1999;212(3):853–60.
13. Azar T, Berger DL. Adult intussusception. *Ann Surg*. 1997;226(2):134–8.
14. Briggs DF, Carpathios J, Zollinger AW. Intussusception in adults. *Am J Surg*. 1961;101:109–13.