

# Diagnostic Accuracy of Color Doppler Ultrasound in Antenatal Diagnosis of Morbidly Adherent Placenta, taking Operative Findings of Caesarean Section as Gold Standard

DANIA KHALID, AFSHAN NOREEN, AZHAR MEHMOOD JAVED, MEHWISH ZAHRA, MEHREEN GUL, AFSHAN SHAKIR

## ABSTRACT

**Background:** Our ability to diagnose morbidly adherent placenta has changed over the last decade. Ultrasound (USG), magnetic resonance imaging (MRI) or a combination of these modalities are now-a-days utilized depending on the availability of expertise and equipment. Ultrasound imaging is popular due to its low cost and accessibility and widely used for the screening of placental location and potential abnormal development.

**Methods:** A total of 69 booked gravid females in third trimester (diagnosed on early ultrasound) having diagnosed placenta previa on ultrasound in current pregnancy were selected. Primigravida females and women having pregnancies complicated by hypertension, diabetes mellitus and cardiac disease were excluded. All the subjects were underwent colour Doppler USG and the presence or absence of morbidly adherent placenta previa was noted. Colour Doppler ultrasonography findings were correlated with operative findings (taking as gold standard).

**Results:** Mean age was  $27.78 \pm 2.65$  years. USG detected the morbidly adherent placenta in 8(11.59%) women. In USG positive patients, 07 were True Positive and 01 was False Positive. Among 61, USG negative patients, 01 was False Negative where as 60 were True Negative ( $p=1.000$ ). Sensitivity, specificity, positive predictive value, negative predictive value and diagnostic accuracy of color Doppler ultrasound in antenatal diagnosis of MAP was calculated as 87.5%, 98.36 %, 87.5%, 98.36% and 97.10% respectively.

**Conclusion:** This study concluded a higher diagnostic accuracy of color Doppler ultrasound for antenatal diagnosis of morbidly adherent placenta in gravid females having placenta previa.

**Keywords:** Placenta accreta, non-invasive, imaging modality, sensitivity.

---

## INTRODUCTION

Morbidly adherent placenta (MAP) is defined as abnormal placental adherence, either in whole or in part of the placenta to the underlying uterine wall<sup>1</sup>. Morbid adherent placenta is rare complication of placentation but has life and fertility threatening complications and includes placenta accreta, percreta and increta<sup>2</sup>. It is found to be the third most frequent indication for emergency obstetrical hysterectomy next to uterine rupture and atony in Pakistan<sup>3</sup>.

Over the past three decades, incidence of MAP has increased drastically<sup>4</sup>. The frequency of abnormal placentation is increasing day by day especially in women with placenta previa which is increased to 10-fold<sup>5</sup>. Placenta percreta constitutes around 5% of MAP increta constitutes 15% and accreta about 80%<sup>5</sup>. The most well known risk factors for MAP are placenta previa and previous

cesarean delivery<sup>6,7</sup>. According to American College of Obstetricians & Gynecologists, incidence of MAP is 1 in 2500 deliveries. Recent reports suggest a frequency between 1 per 2500 deliveries and 1 per 1100 deliveries.<sup>1</sup> Associated maternal mortality reportedly as high as 10%.

Our ability to diagnose morbidly adherent placenta has changed over the last decade. Ultrasound (USG), magnetic resonance imaging (MRI) or a combination of these modalities are now-a-days utilized depending on the availability of expertise and equipment. Ultrasound is readily available, has low cost with no radiation hazards and is the investigation of choice for placental location, abnormalities and its variants. Now a days, placental MRI is used to describe its morphological pattern and its topographical information which is useful for diagnosis of placental abnormalities and for its surgical management<sup>8</sup>.

Considering the MAP a life threatening and fertility problem, I had conducted this study to determine the diagnostic accuracy of color Doppler ultrasound in antenatal diagnosis of morbidly

---

Department Of Diagnostic Radiology, Nishtar Hospital Multan  
The Children Hospital and Institute of Child Health, Multan.  
Correspondence to Dr. Dania Khalid, Email:  
drafshansalam@gmail.com Cell: 0305-5300280

adherent placenta. This would help us in understanding the role of this modality for early diagnosis and thereafter timely management of patients.

**MATERIALS AND METHODS**

This descriptive, cross sectional study was done from April 2013 to November 2013, on 69 booked gravid females in third trimester (diagnosed on early ultrasound) having diagnosed placenta previa on ultrasound in current pregnancy, who were referred by clinician to the radiology department of Nishtar Hospital, Multan were selected for the study. Primigravida females and women having pregnancies complicated by hypertension, diabetes mellitus and cardiac disease were excluded from the study. After taking informed consent and relevant history from all cases, all the subjects were underwent colour Doppler USG by the consultant sonologist having 3 years post fellowship experience and the findings were later on be confirmed on caesarean section by consultant gynaecologist having more than 3 years post fellowship experience. The diagnosis of morbidly adherent placenta previa was made by Doppler ultrasound as presence of anyone of these i.e. complete loss of retroplacental sonolucent zone, Thinning or disruption of hyperechoic uterine serosa-bladder interface with abnormal blood vessels linking the placenta to the bladder, Sonolucent vascular lakes with turbulent flow, Markedly dilated vessels over the peripheral sub-placental region. Each woman was undergone operation in the concerning ward. Colour Doppler ultrasonography findings were correlated with operative findings (taking as gold standard). The collected data was analyzed through computer software SPSS 20.0. Mean and standard deviation was calculated for quantitative variables. Frequency and percentage was calculated for qualitative variables. 2x2 contingency table was used to calculate sensitivity, specificity, positive predictive value, negative predictive value and diagnostic accuracy of color Doppler ultrasound in antenatal diagnosis of morbidly adherent placenta in gravid females having placenta previa.

**RESULTS**

Age range in this study was from 18-35 years with mean age of 27.78±2.65 years. Majority of the patients 59.42% were between 18 to 30 years of age (Table I). Distribution of the patients according to their parity was recorded, 33(47.83%) between 1-3 and 36(52.17%) had >3 paras. All the patients were subjected to colour Doppler ultrasonography. USG detected the morbidly adherent placenta in

8(11.59%) women. Operative findings confirmed morbidly adherent placenta in 8(11.59%) cases where as 61(88.41%) women revealed no morbidly adherent placenta. In USG positive patients, 07 (True Positive) had morbidly adherent placenta and 01 (False Positive) had no morbidly adherent placenta on operation. Among 61, USG negative patients, 01 (False Negative) had morbidly adherent placenta on operation where as 60 (True Negative) had no morbidly adherent placenta on operation (p=1.000) as shown in Table II. Diagnostic accuracy of color Doppler ultrasound in antenatal diagnosis of MAP in gravid females having placenta previa was calculated as 87.5%, 98.36 %, 87.5%, 98.36% and 97.10% as sensitivity, specificity, positive predictive value, negative predictive value and accuracy rate respectively (Fig. 1).

Fig. 1: Diagnostic accuracy of color Doppler ultrasound in antenatal diagnosis of morbidly adherent placenta in gravid females having placenta previa.

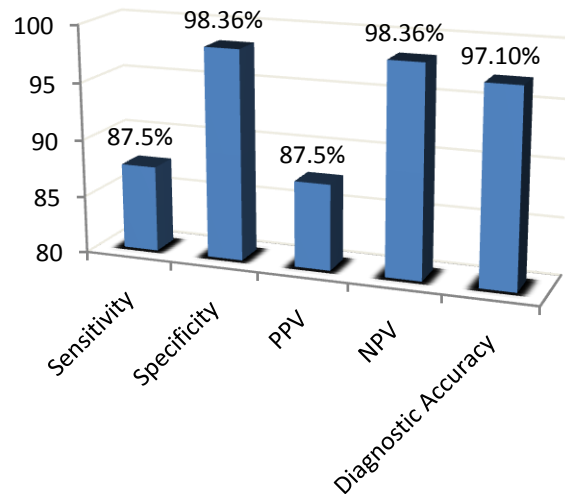


Table I: Age distribution of the patients

Age(in years)	n	%age
18-30	41	59.42
31-35	28	40.58
Total	69	100

Mean±SD: 27.78±2.65

Table-II: Summary of Results.

	+Ve results on USG	-Ve result on USG
+ve on operative findings	07 (TP)*	01 (FN)***
-ve on operative findings	01 (FP)**	60 (TN)****

\*TP=True positive \*\*FP=False positive \*\*\*FN=False negative \*\*\*\*-TN=True negative

## DISCUSSION

The introduction of obstetric ultrasound with color Doppler in modern obstetrics helped in the early detection and management of adherent placenta. With such achievement these low cost modalities might replace the MRI completely for the diagnosis of morbidly adherent placenta. The need to conduct this study was that the MAP is a life threatening problem and diagnostic accuracy of color Doppler ultrasound may be useful which may help us in understanding the role of this modality for early diagnosis and thereafter timely management of patients<sup>10</sup>.

In this study, 41(59.42%) were between 18-30 years, 28(40.58%) were between 31-35 years, mean±sd was calculated as 27.78±2.65 years, 33(47.83%) between 1-3 and 36(52.17%) had >3 paras, frequency of morbidly adherent placenta (on per operative findings) reveals in 8(11.59%), and diagnostic accuracy of color Doppler ultrasound in antenatal diagnosis of MAP in gravid females having placenta previa was calculated as 87.5%, 98.36%, 87.5%, 98.36% and 97.10% as sensitivity, specificity, positive predictive value, negative predictive value and accuracy rate respectively.

These findings are supported by other studies who reported that colour Doppler US has a sensitivity of between 82.4% and 100%, and 91.2% specificity between 92% and 96.8%.<sup>11</sup> The expected prevalence of ultrasonography in detecting MAP was 82%. Warshak CR<sup>12</sup> and Wong HS<sup>13</sup> observed that anterior lower uterine segment is most common site for placenta accreta and due to its superficial location Color doppler ultrasound is useful in demonstrating placental blood flow into the bladder interface.

Cali G and others<sup>14</sup> determined the diagnostic accuracy of color Doppler in patients with morbidly adherent placenta (MAP), and defines the criterion to distinguish placenta accreta from placenta percreta.

First described by Finberg and Williams in 1992, placental lacunae have been the most predictive US finding for PA<sup>15,16,17</sup>. Intraplacental lacunae are parallel linear vascular channels of varying size and shape. They are found in the placental parenchyma, extending from placental parenchyma into the myometrium creating a "moth-eaten" or "Swiss cheese" placental appearance.

According to the literature, presence of placental lacunae are very important for the diagnosis of PA, especially when the placental lacunae are visualized after 15 weeks and it has sensitivity 78%-93% and specificity of 78.6%<sup>16,17</sup>. Risk of PA increases with increasing numbers of lacunae. All cases of PA in one study had at least four placental lacunae<sup>16</sup>. Case reports on PA shows turbulent flow in placental

lacunae on color Doppler imaging findings<sup>16</sup>. Twickler et al<sup>18</sup> mapped color flow in placental lacunae in pts with PA. He took 20 cases of PA to see whether turbulent flow is present in placental lacunae. By using this technique, he concluded that turbulent flow is present in all cases of PA was unable to report combined sensitivity and specificity of color Doppler flow and gray-scale imaging.

However, Doppler ultrasound accurately predicted placenta accreta i.e abnormal attachment of the placenta to the myometrium in 76.2% of cases for Doppler ultrasound and MRI in 66.7% of cases (difference not significant)<sup>19</sup>. In the literature, a mixed performance is observed. The sensitivity of Doppler ultrasound is variable ranges from 85 to 100% and its specificity from 35 to 96%, depending on the study<sup>20,21</sup>.

Three recently published systematic review have shown the diagnostic accuracy of ultrasound for the diagnosis of invasive placentation<sup>21</sup>, the use of MRI<sup>22</sup> and a comparison of ultrasound and MRI.<sup>23</sup> D'Antonio et al<sup>21,22</sup> published meta-analyses for diagnosis of invasive placentation with sensitivity of 90.7% and specificity of 96.9% for ultrasound and sensitivity of 94.4% and specificity of 84% for MRI. Meng et al<sup>23</sup> showed that ultrasound sensitivity was 83%, its specificity was 95% and diagnostic odds ratio(DOR) was 63.41 compared with 82%, 88% and 22.9% respectively, for MRI. These meta-analyses showed good accuracy of ultrasound and MRI in the diagnosis of invasive placentation.

Color Doppler ultrasound imaging is popular because it is cheap, readily available, easily accessible and widely used for the screening of placenta location and placental abnormalities. Color Doppler ultrasound has high sensitivity and specificity for diagnosis of morbidly adherent placenta especially when specific defined criteria are used for the diagnosis.<sup>24</sup> However, the results of the study in support with other studies reveal that diagnostic accuracy of color Doppler ultrasound in antenatal diagnosis of morbidly adherent placenta in gravid females having placenta previa is significantly higher and this modality may be used further for in-time management.

## CONCLUSION

This study concluded a higher diagnostic accuracy of color Doppler ultrasound for antenatal diagnosis of morbidly adherent placenta in gravid females having placenta previa. It is recommended that especially high risk patients must be screened in their antenatal period for diagnosis of the morbidity so that proper treatment protocols may be followed.

## REFERENCES

- Hasan AA, Hasan J, Khan AA. Management and maternal outcome in morbidly adherent placenta. *J Surg Pak (international)*. 2009;14:166-9.
- Derman AY, Nikas V, Haberman S, Zalenko N, Opsha O, Flyer M. Clinical perspective: MRI of placenta accreta: a new imaging perspective. *Am J Roentgenol*. 2011;197:1514-21.
- Shah N, Khan NH. Emergency obstetrical hysterectomy :review of 69 cases. *Rawal Med J*. 2009;34:75-8.
- Leyendecker JR, DuBose M, Hosseinzadeh K, Stone R, Gianini J, Childs DD et al. MRI of Pregnancy-Related Issues: Abnormal Placentation. *Am J Roentgenol*. 2012;198:311-20.
- Eller AG, Bennett MA, Sharshiner M, Masheter C, Soisson AP, Dodson M, et al. Maternal morbidity in cases of placenta accreta managed by a multidisciplinary care team compared with standard obstetric care. *Obstet Gynecol*. 2011;117:331–7.
- Lim PS, Greenberg M, Edelson MI, Bell KA, Edmonds PR, Mackey AM. Utility of Ultrasound and MRI in prenatal diagnosis of placenta accreta. *Am J Roentgenol*. 2011; 197:1505-13.
- Choi SJ, Song SE, Jung KL, Oh SY, Roh CR. Antepartum risk factors associated with postpartum caesarean hysterectomy in women with placenta previa. *Am J Perinatol*. 2008;75:919-25.
- Mazouni C, Gorincoue G, Johan V, Bretelle F. Placenta accrete:a review of current advances in prenatal diagnosis. *Placenta* 2007;28:599-603.
- Ansar A, Rauf N, Bano K, Liaqat N. Spontaneous rupture of primigravid uterus due to morbidly adherent placentas. *JCPSP* 2009;19:732-3.
- Elhawary TM, Dabees NL, Youssef MA; Diagnostic value of ultrasonography and magnetic resonance imaging in pregnant women at risk for placenta accreta. *J Matern Fetal Neonatal Med*. 2013;26(14):1443-9
- Thai EW, Lee SL, Tan HK. Ultrasonographical features of morbidly-adherent placentas. *Singapore Med J*. 2007;48(9):799-802.
- Warshak CR, Eskander R, Hull AD. Accuracy of ultrasonography and magnetic resonance imaging in the diagnosis of placenta accreta. *Obstet Gynecol*. 2006;108:573-81.
- Wong HS, Zuccollo J, Straw L. The use of ultrasound in assessing the extent of myometrial involvement in partial placenta accreta. *Ultrasound Obstet Gynecol*. 2007;30:277-30.
- Cali G, Giambanco L, Puccio G, Forlani F. Morbidly adherent placenta: evaluation of ultrasound diagnostic criteria and differentiation of placenta accreta from percreta. *Ultrasound Obstet Gynecol*. 2013;41(4):406-12.
- Finberg HJ, Williams JW. Placenta accreta: prospective sonographic diagnosis in patients with placenta previa and prior cesarean section. *J Ultrasound Med*. 1992;11:333–43.
- Yang JI, Lim YK, Kim HS, Chang KH, Lee JP, Ryu HS. Sonographic findings of placental lacunae and the prediction of adherent placenta in women with placenta previa totalis and prior Cesarean section. *Ultrasound Obstet Gynecol*. 2006;28:178–82.
- Japaraj RP, Mimin TS, Mukudan K. Antenatal diagnosis of placenta previa accreta in patients with previous cesarean scar. *J Obstet Gynaecol Res*. 2007;33:431–7.
- Twickler DM, Lucas MJ, Balis AB. Color flow mapping for myometrial invasion in women with a prior cesarean delivery. *J Matern Fetal Med*. 2000;9:330–5.
- Maher MA, Abdelaziz A, Bazeed MF. Diagnostic accuracy of ultrasound and MRI in the prenatal diagnosis of placenta accreta. *Acta Obstet Gynecol Scand*. 2013;92:1017–22.
- Riteau A-S, Tassin M, Chambon G, Le Vaillant C, de Laveaucoupet J, Quéré M-P, et al. Accuracy of Ultrasonography and Magnetic Resonance Imaging in the Diagnosis of Placenta Accreta. *PLoS ONE*. 2013;9(4):e94866.
- D'Antonio F, Iacovella C, Bhide A. Prenatal identification of invasive placentation using ultrasound: systematic review and meta-analysis. *Ultrasound Obstet Gynecol*. 2013;42:509–17.
- D'Antonio F, Iacovella C, Palacios-Jaraquemada J, Bruno CH, Manzoli L. Prenatal Identification Of Invasive Placentation Using Magnetic Resonance Imaging (Mri): A Systematic Review And Meta-Analysis. *Ultrasound Obstet Gynecol*. 2014;doi:10.1002/uog.13327.
- Meng X, Xie L, Song W. Comparing the diagnostic value of ultrasound and magnetic resonance imaging for placenta accreta: a systematic review and meta-analysis. *Ultrasound Med Biol*. 2013;39:1958–965.
- Peker N, Turan V, Ergenoglu M, Yeniel O, Sever A. Assessment of total placenta previa by magnetic resonance imaging and ultrasonography to detect placenta accreta and its variants. *Ginekol Pol*. 2013;84:186–92.